

# Medium-term results of ceramic-on-polyethylene Zweymüller-Plus total hip arthroplasty

H Li, S Zhang, XM Wang, JH Lin \*, BL Kou \*

## ABSTRACT

**Introduction:** The need for better durability and longevity in total hip arthroplasty for patients with various hip joint diseases remains a challenge. This study aimed to obtain medium-term results at a follow-up of >10 years for Zweymüller-Plus total hip arthroplasty with ceramic-on-polyethylene bearing.

**Methods:** A retrospective study was conducted to review the results after a minimum of 12.4 years of 207 consecutive total hip arthroplasties in 185 patients in Peking University People's Hospital in China using the Zweymüller SL-Plus stem in combination with the Bicon-Plus threaded cup and ceramic-on-polyethylene bearing between October 1994 and April 2000.

**Results:** During the study period, two patients (2 hips) died and 25 patients (28 hips) were lost to follow-up. Two hips were revised for aseptic loosening of the Bicon-Plus cup. The mean clinical and radiological follow-up was 14.1 years (range, 12.4-16.5 years) for the remaining 156 patients (175 hips). The mean (standard deviation) Harris Hip score for the 175 hips increased significantly from 39.3 (3.8) preoperatively to 94.1 (2.5) postoperatively at a mean follow-up of 14.1 years ( $P < 0.05$ ). Focal osteolysis was observed in seven (4.0%) of 175 stems and three (1.7%) of 175 cups. The Kaplan-Meier

survival with revision for any reason as the end-point was 99.03% (95% confidence interval, 95%-100%).

**Conclusions:** The high survival rate of the cementless Zweymüller-Plus system with ceramic-on-polyethylene bearing at mid-term follow-up makes this total hip arthroplasty system reliable for patients with various hip joint diseases.

Hong Kong Med J 2017;23:333-9

DOI: 10.12809/hkmj164949

<sup>1</sup> H Li #, MD

<sup>2</sup> S Zhang #, MD

<sup>3</sup> XM Wang, MD

<sup>1</sup> JH Lin \*, MD

<sup>1</sup> BL Kou \*, MD

<sup>1</sup> Arthritis Clinic and Research Center, Peking University People's Hospital, Beijing, No.11 Xizhimen South Street, Xicheng District, Beijing, 100044, China

<sup>2</sup> Orthopaedic Department, Beijing Dongchengqu First People's Hospital, Beijing, 100075, China

<sup>3</sup> Orthopaedic Department, Beijing Moslem Hospital, Beijing, 100054, China

# The first two authors contributed equally to this work.

\* Corresponding authors: bolongkoubk@163.com; jianhao\_lin@hotmail.com

This article was published on 10 Mar 2017 at www.hkmj.org.

### New knowledge added by this study

- This study determined the medium-term outcome of Zweymüller-Plus total hip arthroplasty (THA) with ceramic-on-polyethylene bearing.

### Implications for clinical practice or policy

- Zweymüller-Plus THA has a good medium-term outcome and is reliable for patients with various hip joint diseases.

## Introduction

Total hip arthroplasty (THA) is considered one of the most effective therapies for a variety of hip joint diseases. The cemented THA has been successfully performed since the 1960s but has been widely criticised in several postoperative follow-up studies for its later loosening.<sup>1,2</sup> During the 1970s, cementless THA with different principles of fixation and various new materials was introduced. This prosthesis had good biocompatibility and its specific surface structure could achieve secondary fixation to bone that could avoid later loosening.<sup>3</sup>

The Zweymüller-Plus system (Smith & Nephew

Orthopaedics AG; Rotkreuz, Switzerland), a kind of cementless THA that comprises the SL-Plus stem and Bicon-Plus cup, was introduced in 1993 as a successor to the Alloclassic system.<sup>4</sup> It has been widely used for primary THA. Because of aseptic loosening due to polyethylene wear, alternative bearings were introduced.<sup>5,6</sup> These alternative bearings included metal-on-metal, ceramic-on-ceramic, and ceramic-on-polyethylene articulation.<sup>7,8</sup> The Zweymüller-Plus THA system with the ceramic-on-polyethylene bearing has been reported to have superior survival and durability at 10 years' follow-up than other bearings.<sup>9</sup> Additionally, in the mid-1990s in mainland

## 使用陶瓷對聚乙烯Zweymüller-Plus全髖關節置換術的中期結果

李虎、張舒、王曉梅、林劍浩、寇伯龍

**引言：**對於各種髖關節病患者來說，全髖關節置換術中人工髖關節的耐用性和使用壽命依然是一項挑戰。本研究旨在找出使用有陶瓷對聚乙烯負重界面的Zweymüller-Plus全髖關節置換術的患者隨訪超過10年的中期結果。

**方法：**回顧研究1994年10月至2000年4月期間於中國北京大學人民醫院進行全髖關節置換術共185名患者（207髖）。隨訪期至少為12.4年。所有手術均使用陶瓷對聚乙烯界面的Zweymüller-Plus假體柄與Bicon-Plus螺旋臼杯組合。

**結果：**研究期間有2名患者（2髖）死亡，另有25名失訪患者（28髖）。有2髖因Bicon-Plus螺旋臼杯出現無細菌鬆脫須進行再置換術。餘下的156名患者（175髖）的平均臨床和放射隨訪時間為14.1年（介乎12.4至16.5年）。在平均隨訪期為14.1年時，175例髖的平均（標準差）Harris髖關節評分由術前的39.3（3.8）分顯著增加至術後的94.1（2.5）分（ $P < 0.05$ ）。175例假體柄中有7例（4.0%）出現局灶性骨溶解，另175例螺旋臼杯中有3例（1.7%）有同樣情況。以再置換術（不論任何原因）為最終結果測量，Kaplan-Meier存活率為99.03%（95%置信區間：95%-100%）。

**結論：**根據本研究的中期結果，對於各種髖關節病患者來說，使用有陶瓷對聚乙烯負重界面的Zweymüller-Plus全髖關節置換術均有高存活率。

China, the Zweymüller-Plus THA with ceramic-on-polyethylene bearing was the most common type of hip prosthesis. We report the results after a minimum of 12.4 years of an independent series using Zweymüller-Plus THA with ceramic-on-polyethylene bearing in a historical follow-up study.

## Methods

Between October 1994 and April 2000, a total of 207 Zweymüller-Plus total hip replacements (Smith & Nephew Orthopaedics AG) with ceramic-on-polyethylene bearings were performed in 185 consecutive patients at Peking University People's Hospital in China. The institutional review board of Peking University People's Hospital approved this study, with the requirement of patient informed consent waived because of its retrospective nature.

## Patients

Data on the patients including gender, age, hip distribution, initial diagnosis, complications, reason for revisions, and clinical outcome were obtained from the hospital database and retrospectively reviewed. Basic demographic data and indications for implantation of the prosthesis were collected.

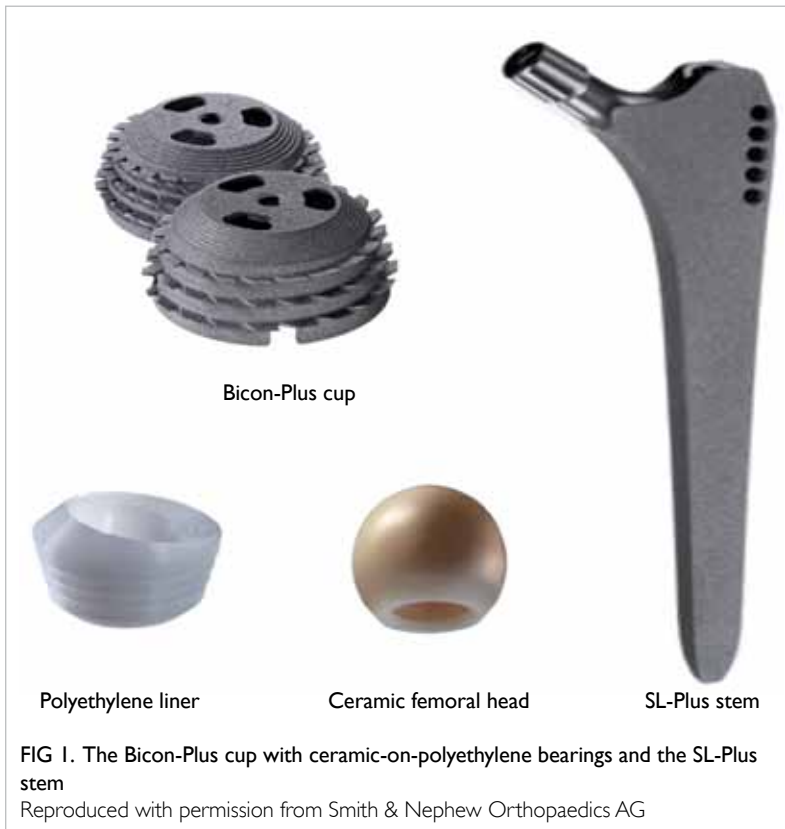## Implants

The acetabular component was the Bicon-Plus cup (Smith & Nephew Orthopaedics AG), a biconical threaded cup made of hot-forged pure titanium (Fig 1). The Bicon-Plus cup has a microroughness of 4-6  $\mu\text{m}$  and no coating on the microporous outer surface. The polyethylene inlay of the Bicon-Plus cup is made of conventional ultra-high-molecular-weight polyethylene that has been sterilised by gamma irradiation.

The femoral component was the SL-Plus stem, a cementless, rectangular, dual-tapered straight stem made of a wrought Ti-6Al-7Nb alloy with a microporous surface roughness of 4-6  $\mu\text{m}$  (Smith & Nephew Orthopaedics AG; Rotkreuz, Switzerland; Fig 1). The femoral head with a diameter of 28 mm was made of high-grade alumina ceramics (the third-generation alumina ceramics). The edges of the SL-Plus stem were rounded to reduce the occurrence of distal femoral cortical thickening. The combination of polyethylene inlay with the 28-mm diameter ceramic femoral head constituted the ceramic-on-polyethylene bearing surface.

## Perioperative care

All THAs were performed by the senior surgeon (BL Kou) through a modified Hardinge direct lateral approach. The mean ( $\pm$  standard deviation) desired acetabular position was  $45^\circ \pm 10^\circ$  of abduction and  $15^\circ \pm 10^\circ$  of anteversion, the femoral position was  $5^\circ - 10^\circ$  of anteversion: both were evaluated by postoperative



X-ray. In order to facilitate optimal insertion of the bone, the bone had to be shaped to the Bicon-Plus cup by matched directional devices. All patients received prophylactic antibiotics prior to surgery and subcutaneous low-molecular-weight heparin calcium for prophylaxis against thrombosis for 2 weeks postoperatively. Patients were discharged after a mean of 5 days after surgery. Mobilisation with full weight-bearing was encouraged the day after surgery. At postoperative 6 weeks, rehabilitation exercises were commenced and the hip joint mobilised.

### Clinical and radiological assessment

The Harris Hip score (HHS),<sup>10</sup> which is a disease-specific health-related quality-of-life instrument and widely used to evaluate physical function and pain relief in patients with various hip diseases, was used to clinically evaluate patients preoperatively, postoperatively, and at the most recent follow-up. Anteroposterior and lateral supine radiographs of the hip and femur were analysed for radiolucencies, osteolysis, and migration of the components, and compared with radiographs taken 2 weeks after surgery. Osteolytic areas and radiolucencies adjacent to the SL-Plus and Bicon-Plus were evaluated using the zones described by Gruen et al<sup>11</sup> and DeLee and Charnley,<sup>12</sup> respectively. Osteolysis was described as a sharply demarcated radiolucent space with rounded or scalloped appearance that was >2 mm wide.<sup>13</sup> The migration of the cup was defined as movement of ≥3 mm in a horizontal or vertical direction and stem migration was defined as a change in position of >4 mm relative to the mid-lesser trochanter. Femoral implant stability was assessed by the radiographs according to the criteria of Engh et al,<sup>14</sup> as stable with osseointegration or fibrous tissue ingrowth, or as unstable. Heterotopic ossification was evaluated using the criteria described by Brooker et al.<sup>15</sup> Liner wear was determined by subtracting the thickness of the polyethylene on the first radiograph of the hip postoperatively in the standing position from the last available control radiograph corrected for enlargement and determined in relation to the diameter of the head component.<sup>15</sup> We only included cases of annual liner wear of >0.1 mm/year due to the lack of precision of these measurements.

### Statistical analysis

Demographic and X-ray variables were assessed with descriptive statistics. Kaplan-Meier survival analyses<sup>16</sup> with 95% confidence intervals (CI) were used to determine the survival rate with the use of several end-points: revision for any reason or revision for aseptic loosening for each component of the THA system. All patients were included in the Kaplan-Meier analysis. Patients who died were censored at their date of death and patients who were lost to follow-up were censored at the date of

last assessment. Continuous variables of HHS were compared using a two-sided Student's *t* test. The Statistical Package for the Social Sciences (Windows version 19.0; IBM Corp, Armonk [NY], United States) was used to analyse the collected data. A P value of <0.05 was considered significant.

## Results

### Sample

Demographic data of patients and indications for implantation of the prosthesis are listed in Table 1. There were 95 women and 90 men, and the mean age (± standard deviation) at the time of the index surgery was 57.8 ± 13.8 years (range, 16-72 years). Overall, 161 patients (183 hips) underwent primary THA only and the most common indication was ischaemic femoral head necrosis (58 hips). Other indications included ankylosing spondylitis and femoral neck fracture (Table 1). Another 24 hips underwent surgery for revision (15 for aseptic loosening, 6 for migration of the acetabular component, and 3 for deep infection) and the mean time between the primary THA and this revision was 3.2 years.

TABLE 1. Patient demographics and distribution of hips

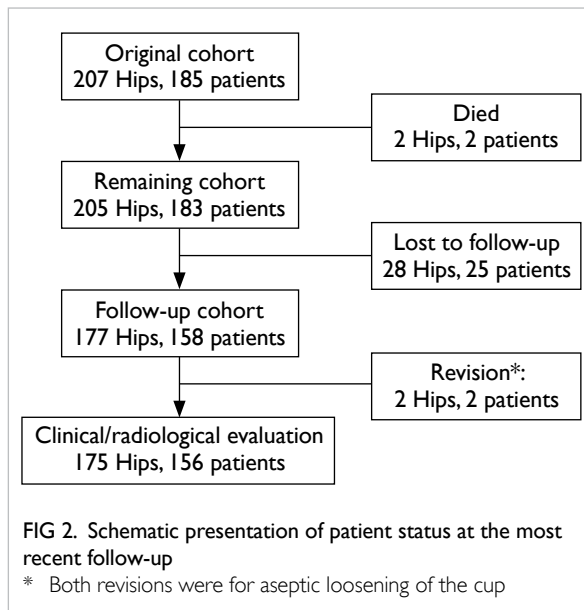
	No. (%) of patients/hips*
<b>Sex</b>	
Male	90 (48.6)
Hip	107 (51.7)
Female	95 (51.4)
Hip	100 (48.3)
<b>Age-group (years), No. of patients</b>	
0-39	28 (15.1)
40-49	35 (18.9)
50-59	28 (15.1)
60-75	90 (48.6)
>75	4 (2.2)
<b>Hip distribution, No. of hips</b>	
Right	90 (43.5)
Left	117 (56.5)
<b>Diagnosis, No. of hips</b>	
Primary total hip arthroplasty	183 (88.4)
Ischaemic femoral head necrosis	58 (28.0)
Ankylosing spondylitis	42 (20.3)
Femoral neck fracture	30 (14.5)
Others†	53 (25.6)
Revision	24 (11.6)

\* Because of rounding, not all percentages total 100

† Including osteoarthritis, acetabular dysplasia, and rheumatoid arthritis

### Follow-up

As shown in Figure 2, two patients (two hips) died without a revision prior to death for reasons unrelated to the surgery; the time between operation and death were 4.2 years and 5.1 years, respectively. Twenty-five patients (28 hips) were lost to follow-up. The main cause for patients lost to follow-up was change of residence and/or phone number. Revision was performed in two patients (two hips). A total of 156 patients (175 hips) were available for clinical and radiological evaluation, with a mean time between operation and final evaluation of 14.1 years (range, 12.4-16.5 years).



### Revisions

There were two (0.97%) revisions in the whole series of 207 hips. An example of good results at 16.5 years of follow-up is shown in Figure 3. The stem alone had not been revised in any hip. The Bicon-Plus cup alone had been revised in two hips, both for aseptic loosening. Radiographs of aseptic loosening of acetabular components before and after revision at 10.7 years until the latest follow-up are shown in Figure 4. Both revision surgeries were performed on men after 10.7 and 16.5 years postoperatively. No perioperative complications were observed after revision and the HHS were 92 and 96 post-revision, respectively.

There were no other re-operations at the time of most recent follow-up. Two hips (two patients), however, showed excessive polyethylene wear of the liner although both were asymptomatic. Liner exchange was recommended but both patients refused. They were closely monitored for observation of wear progression and osteolysis development.

### Radiological evaluation of surviving hips

Non-progressive radiolucent lines around the femoral component (<1 mm) were found in seven (4.0%) of 175 stems, all limited to the proximal femur (Gruen zone 7). Comparison of early and late postoperative radiographs revealed no signs of osteolysis in the distal femoral zones or subsidence of femoral prosthesis of >1 mm. Intramedullary ossification was found in five (2.9%) of 175 stems. There was no excessive liner wear in the remaining 173 hips.

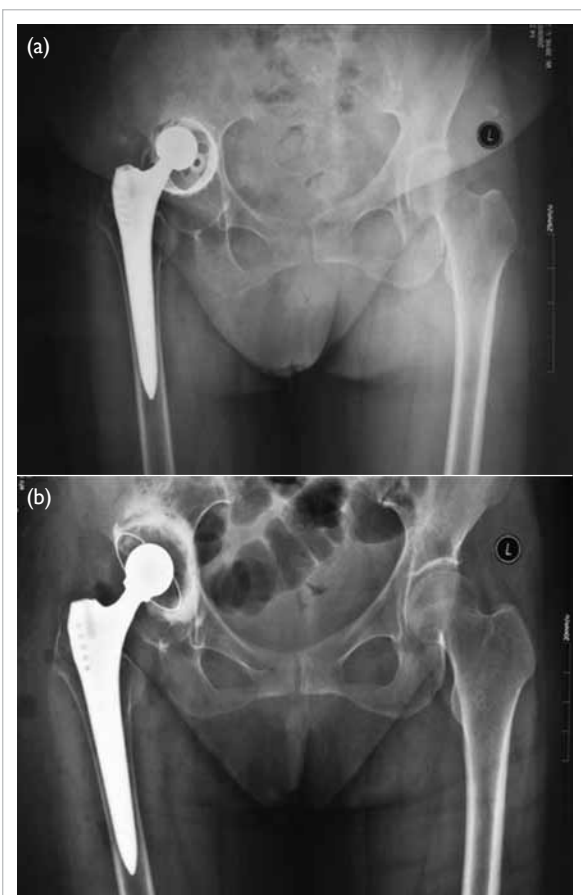
Non-progressive radiolucent lines of <2 mm

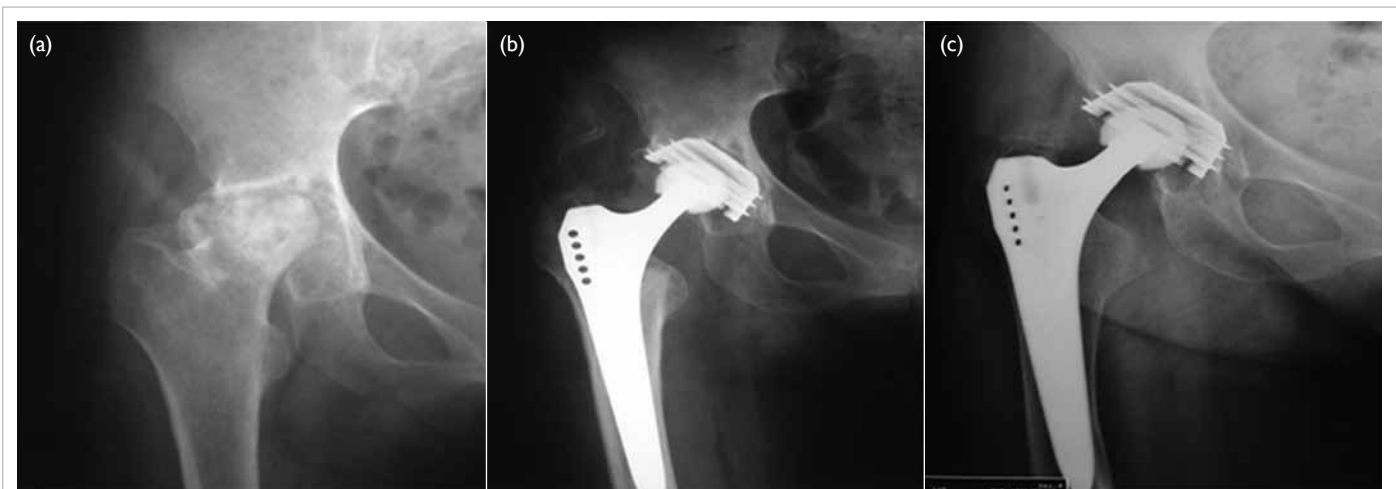

FIG 3. An example of good outcome with Zweymüller-Plus total hip arthroplasty

Radiographs were taken from a 59-year-old female who underwent Zweymüller-Plus total hip arthroplasty at 16.5 years of follow-up in April 2012: (a) preoperative, (b) at 2 years of follow-up, (c) at 16.5 years of follow-up





**FIG 4. An example of aseptic loosening of acetabular components**  
 Radiographs were taken from a 56-year-old female who underwent Zweymüller-Plus total hip arthroplasty at 10.7 years of follow-up in July 2012: (a) before revision and (b) at 10 years of follow-up after revision

were found around the Bicon-Plus cup in three (1.7%) of 175 hips in DeLee-Charnley zone III. No extensive peri-acetabular osteolysis radiographically of >2 mm was observed in any hip. Heterotopic ossification was found in 23 (13.1%) of 175 hips with various degrees according to the criteria by Brooker et al.<sup>15</sup> Among the 23 hips, 11 hips were considered Brooker grade I, eight hips were Brooker grade II, and the remaining four were Brooker grade III.

### Clinical evaluation of surviving hips

A total of 156 patients (175 hips) were available for clinical and radiological evaluation. The mean HHS for the 175 hips increased significantly from 39.3 ± 3.8 preoperatively to 94.1 ± 2.5 postoperatively at a mean follow-up of 14.1 years ( $P < 0.05$ ).

### Complications

Intra-operative complications including pulmonary and deep vein thrombosis were not observed in any patient. Surgical complications including

calcar cracks, femoral fracture, deep infection, and dislocation did not occur in any patient. In addition, no medical complications were observed in cardiac, urinary, or psychiatric aspects.

### Survival analysis

The Kaplan-Meier survival analysis, with the end-point being revision of any component for any reason, estimated the 14.1-year (minimum follow-up of 12.4 years) survival rate at 99.03% (95% CI, 95%-100%). Since the reason for both revisions was aseptic loosening of the Bicon-cup, the survival rate at a minimum of 12.4 years of follow-up with removal of any component for aseptic loosening and the probability of survival of acetabular components with revision for any reason were both 99.03% (95% CI, 95%-100%). In addition, the survival rate of the SL-Plus stem with revision for any reason was 100%. The worst case survival of this ceramic-on-polyethylene THA, when taking the two pending revision cases into account, with removal of any component for any cause as the end-point was 98.07% (95% CI, 84%-100%).

### Discussion

Medium- to long-term follow-up studies are required to evaluate the effectiveness of orthopaedic implants in patients with various hip diseases. The present study was conducted in a group of 207 hips after a mean follow-up of 14.1 years to evaluate the medium-term effectiveness of the Zweymüller-Plus THA with ceramic-on-polyethylene bearings.

The main finding of this study was the relatively high survival rate of both implant components (100% for the femoral component and 99.0% for the acetabular component). The worst survival when taking the pending revisions into account was still 98.1%. Although methodological differences and dissimilar implant designs can limit comparison of different THAs, the survival rate of the stem and cup in our series is comparable or even higher than previous descriptions for other THAs, especially the Alloclassic system (Zimmer, Winterthur, Switzerland). Bonnomet et al<sup>17</sup> reported that the 10-year survival with stem revision for any reason as the end-point of the Alloclassic-SL grit-blasted titanium stem in primary THA was 99.2%. For Alloclassic THAs with/without hydroxyapatite coating on the fixation of a cementless femoral stem, the 15-year survival of the stem for the event (revision for any reason) was 98.1%.<sup>18</sup> For another cementless Zweymüller-Alloclassic system, a survival rate of 98% for the stem and 85% for the cup at 15 years with revision for any reason as the end-point has been reported.<sup>19</sup> Femoral survival and acetabular survival with the Alloclassic system are shown in Table 2.<sup>17-20</sup> Consistent with our results,

TABLE 2. Comparison of survival studies

Study	Type of arthroplasty	Maximum years of follow-up	Femoral survival (%); 95% CI	Acetabular survival (%); 95% CI
Bonnomet et al <sup>17</sup>	Alloclassic*	10	99.2; 92.4-99.9	Not given
Grübl et al <sup>19</sup>	Alloclassic*	15	98; 96-100	85; 79-91
Delaunay <sup>18</sup>	Alloclassic* (with or without HA)	15	98.1	Not given
Lass et al <sup>20</sup>	Alloclassic Metasul† (metal-on-metal bearing)	18.8	97.9; 95.8-100	95; 92.1-97.9

Abbreviations: CI = confidence interval; HA = hydroxyapatite

\* Alloclassic (Zimmer, Winterthur, Switzerland)

† Alloclassic Metasul (Zimmer, Winterthur, Switzerland)

long survival of Zweymüller-Plus components with ceramic-on-polyethylene bearings has been reported previously. A retrospective analysis of results after a mean follow-up of 11 years by Korovessis et al<sup>21</sup> showed that the rate of survival was 100% for the Bicon-Plus and 98% for the SL-Plus. As a successor of the Alloclassic system, there are several improvements in the Zweymüller-Plus system. The sharp edges of the Alloclassic stem have been rounded in the SL-Plus stem and this may avoid distal stress concentration, cortical thickening, and subsequent thigh pain.<sup>22,23</sup> Moreover the Bicon-Plus cup has inherent advantages over the Alloclassic cup when implanted in hips with deficient or deformed acetabulum since positioning of the biconical threaded cup does not require removal of so much spherical acetabular bone.<sup>21</sup> All these features make the Zweymüller-Plus system hypothetically practical and stable.

The type of bearing couple may be the major limitation for longevity of well-fixed hip implants.<sup>24</sup> A previous comparison of four bearings revealed that ceramic-on-polyethylene bearing couple achieved the best results for revision for any reason (98.1%).<sup>9</sup> Similar to a previous description, the survival of the ceramic-on-polyethylene bearings in the Zweymüller-Plus system was relatively high in our study (99.0%). Ceramic bearings have several advantages over other bearings such as a low coefficient of friction, low wear rates, and less biologically reactive debris.<sup>25-27</sup> They also have several drawbacks such as susceptibility to fracture,<sup>28</sup> although they avoid the adverse qualities associated with polyethylene.<sup>9</sup> In our study, there were no revisions due to ceramic fracture.

The problems with polyethylene wear and osteolysis are often considered to compromise the long-term survival of implants. In an analysis based on the Norwegian Arthroplasty Register, Hallan et al<sup>29</sup> showed that high revision rates for polyethylene wear and osteolysis lead to an obvious decline in survival after 10 years. There is an improvement in osteolysis of the Alloclassic cup compared with

cemented polyethylene cups with ceramic-on-polyethylene bearing surfaces, since radiolucent lines and osteolysis in the Alloclassic cup were evident in 0% to 6% of cases after 9.3 to 12 years<sup>19,30</sup> while osteolysis around cemented cups was present in 11% at 11.2 years.<sup>31</sup> In our study, radiolucent lines and osteolysis in the Bicon-Plus cups was 1.7% at 14.1 years, which is lower than that in previous reports.<sup>19,30</sup> Additionally, the osteolysis and radiolucent lines were all located proximally and did not extend around the distal part of the stem. The osteolysis rate (4%) of the SL-Plus stem at 14.1 years was also lower.

Our findings were tempered by the limitations inherent in our study design. The retrospective design and the high number of patients lost to follow-up might lead to excessively optimistic results. In addition, patients who died or who were lost to follow-up were not included in the clinical analysis although their data were included in the survival calculation to minimise the bias. Despite these limitations, our study with a relatively long follow-up and a large number of patients provides evidence of the clinical durability of the ceramic-on-polyethylene Zweymüller-Plus THA.

## Conclusions

Our results indicate that the Zweymüller-Plus system with ceramic-on-polyethylene bearing showed a long survival and durability at a mean follow-up of 14.1 years, along with an improvement in osteolysis of both the SL-Plus stem and Bicon-Plus cup. Longer follow-up is still necessary to monitor the long-term outcomes for the Zweymüller-Plus system with ceramic-on-polyethylene.

## Declaration

The authors declare that they have no competing interests.

## References

- Schulte KR, Callaghan JJ, Kelley SS, Johnston RC. The outcome of Charnley total hip arthroplasty with cement

- after a minimum twenty-year follow-up. The results of one surgeon. *J Bone Joint Surg Am* 1993;75:961-75.
2. Severt R, Wood R, Cracchiolo A 3rd, Amstutz HC. Long-term follow-up of cemented total hip arthroplasty in rheumatoid arthritis. *Clin Orthop Relat Res* 1991;(265):137-45.
  3. Hailer NP, Garellick G, Kärrholm J. Uncemented and cemented primary total hip arthroplasty in the Swedish Hip Arthroplasty Register. *Acta Orthop* 2010;81:34-41.
  4. Repantis T, Vitsas V, Korovessis P. Poor mid-term survival of the low-carbide metal-on-metal Zweymüller-plus total hip arthroplasty system: a concise follow-up, at a minimum of ten years, of a previous report. *J Bone Joint Surg Am* 2013;95:e331-4.
  5. Goldring SR, Clark CR, Wright TM. The problem in total joint arthroplasty: aseptic loosening. *J Bone Joint Surg Am* 1993;75:799-801.
  6. Harris WH. Wear and periprosthetic osteolysis: the problem. *Clin Orthop Relat Res* 2001;(393):66-70.
  7. Petsatodis GE, Papadopoulos PP, Papavasiliou KA, Hatzokos IG, Agathangelidis FG, Christodoulou AG. Primary cementless total hip arthroplasty with an alumina ceramic-on-ceramic bearing: results after a minimum of twenty years of follow-up. *J Bone Joint Surg Am* 2010;92:639-44.
  8. Korovessis P, Petsinis G, Repanti M, Repantis T. Metallosis after contemporary metal-on-metal total hip arthroplasty. Five to nine-year follow-up. *J Bone Joint Surg Am* 2006;88:1183-91.
  9. Topolovec M, Milošev I. A comparative study of four bearing couples of the same acetabular and femoral component: a mean follow-up of 11.5 years. *J Arthroplasty* 2014;29:176-80.
  10. Davis KE, Ritter MA, Berend ME, Meding JB. The importance of range of motion after total hip arthroplasty. *Clin Ortho Relat Res* 2007;465:180-4.
  11. Gruen TA, McNeice GM, Amstutz HC. "Modes of failure" of cemented stem-type femoral components: a radiographic analysis of loosening. *Clin Ortho Relat Res* 1979;(141):17-27.
  12. DeLee JG, Charnley J. Radiological demarcation of cemented sockets in total hip replacement. *Clin Ortho Relat Res* 1976;(121):20-32.
  13. Zicat B, Engh CA, Gokcen E. Patterns of osteolysis around total hip components inserted with and without cement. *J Bone Joint Surg Am* 1995;77:432-9.
  14. Engh CA, Bobyn JD, Glassman AH. Porous-coated hip replacement. The factors governing bone ingrowth, stress shielding, and clinical results. *J Bone Joint Surg Br* 1987;69:45-55.
  15. Brooker AF, Bowerman JW, Robinson RA, Riley LH Jr. Ectopic ossification following total hip replacement. Incidence and a method of classification. *J Bone Joint Surg Am* 1973;55:1629-32.
  16. Kaplan EL, Meier P. Nonparametric estimation from incomplete observations. *J Am Stat Assoc* 1958;53:457-81.
  17. Bonnomet F, Delaunay C, Simon P, et al. Straight femoral taper in cementless primary total hip replacement in less than 65 year-old patients: multicenter study of 115 consecutive implantations at mean 8.2 year follow-up [in French]. *Rev Chir Orthop Reparatrice Appar Mot* 2001;87:802-14.
  18. Delaunay C. Effect of hydroxyapatite coating on the radio-clinical results of a grit-blasted titanium alloy femoral taper. A case-control study of 198 cementless primary total hip arthroplasty with the Alloclassic system. *Orthop Traumatol Surg Res* 2014;100:739-44.
  19. Gröbl A, Chiari C, Giurea A, et al. Cementless total hip arthroplasty with the rectangular titanium Zweymüller stem. A concise follow-up, at a minimum of fifteen years, of a previous report. *J Bone Joint Surg Am* 2006;88:2210-5.
  20. Lass R, Gröbl A, Kolb A, et al. Primary cementless total hip arthroplasty with second-generation metal-on-metal bearings: a concise follow-up, at a minimum of seventeen years, of a previous report. *J Bone Joint Surg Am* 2014;96:e37.
  21. Korovessis P, Repantis T, Zafiropoulos A. High medium-term survivorship and durability of Zweymüller-Plus total hip arthroplasty. *Arch Orthop Trauma Surg* 2011;131:603-11.
  22. Gröbl A, Chiari C, Gruber M, Kaider A, Gottsauner-Wolf F. Cementless total hip arthroplasty with a tapered, rectangular titanium stem and a threaded cup: a minimum ten-year follow-up. *J Bone Joint Surg Am* 2002;84-A:425-31.
  23. Garcia-Cimbrello E, Cruz-Pardos A, Madero R, Ortega-Andreu M. Total hip arthroplasty with use of the cementless Zweymüller Alloclassic system. A ten to thirteen-year follow-up study. *J Bone Joint Surg Am* 2003;85-A:296-303.
  24. Zywił MG, Sayeed SA, Johnson AJ, Schmalzried TP, Mont MA. State of the art in hard-on-hard bearings: how did we get here and what have we achieved? *Expert Rev Med Devices* 2011;8:187-207.
  25. Murphy SB, Ecker TM, Tannast M. Two-to 9-year clinical results of alumina ceramic-on-ceramic THA. *Clin Ortho Relat Res* 2006;453:97-102.
  26. Affatato S, Traina F, De Fine M, Carmignato S, Toni A. Alumina-on-alumina hip implants: a wear study of retrieved components. *J Bone Joint Surg Br* 2012;94:37-42.
  27. Revell PA. The combined role of wear particles, macrophages and lymphocytes in the loosening of total joint prostheses. *J R Soc Interface* 2008;5:1263-78.
  28. Park YS, Hwang SK, Choy WS, Kim YS, Moon YW, Lim SJ. Ceramic failure after total hip arthroplasty with an alumina-on-alumina bearing. *J Bone Joint Surg Am* 2006;88:780-7.
  29. Hallan G, Dybvik E, Furnes O, Havelin LI. Metal-backed acetabular components with conventional polyethylene: a review of 9113 primary components with a follow-up of 20 years. *J Bone Joint Surg Br* 2010;92:196-201.
  30. Perka C, Fischer U, Taylor WR, Matziolis G. Developmental hip dysplasia treated with total hip arthroplasty with a straight stem and a threaded cup. *J Bone Joint Surg Am* 2004;86-A:312-9.
  31. Sugano N, Nishii T, Nakata K, Masuhara K, Takaoka K. Polyethylene sockets and alumina ceramic heads in cemented total hip arthroplasty. A ten-year study. *J Bone Joint Surg Br* 1995;77:548-56.