

Clinical applications of high-intensity focused ultrasound

WH She, TT Cheung *, Caroline R Jenkins, Michael G Irwin

ABSTRACT

Ultrasound has been developed for therapeutic use in addition to its diagnostic ability. The use of focused ultrasound energy can offer a non-invasive method for tissue ablation, and can therefore be used to treat various solid tumours. High-intensity focused ultrasound is being increasingly used in the treatment of both primary and metastatic tumours as these can be precisely located for ablation. It has been shown to be particularly useful in the treatment of uterine fibroids, and various solid tumours including those of the pancreas and liver. High-intensity focused ultrasound is a valid treatment option for liver tumours in patients with significant medical co-morbidity who are at high risk for surgery or who have relatively poor liver function that may preclude hepatectomy. It has also been used as a form of bridging therapy while patients awaiting cadaveric donor liver transplantation. In this article, we outline the principles of high-intensity focused ultrasound and its clinical applications, including the management protocol development in the treatment of hepatocellular carcinoma in Hong

Kong by performing a search on MEDLINE (OVID), EMBASE, and PubMed. The search of these databases ranged from the date of their establishment until December 2015. The search terms used were: high-intensity focused ultrasound, ultrasound, magnetic resonance imaging, liver tumour, hepatocellular carcinoma, pancreas, renal cell carcinoma, prostate cancer, breast cancer, fibroids, bone tumour, atrial fibrillation, glaucoma, Parkinson's disease, essential tremor, and neuropathic pain.

Hong Kong Med J 2016;22:382–92

DOI: 10.12809/hkmj154755

¹ WH She, MB, BS, FRCS

¹ TT Cheung *, MS, FRCS

² CR Jenkins, MB, BS, FRCA

² MG Irwin, MD, FRCA

¹ Department of Surgery

² Department of Anaesthesiology

The University of Hong Kong, Queen Mary Hospital, Pokfulam, Hong Kong

* Corresponding author: tantocheung@hotmail.com

▶ A video clip showing clinical applications of high-intensity focused ultrasound is available at <www.hkmj.org>



This article was published on 6 Jul 2016 at www.hkmj.org.

Introduction

High-intensity focused ultrasound (HIFU) was initially used in the 1940s to treat brain pathologies such as Parkinson's disease.¹⁻³ In the 1990s, it was introduced to ophthalmology to treat raised intra-ocular pressure, traumatic capsular tears, glaucoma, retinal detachment, and vitreous haemorrhage.⁴⁻⁹ This technique has a unique ability to target deep-seated soft tissue tumours. Furthermore, as long as the lesions within solid organs can be clearly visualised on magnetic resonance imaging (MRI) or ultrasonography (USG)—that is, the presence of the acoustic window to allow the transmission of ultrasound energy—many lesions can be targeted such as those in the liver, kidney, pancreas and breast; and uterine fibroids, benign prostatic hypertrophy, and prostate cancer. In recent years, HIFU has been used to treat both benign and malignant lesions of various solid organs. This non-invasive modality allows treatment of tumours without surgery and offers a new treatment option for those patients who are not candidates for surgery, or who do not want surgery.

Methods

A search was performed on the following electronic

databases: MEDLINE (OVID), EMBASE, and PubMed. The search of these databases ranged from the date of their establishment until December 2015. The search terms used were: high-intensity focused ultrasound, ultrasound, magnetic resonance imaging, liver tumour, hepatocellular carcinoma, pancreas, renal cell carcinoma, prostate cancer, breast cancer, fibroids, bone tumour, atrial fibrillation, glaucoma, Parkinson's disease, essential tremor, and neuropathic pain. Only studies reported in English were included. Full papers were selected if they contained facts, data, or scientific evidence related to the treatment of HIFU. The reference lists of articles selected were screened for full-text review.

Mechanism of high-intensity focused ultrasound

High-intensity focused ultrasound incorporates multiple ultrasound beams produced by piezoelectric or piezoceramic transducers directed into a three-dimensional focal point of typically 1 to 5 mm in diameter and 10 to 50 mm in length.¹⁰ Various mechanisms have been proposed for the subsequent tissue destruction with a synergistic

effect from thermal and mechanical means. This technique induces heat generation due to absorption of the acoustic energy with the temperature rising rapidly to 60°C or higher, causing coagulation necrosis in a short period of time. Focusing is an important component as only a small volume (eg 1 mm diameter and 9 mm length) is targeted by the ultrasound beam and hence HIFU induces minimal thermal damage to tissue located between the transducer and the focal point.¹¹

A mechanical effect is produced by acoustic pulses only at higher intensities. Various phenomena are observed, including cavitation, microstreaming, and radiation forces. Cavitation is defined as the creation or motion of a gas cavity in an acoustic field due to alternating compression and expansion of tissue as an ultrasound burst propagates through it.¹² There are two forms of cavitation to consider: stable and inertial.¹¹ If the tissue expansion or rarefaction pressure is of sufficient magnitude, gas can be extracted from the tissue, resulting in bubble formation. In stable cavitation, the bubble is exposed to a low-pressure acoustic field, resulting in stable oscillation of the size of the bubble. In inertial cavitation, exposure of the bubble to the acoustic field results in violent oscillations of the bubble and rapid growth during the rarefaction phase, eventually leading to the violent collapse and destruction of the bubble. It will produce shock waves of very high pressure (20-30 000 bars) and a high temperature (2000-5000 K) in the microenvironment.^{13,14} Microstreaming is a phenomenon produced by stable cavitation in which rapid movement of fluid occurs near the bubble due to its oscillating motion. It can produce high shear forces that can cause transient damage to cell membranes and may play a role in ultrasound-enhanced drug or gene delivery when damage to the cell membrane is transient.^{13,15}

Radiation forces are developed when a wave is either absorbed or reflected. If the reflecting or absorbing medium is tissue or other solid material, the force presses against the medium, producing a pressure termed 'radiation pressure'. If the medium is liquid and can move under pressure, then streaming results.¹⁶

The intention of HIFU is to raise and maintain an isolated part of the volume above 60°C for more than 1 second or longer, in order to cause coagulative necrosis and immediate cell death.^{17,18} It aims to deliver the energy required to raise the tissue temperature to a cytotoxic level sufficiently fast that the tissue vasculature does not have a significant effect on the extent of cell killing.^{19,20} In a study of the application of HIFU in the liver, 2 hours of exposure resulted in a rim of glycogen-free cells of about 10 cells wide. These cells were dead 48 hours later, and showed signs of coagulative necrosis typical of thermal injury.¹⁹

高強度聚焦超聲的臨床應用

石黃海、張丹圖、Caroline R Jenkins、Michael G Irwin

超聲具有診斷和治療雙重作用。聚焦的超聲能量為組織切除提供了一種無創方法，故可用於治療不同腫瘤。高強度聚焦超聲（HIFU）能準確地把腫瘤消融，所以在治療原發性和轉移性腫瘤方面越趨廣泛。研究顯示HIFU對於消融子宮肌瘤，以及其他如肝臟和胰臟的腫瘤尤其有效。對於患有其他嚴重疾病而不適合接受手術的病人，以及肝功能較差而不能接受肝切除的病人，HIFU是一個有效的治療方案。另外，對於正等待屍肝移植的病人，此技術也可作為橋接療法。我們利用電子數據庫MEDLINE（OVID）、EMBASE和PubMed找出和以下關鍵詞相關的文獻：高強度聚焦超聲、超聲、磁力共振、肝腫瘤、肝細胞癌、胰腺、腎細胞癌、前列腺癌、乳腺癌、子宮肌瘤、骨腫瘤、心房纖維性顫動、青光眼、帕金森氏病、特發性震顫和神經性疼痛，並概括列出使用HIFU的原則及其臨床應用，包括香港治療肝癌模式的發展。

Limitations of high-intensity focused ultrasound

Of all the ablative modalities, HIFU has the advantage that it does not require the introduction of an applicator in order to achieve the ablative effect and is the only non-invasive option. This makes it a very attractive choice. It has several limitations, however. This technique is essentially USG and, therefore, any artefacts, such as acoustic shadowing, reverberation, and refraction also apply to it. Superficial lesions are treated most effectively by HIFU due to the limitations of ultrasound penetration through many tissues, but the sound wave reflected carries very high energy, and can also produce burns in tissues that lie between the target and the transducer. Many collateral injuries have been reported due to scattered and reflected high-intensity ultrasound waves, such as skin burns, peripheral nerve damage, and bowel injury.^{21,22} Great care also needs to be taken in areas that are subject to respiratory movement, because of a lack of precision, or the presence of sonic shadowing due to overlying bony substances.²¹ In such situations it may be necessary for the anaesthetist to use controlled ventilation. The amount of energy absorbed by the tissue may vary, as fibrotic, fatty, and highly vascularised tissues attenuate sound energy differently. Excessive energy absorption may result in an unpredictable distribution of cell death.²³ Careful planning is therefore required to ensure adequate tumour coverage, as coagulation, desiccation, and vapour formation are detrimental to ultrasound energy propagation, as well as precise localisation of the lesion.²⁴

The high-intensity focused ultrasound system

Both USG and MRI can be used to visualise, target, and monitor the status of tissue destruction.

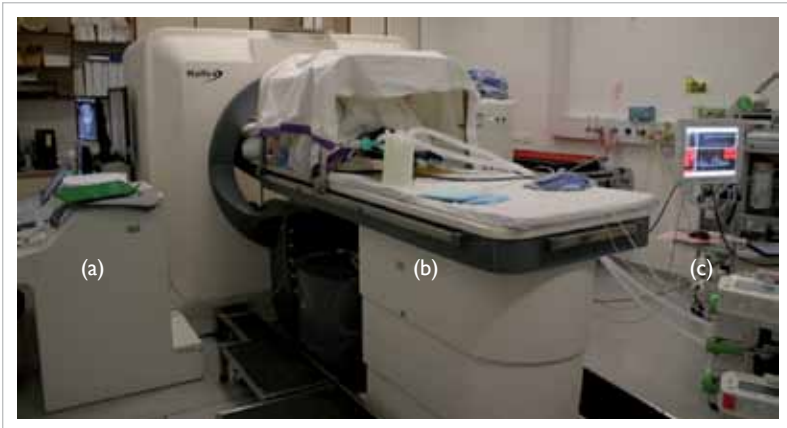


FIG 1. The usual setup of the high-intensity focused ultrasound (HIFU) system (a) Control system; (b) HIFU machine and patient lying on the treatment table; and (c) anaesthetic machine

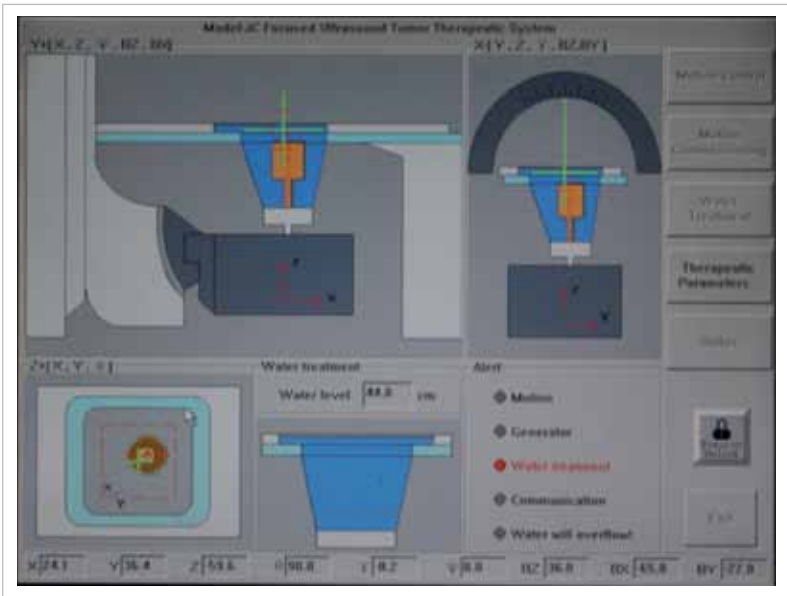


FIG 2. Computer controls the degassed water in and out of the tank

Ultrasonography

This is the most common method to target and monitor the status of HIFU destruction.²⁵ The therapeutic and diagnostic transducers can be packaged into one instrument that allows real-time monitoring of the delivery of HIFU, the outcome of the lesion, and the outcome of the peripheral tissues. Although it is cost-effective, it has relatively low spatial resolution that limits its accuracy for targeting and it is also hard to visualise the details of the structures in close proximity to the bowel because of the gas-containing portions (air conducts sound very poorly). In our unit, we use an USG-guided HIFU system.²⁶

Magnetic resonance imaging

This offers excellent resolution and tumour detail. It locates the tumour boundary very clearly and is particularly useful in patients in whom tumours cannot be visualised with USG, for example, in obese patients.²⁷ Magnetic resonance imaging possesses real-time thermal resolution with high spatial resolution, and provides temperature data within seconds of HIFU exposure. This allows detection of small temperature elevations before any irreversible tissue damage occurs.²⁸ Nonetheless, MRI guidance is expensive, labour intensive, noisy, and bulky. Equipment such as that used for monitoring and anaesthesia needs to be non-ferrous and MRI-safe and treatment time is prolonged.

High-intensity focused ultrasound device

There are several devices available for the treatment of various diseases, including extracorporeal, transrectal, and interstitial devices.

Extracorporeal devices

Organs lying externally or those that are readily accessible—such as breasts, cutaneous tissue, limbs, abdomen, and brain—are usually treated with extracorporeal HIFU that is guided by either USG or MRI. As long as there is a suitable acoustic window on the skin that allows uninterrupted propagation of the HIFU energy beam to the target organs, one can consider the use of extracorporeal HIFU for treatment.

Ultrasonography-guided transcutaneous high-intensity focused ultrasound

We are currently using a HIFU machine produced by Haifu Technology Company (Chongqing, China) [Figs 1 to 3]. It has been used and shown to be effective in treatment of a variety of benign and malignant solid organ tumours, such as liver and pancreatic cancer, uterine fibroids, soft tissue tumours, breast cancer, and bladder cancer.²⁹⁻³¹ This system consists of three selectable therapeutic transducers and a real-time imaging transducer. The transducers are mounted in a water reservoir with the beam axis directed upward, and the patient is positioned above the transducers in a prone or decubitus position. The HIFU exposure level is adjusted until a hyperechoic region is seen on the USG image.

Magnetic resonance imaging-guided high-intensity focused ultrasound

Two major clinical MRI-HIFU systems are available worldwide: InSightec (Tirat Carmel, Israel) and Philips Healthcare (Vantaa, Finland).^{32,33} Their HIFU

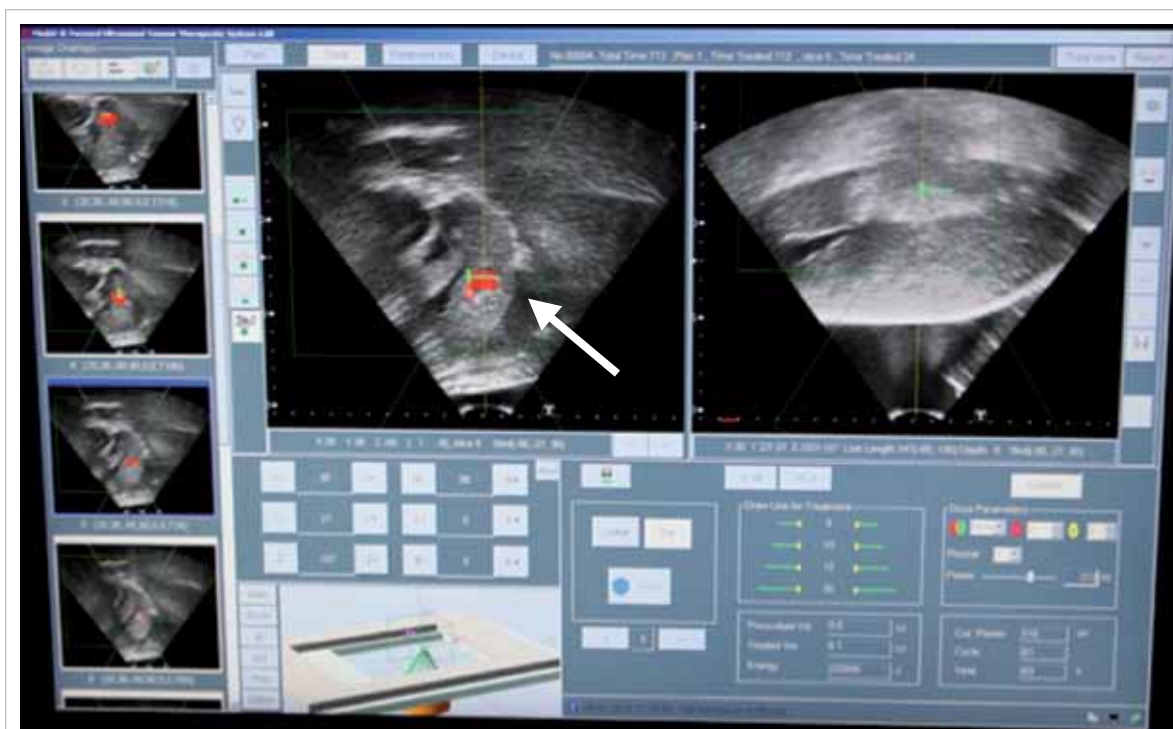


FIG 3. The lesion (arrow) is identified and fired by high-intensity focused ultrasound

transducers are similar in terms of enabling both mechanical and electronic adjustment of HIFU focus and MR thermometric temperature monitoring, but their sonication strategies are different and hence they differ in energy efficiency.³⁴ These machines are not available in Hong Kong.

Transrectal devices

Transrectal devices were developed for the treatment of benign and malignant prostatic diseases. They aim to ablate the entire prostate. Both USG-guided probes and MRI-guided systems have been developed. The USG probes are inserted per rectum and incorporate both imaging and therapeutic transducers in one unit,³⁵⁻⁴¹ such as Ablatherm (Edap Technomed, France) and the Sonablate (Focus Surgery Inc, US), whereas a prostate-dedicated MRI-HIFU system makes use of either the transrectal (ExAblate OR; InSightec) or transurethral (Philips Healthcare) approach.^{42,43}

Interstitial devices

Ultrasonographic transducers with different shapes and sizes were developed in order to place the focused applicators as close as possible to the target area. Several shapes are available, including cylindrical, semi-cylindrical, cylindrical with focusing by wave reflection, plane and cylindrical array. Various applicators have been developed to facilitate access

and guidance of the device, such as the flexible applicator in an endoscopically placed HIFU device for the treatment of cholangiocarcinoma⁴⁴ or oesophageal tumours⁴⁵; or rigid applicators for a linear approach. Probes for percutaneous and laparoscopic treatment are also being developed and it is likely that the therapeutic indications will increase.

Current clinical applications

High-intensity focused ultrasound has been used to treat various benign and malignant solid tumours. It is also used in conditions such as ablation for atrial fibrillation,⁴⁶ glaucoma,⁴⁷ and benign obstetric and gynaecological procedures such as fibroids.³²

Liver tumours

In general, liver resection is still the mainstay of treatment of hepatocellular carcinoma (HCC), provided the patient is surgically fit, has fair liver function with good liver remnant and resectable tumour. Liver transplantation is planned for patients whose tumour is within the transplant criteria, and a living or deceased donor is available.

Ablative therapy, such as radiofrequency ablation (RFA), is considered for patients with a relatively small tumour, preserved liver function, and favourable location, that is, away from pleural or gastrointestinal tract. For those patients whose

tumours are relatively small, located at the dome of the liver, with clinical evidence of ascites or pleural effusion, HIFU would be an alternative as long as the lesion can be visualised and located by USG. For those patients with multifocal tumours that are not amenable to surgical resection or ablation, and who have reasonable liver function without evidence of ascites, transarterial chemoembolisation is the treatment of choice. Sorafenib is an effective target therapy for patients undergoing palliative care, but has significant side-effects.

High-intensity focused ultrasound is now one of the treatment modalities in our centre for HCC and has been used as bridging therapy for patients who are awaiting cadaveric donor liver transplantation. This technique can be utilised for patients who are not suitable for percutaneous RFA but have a satisfactory general condition as assessed by an anaesthesiologist. They should have intact skin over the ablative region.

High-intensity focused ultrasound treatment procedure

Before treatment, the patient undergoes USG screening to ensure that the targeted lesions are visible on the USG localisation system. An anaesthesiologist will assess the patient's co-morbidities and suitability for general anaesthesia as many patients may be unfit for open surgery. Standard fasting and drug administration guidelines apply. Before treatment starts, the patient's skin is cleansed with degassed water and a negative-pressure aspirator is used to degas the skin and reduce the dampening effect of ultrasonic waves.

We use the JC HIFU system (Chongqing Haifu Technology, Chongqing, China); HIFU ablation is performed under general anaesthesia by a team of surgeons and radiologists. Total intravenous anaesthesia is favoured in our centre because of its titratability, avoidance of nitrous oxide, and no need for scavenging waste anaesthetic gases that may be hazardous to the health of attendant staff.⁴⁸ A dose of antibiotic (Augmentin 1.2 g; Beecham Pharmaceuticals, Brentford, UK) is given just before the procedure begins. Artificial pleural effusion of 500 mL of normal saline is introduced if the liver tumour is located at the dome, in order to facilitate better ultrasound access to this region and protect the lung. In addition, intermittent cessation of respiratory movement by the anaesthesiologist facilitates better localisation of the lesions during energy transfer. For right-sided lesions, the patient is placed in the right lateral position after tracheal intubation. For left-sided lesions, the patient is placed in the prone position. The JC HIFU system consists of a treatment unit that delivers focused ultrasound energy with a focal length of 12 cm deep. The body is immersed in a degassed water circulation unit that

provides a medium for ultrasound transmission. Grey-scale changes at the ablation site are observed during the procedure, indicating the temperature change inside the targeted lesion. Oral antibiotics are given for 5 days after treatment.⁴⁹

When ablating a large tumour, the ultrasound energy is focused on the deep margin of the lesion first so as to avoid prohibition of effective penetration of energy by the cavitation effect and the presence of coagulation necrosis. Meticulous planning of the focus point before the procedure, in which the ablation sequence is from the deepest layer to the most superficial layer, is required for maximal destruction of the targeted lesion. Intermittent cessations of the procedure allow recovery of the cavitation effect shown under USG monitoring, giving additional allowance for ablation of the residual lesion in the periphery.⁵⁰

Treatment results

Although a minimally invasive approach can be employed in patients with HCC and liver cirrhosis, hepatectomy is contra-indicated in patients with decompensated cirrhosis.⁵¹ Our pilot studies suggested that HIFU is relatively safe and effective.^{52,53} Patients who have poor liver function can still be offered HIFU.⁵⁴ Its effectiveness in treating small HCC of size <3 cm was proven to be comparable with percutaneous RFA.⁵⁵ Furthermore, its application in recurrent HCC allows patients to undergo ablation, especially when the abdomen is hostile due to previous surgery, or there is inadequate liver remnant due to previous major hepatectomy.⁵⁶ In the treatment of HCC in non-surgical candidates, 1- and 3-year overall survival rates of 87.7% and 62.4%, respectively were achieved in 49 patients with a median tumour size of 2.2 cm.⁴⁹ In addition, our prospective study suggested that the response rate for those patients with HCC who underwent HIFU as the bridging treatment while awaiting cadaveric liver transplantation was higher than in those who underwent transarterial chemoembolisation.⁵² It is particularly useful in patients who also have poor liver function with clinical ascites, as ascites itself is a good acoustic media for HIFU.⁵⁷

High-intensity focused ultrasound does carry certain risks in the treatment for HCC. Minor complications such as skin and subcutaneous tissue injury occur in most patients.⁵⁴ At our centre, there has been a case of post-HIFU bile duct stricture requiring endoscopic retrograde cholangiography.

Pancreatic cancer

Inoperable locally advanced pancreatic cancer remains difficult to treat. Local ablative therapy with HIFU has been used in patients with unresectable pancreatic cancer and proven to be safe in both clinical trials and retrospective studies,^{31,58-60} with

no damage to the exocrine or endocrine function.⁶¹⁻⁶³ It has been used as a form of palliative treatment in some pilot studies with a median survival ranging from 10 to 12.6 months, either alone or combined with chemotherapy.⁶²⁻⁶⁵ Pain relief was also found to be effective.^{31,58,59,63,65,66} Unfortunately, treatment after HIFU usually lacked histomorphological examination. The survival benefit needs to be tested in further studies, and preferably confirmed by randomised controlled trials.

Urological applications

Prostate cancer

Transrectal HIFU is advocated as a form of minimally invasive treatment for localised prostate cancer. It is suggested primarily for patients with low- to intermediate-risk prostate cancer, according to D'Amico Risk stratification.⁶⁷⁻⁷² It has also been used to treat locally recurrent prostate cancer. Patients with unifocal and multifocal prostate cancer were subjected to HIFU and had no evidence of disease on MRI at 12 months.⁷³ Good functional outcome was achieved after the treatment, such as continence and good erectile function. Nonetheless, complications such as acute retention of urine or more severe rectal wall injury can occur. More sophisticated MRI-guided HIFU will allow more precise localisation of such lesions.⁷⁴ To date, most studies have been in the form of retrospective studies or case series only with no randomised controlled trial of HIFU for the treatment of prostate cancer.

Renal tumours

International consensus panels recommend ablative techniques in patients who are unfit for surgery, who are not considered candidates for or elect against active surveillance, and who have a small renal mass.^{75,76} European Association of Urology guidelines recommend the use of an ablative method only in tumours of less than 4 cm.⁷⁶ In fact, HIFU has been investigated in the treatment of both primary and metastatic renal tumours.⁷⁷⁻⁷⁹ Results suggest that there were discrete zones of ablation in 67% of patients in the final histology and HIFU achieved stable lesions in two thirds of patients with minimal morbidity; 90% of patients had good pain control immediately after HIFU.⁷⁹ There were several limitations, however, such as the degree of subcutaneous and perinephric fat and the position of the tumour in relation to the ribs.⁸⁰ Higher acoustic output is needed to compensate for the energy loss due to the thickness of the perinephric fat that might in turn increase the risk of prefocal and surrounding tissue damage.⁸¹ Currently, there is no controlled study to suggest the superiority of HIFU over various ablative techniques, such as RFA or cryoablation.

Brain diseases

High-intensity focused ultrasound was first used in the 1950s to treat Parkinson's disease.⁸²⁻⁸⁴ It required access through the skull to the brain and, therefore, craniotomy was necessary. It subsequently became unpopular due to the concurrent development of the drug levodopa. With the advancement of MRI guidance, there has been a resurgence of interest as a non-invasive treatment for essential tremor, neuropathic pain, and Parkinson's disease. It is safe, without major risk of infection or bleeding, but may result in transient oedema. In Parkinson's disease, as the disease progresses, patients will eventually require levodopa that is associated with tolerance and, eventually, development of levodopa-resistant symptoms with movement fluctuations and dyskinesias. At this time surgical intervention may be considered. High-intensity focused ultrasound can allow ablation of the fibres that join the thalamus with the globus pallidus. Results of a pilot study suggested that there was improvement in terms of the functional score as rated by the Unified Parkinson's Disease Rating Scale.⁸⁵

Essential tremor is a common neurological condition usually managed conservatively, or with propranolol and primidone. For those treatment-resistant patients, surgical intervention may be considered. Usually RFA, stereotactic radiosurgery, gamma knife thalamotomy, or deep brain stimulation are used to either cause tissue destruction or to block abnormal nerve signals. High-intensity focused ultrasound has been used in a clinical trial context with promising results and marked reduction (>80%) of tremor.^{86,87}

Neuropathic pain is a complex condition often associated with damage to or dysfunction of the nerve fibres that then send incorrect signals to the pain centres with minimal stimulation. High-intensity focused ultrasound can be directed to the part of the central lateral thalamic nucleus of those patients suffering from chronic therapy-resistant neuropathic pain. Significant pain relief has been observed with long-term follow-up in a pilot study.⁸⁸

Breast tumour

High-intensity focused ultrasound is an ideal breast-conserving therapy because it does not significantly change the patients' breast shape and does not cause bleeding or scarring. It does not require general anaesthesia, and hence has a reduced recovery time. Both USG- and MRI-guided HIFU ablations have been used. The aim is to achieve complete tumour necrosis but results have been inconsistent with some showing complete necrosis,⁸⁹ and others residual tumour of less than 10% and residual tumour between 10% and 90%.⁹⁰⁻⁹⁴ A negative margin is the most important basis and factor for local control

of the breast cancer.^{95,96} Nonetheless, it is difficult to ensure a negative margin after HIFU therapy with the aid of imaging alone, hence adjuvant radiotherapy has been suggested. Currently, there is limited prospective study or randomised trial in this area. Most work has been pilot studies or feasibility studies only.

Complications include pain, skin burns, oedema, pectoralis major muscle injury,⁹⁷ and rib pain.⁹⁸ These are relatively minor compared with those following traditional breast surgery with its attendant potential complications of wound pain, infection, bleeding, and impaired wound healing.

Fibroids

Uterine fibroid is a common benign gynaecological condition in women of childbearing age. Patients usually suffer symptoms such as heavy, painful, and prolonged menstrual bleeding, mass effect with urinary urgency, and constipation.⁹⁹ Conservative medical therapy with non-steroidal anti-inflammatory drugs, contraceptive steroids, and gonadotropin-releasing hormone agonists are the first-line treatment. Ablative treatment as well as surgery will be necessary for those in whom conservative management fails or in those with progressive symptoms. Treatment is by means of myomectomy or hysterectomy. In cases where the patient does not want surgery, or where the patient is planning a future pregnancy, HIFU is a good option.^{100,101} Extracorporeal HIFU enables ablation of various sizes and shape of fibroid. Symptoms are reduced by more than 50% in terms of pain,¹⁰²⁻¹⁰⁴ bulk-related and menstrual symptoms, comparable with the results of conventional surgery.¹⁰⁵ After HIFU, the ablated fibroid volume is decreased, and is related to the non-perfused volume of the tumour immediately after treatment.^{44,106,107} Nonetheless, HIFU cannot propagate through air-filled viscera such as bowel. There is a potential risk of bowel perforation if it lies close to the fibroids.¹⁰⁸ Most of the articles were from China, as HIFU has been used in China for treatment of fibroids. In our hospital, the following criteria are used for patient selection: (1) premenopausal women with no plans for further childbearing; (2) severe fibroid symptoms (as defined by a transformed symptom severity score of >41 on the Uterine Fibroid Symptom and Quality of Life questionnaire); (3) a clinical uterine size of less than 20 weeks' gestation, a dominant fibroid of less than 10 cm in diameter without areas of necrosis as judged by contrast-enhanced MRI, a non-pedunculated fibroid, and a fibroid not suspicious of malignancy; (4) no evidence of known or suspected extensive pelvic adhesions such as history of acute pelvic inflammatory disease, severe pelvic endometriosis, or lower abdominal surgery; and (5) an abdominal wall thickness of less than 5 cm.¹⁰⁹

Bone tumour

Bone metastases

In palliative treatment of bone tumours, therapeutic goals include pain palliation, tumour reduction, prevention of impending pathological fractures, and/or tumour decompression. Opioid analgesics and radiation therapy are widely used for pain control in patients suffering from bone metastases but this does not always provide desired relief in many patients and is associated with undesirable side-effects.¹¹⁰⁻¹¹⁵ Research reveals that MRI-guided HIFU is safe and effective in the treatment of painful bone tumours.¹¹⁶⁻¹¹⁸ Periosteal denervation and tumour debulking may play a significant role in symptom relief.^{74,116,117} Response to HIFU is rapid and good pain control has been seen within days of treatment. This greatly improves the quality of life for many patients with disseminated cancer.¹¹⁹ There is also evidence of a reduction in lesion viability after HIFU and a remineralisation of spongy bone.¹²⁰

Tumour ablation in curative treatment aims for complete coagulation necrosis of the primary lesion. Primary bone malignancy such as osteosarcoma has been treated with HIFU. A combination of chemotherapy with HIFU seems to be as effective as limb-sparing surgery and chemotherapy for malignant bone tumours.¹²¹ This is potentially useful for patients who are not fit for surgery. Treatment complications include skin burns, procedure-related pain, and post-treatment fractures.^{121,122} Most of the studies were clinical trials. More studies should focus on the treatment outcome in terms of the function, quality of life, and survival.

Glaucoma

The specific advantage of HIFU is that the energy can be focused through non-optically transparent media without uncontrolled energy absorption, thus reducing the effects on adjacent tissues. It allows a defined and adjustable tissue volume to be heated and treated at any depth or location within the eye. Intra-ocular pressure is decreased both by reducing aqueous humour production (aqueous inflow) and by facilitating the evacuation of aqueous humour from the eye (aqueous outflow).¹²³ Prospective case series suggest there is a significant reduction in intra-ocular pressure without significant peri- or post-treatment side-effects.¹²⁴

Atrial fibrillation

High-intensity focused ultrasound has been used to treat atrial fibrillation in cardiac surgery. This is designed to deliver pulmonary vein and posterior left atrial wall isolation on the beating heart using an encircling 'cinch' and create left atrial lines using a handheld wand device. It then ablates areas around the ganglionic plexi where dense collections of

complex fractionated atrial electrograms are found. It has been proven to be safe and effective.¹²⁵ Patients can be reverted to sinus rhythm and the results are more pronounced in patients with paroxysmal atrial fibrillation.^{46,126} Selected use of this technique has been suggested.¹²⁷ If symptoms persist, other modalities should be considered.¹²⁵

Conclusions

High-intensity focused ultrasound has many applications in both benign and malignant diseases. It offers an alternative to those patients for whom surgery is contra-indicated or inappropriate. The results of HIFU in the management of HCC patients in our centre are particularly promising. Further studies of the application of HIFU in various organs should be conducted for both clinical trials as well as comparative studies with other ablative modalities in the form of randomised controlled trials.

Declaration

No funding was received for the study or its publication. None of the authors has any conflict of interest with regard to the study or its publication.

References

- Lynn JG, Zwemer RL, Chick AJ, Miller AE. A new method for the generation and use of focused ultrasound in experimental biology. *J Gen Physiol* 1942;26:179-93.
- Fry WJ, Fry FJ. Fundamental neurological research and human neurosurgery using intense ultrasound. *IRE Trans Med Electron* 1960;ME-7:166-81.
- Lynn JG, Putnam TJ. Histology of cerebral lesions produced by focused ultrasound. *Am J Pathol* 1944;20:637-49.
- Coleman DJ, Lizzi FL, el-Mofty AA, Driller J, Franzen LA. Ultrasonically accelerated resorption of vitreous membranes. *Am J Ophthalmol* 1980;89:490-9.
- Coleman DJ, Lizzi FL, Torpey JH, et al. Treatment of experimental lens capsular tears with intense focused ultrasound. *Br J Ophthalmol* 1985;69:645-9.
- Coleman DJ, Lizzi FL, Driller J, et al. Therapeutic ultrasound in the treatment of glaucoma. II. Clinical applications. *Ophthalmology* 1985;92:347-53.
- Rosenberg RS, Purnell EW. Effects of ultrasonic radiation to the ciliary body. *Am J Ophthalmol* 1967;63:403-9.
- Silverman RH, Vogelsang B, Rondeau MJ, Coleman DJ. Therapeutic ultrasound for the treatment of glaucoma. *Am J Ophthalmol* 1991;111:327-37.
- Rosecan LR, Iwamoto T, Rosado A, Lizzi FL, Coleman DJ. Therapeutic ultrasound in the treatment of retinal detachment: clinical observations and light and electron microscopy. *Retina* 1985;5:115-22.
- Mearini L. High intensity focused ultrasound, liver disease and bridging therapy. *World J Gastroenterol* 2013;19:7494-9.
- Dubinsky TJ, Cuevas C, Dighe MK, Kolokythas O, Hwang JH. High-intensity focused ultrasound: current potential and oncologic applications. *AJR Am J Roentgenol* 2008;190:191-9.
- Yang R, Reilly CR, Rescorla FJ, et al. High-intensity focused ultrasound in the treatment of experimental liver cancer. *Arch Surg* 1991;126:1002-9; discussion 1009-10.
- Holland CK, Apfel RE. Thresholds for transient cavitation produced by pulsed ultrasound in a controlled nuclei environment. *J Acoust Soc Am* 1990;88:2059-69.
- Marmottant P, Hilgenfeldt S. Controlled vesicle deformation and lysis by single oscillating bubbles. *Nature* 2003;423:153-6.
- Pitt WG, Hussein GA, Staples BJ. Ultrasonic drug delivery—a general review. *Expert Opin Drug Deliv* 2004;1:37-56.
- Vaezy S, Shi X, Martin RW, et al. Real-time visualization of high-intensity focused ultrasound treatment using ultrasound imaging. *Ultrasound Med Biol* 2001;27:33-42.
- Sapareto SA, Dewey WC. Thermal dose determination in cancer therapy. *Int J Radiat Oncol Biol Phys* 1984;10:787-800.
- Dewhirst MW, Viglianti BL, Lora-Michiels M, Hanson M, Hoopes PJ. Basic principles of thermal dosimetry and thermal thresholds for tissue damage from hyperthermia. *Int J Hyperthermia* 2003;19:267-94.
- ter Haar GR, Robertson D. Tissue destruction with focused ultrasound in vivo. *Eur Urol* 1993;23 Suppl 1:8-11.
- Wu F, Chen WZ, Bai J, et al. Pathological changes in human malignant carcinoma treated with high-intensity focused ultrasound. *Ultrasound Med Biol* 2001;27:1099-106.
- Kim YS, Rhim H, Choi MJ, Lim HK, Choi D. High-intensity focused ultrasound therapy: an overview for radiologists. *Korean J Radiol* 2008;9:291-302.
- Li JJ, Xu GL, Gu MF, et al. Complications of high intensity focused ultrasound in patients with recurrent and metastatic abdominal tumors. *World J Gastroenterol* 2007;13:2747-51.
- Sibille A, Prat F, Chapelon JY, et al. Extracorporeal ablation of liver tissue by high-intensity focused ultrasound. *Oncology* 1993;50:375-9.
- Roberts WW, Hall TL, Ives K, Wolf JS Jr, Fowlkes JB, Cain CA. Pulsed cavitation ultrasound: a noninvasive technology for controlled tissue ablation (histotripsy) in the rabbit kidney. *J Urol* 2006;175:734-8.
- ter Haar G. Ultrasound focal beam surgery. *Ultrasound Med Biol* 1995;21:1089-100.
- Hynynen K, Freund WR, Cline HE, et al. A clinical, noninvasive, MR imaging-monitored ultrasound surgery method. *Radiographics* 1996;16:185-95.
- Yagel S. High-intensity focused ultrasound: a revolution in non-invasive ultrasound treatment? *Ultrasound Obstet Gynecol* 2004;23:216-7.
- Hynynen K, Pomeroy O, Smith DN, et al. MR imaging-guided focused ultrasound surgery of fibroadenomas in the breast: a feasibility study. *Radiology* 2001;219:176-85.
- Dong X, Yang Z. High-intensity focused ultrasound ablation of uterine localized adenomyosis. *Curr Opin Obstet Gynecol* 2010;22:326-30.
- Jung SE, Cho SH, Jang JH, Han JY. High-intensity focused ultrasound ablation in hepatic and pancreatic cancer: complications. *Abdom Imaging* 2011;36:185-95.
- Orsi F, Zhang L, Arnone P, et al. High-intensity focused ultrasound ablation: effective and safe therapy for solid tumors in difficult locations. *AJR Am J Roentgenol* 2010;195:W245-52.
- Tempny CM, Stewart EA, McDannold N, Quade BJ, Jolesz FA, Hynynen K. MR imaging-guided focused

- ultrasound surgery of uterine leiomyomas: a feasibility study. *Radiology* 2003;226:897-905.
33. Kim YS, Keserci B, Partanen A, et al. Volumetric MR-HIFU ablation of uterine fibroids: role of treatment cell size in the improvement of energy efficiency. *Eur J Radiol* 2012;81:3652-9.
 34. Kim YS. Advances in MR image-guided high-intensity focused ultrasound therapy. *Int J Hyperthermia* 2015;31:225-32.
 35. Sanghvi NT, Foster RS, Bihrl R, et al. Noninvasive surgery of prostate tissue by high intensity focused ultrasound: an updated report. *Eur J Ultrasound* 1999;9:19-29.
 36. Beerlage HP, Thüroff S, Debruyne FM, Chaussy C, de la Rosette JJ. Transrectal high-intensity focused ultrasound using the Ablatherm device in the treatment of localized prostate carcinoma. *Urology* 1999;54:273-7.
 37. Andreou C, Blana A, Orovan W, Hassouna M, Warner J, Woods E. Technical review: high-intensity focused ultrasound for prostate cancer. *Can J Urol* 2005;12:2684-5; discussion 2686.
 38. Christopher T. HIFU focusing efficiency and a twin annular array source for prostate treatment. *IEEE Trans Ultrason Ferroelectr Freq Control* 2005;52:1523-33.
 39. Curiel L, Chavrier F, Souchon R, Birer A, Chapelon JY. 1.5-D high intensity focused ultrasound array for non-invasive prostate cancer surgery. *IEEE Trans Ultrason Ferroelectr Freq Control* 2002;49:231-42.
 40. Rebillard X, Gelet A, Davin JL, et al. Transrectal high-intensity focused ultrasound in the treatment of localized prostate cancer. *J Endourol* 2005;19:693-701.
 41. Saleh KY, Smith NB. A 63 element 1.75 dimensional ultrasound phased array for the treatment of benign prostatic hyperplasia. *Biomed Eng Online* 2005;4:39.
 42. Lindner U, Ghai S, Spensieri P, et al. Focal magnetic resonance guided focused ultrasound for prostate cancer: Initial North American experience. *Can Urol Assoc J* 2012;6:E283-6.
 43. Siddiqui K, Chopra R, Vedula S, et al. MRI-guided transurethral ultrasound therapy of the prostate gland using real-time thermal mapping: initial studies. *Urology* 2010;76:1506-11.
 44. Lafon C, Chapelon JY, Prat F, et al. Design and preliminary results of an ultrasound applicator for interstitial thermal coagulation. *Ultrasound Med Biol* 1998;24:113-22.
 45. Melodelima D, Salomir R, Chapelon JY, Theillère Y, Moonen C, Cathignol D. Intraluminal high intensity ultrasound treatment in the esophagus under fast MR temperature mapping: in vivo studies. *Magn Reson Med* 2005;54:975-82.
 46. Reyes G, Ruyra X, Valderrama F, et al. High intensity focused ultrasound ablation for atrial fibrillation: results from the National Spanish Registry. *Minerva Cardioangiolog* 2015 May 26. Epub ahead of print.
 47. Melamed S, Goldenfeld M, Cotlear D, Skaat A, Moroz I. High-intensity focused ultrasound treatment in refractory glaucoma patients: results at 1 year of prospective clinical study. *Eur J Ophthalmol* 2015;25:483-9.
 48. Yao CL, Trinh T, Wong GT, Irwin MG. Anaesthesia for high intensity focused ultrasound (HIFU) therapy. *Anaesthesia* 2008;63:865-72.
 49. Ng KK, Poon RT, Chan SC, et al. High-intensity focused ultrasound for hepatocellular carcinoma: a single-center experience. *Ann Surg* 2011;253:981-7.
 50. Cheung TT, Poon RT, Jenkins CR, et al. Survival analysis of high-intensity focused ultrasound therapy vs. transarterial chemoembolization for unresectable hepatocellular carcinomas. *Liver Int* 2014;34:e136-43.
 51. Cheung TT, Poon RT, Yuen WK, et al. Long-term survival analysis of pure laparoscopic versus open hepatectomy for hepatocellular carcinoma in patients with cirrhosis: a single-center experience. *Ann Surg* 2013;257:506-11.
 52. Cheung TT, Fan ST, Chan SC, et al. High-intensity focused ultrasound ablation: an effective bridging therapy for hepatocellular carcinoma patients. *World J Gastroenterol* 2013;19:3083-9.
 53. Wu F, Wang ZB, Chen WZ, et al. Advanced hepatocellular carcinoma: treatment with high-intensity focused ultrasound ablation combined with transcatheter arterial embolization. *Radiology* 2005;235:659-67.
 54. Cheung TT, Chu FS, Jenkins CR, et al. Tolerance of high-intensity focused ultrasound ablation in patients with hepatocellular carcinoma. *World J Surg* 2012;36:2420-7.
 55. Cheung TT, Fan ST, Chu FS, et al. Survival analysis of high-intensity focused ultrasound ablation in patients with small hepatocellular carcinoma. *HPB (Oxford)* 2013;15:567-73.
 56. Chan AC, Cheung TT, Fan ST, et al. Survival analysis of high-intensity focused ultrasound therapy versus radiofrequency ablation in the treatment of recurrent hepatocellular carcinoma. *Ann Surg* 2013;257:686-92.
 57. Chok KS, Cheung TT, Lo RC, et al. Pilot study of high-intensity focused ultrasound ablation as a bridging therapy for hepatocellular carcinoma patients wait-listed for liver transplantation. *Liver Transpl* 2014;20:912-21.
 58. Orgera G, Krokidis M, Monfardini L, et al. High intensity focused ultrasound ablation of pancreatic neuroendocrine tumours: report of two cases. *Cardiovasc Intervent Radiol* 2011;34:419-23.
 59. Wang K, Zhu H, Meng Z, et al. Safety evaluation of high-intensity focused ultrasound in patients with pancreatic cancer. *Onkologie* 2013;36:88-92.
 60. Sung HY, Jung SE, Cho SH, et al. Long-term outcome of high-intensity focused ultrasound in advanced pancreatic cancer. *Pancreas* 2011;40:1080-6.
 61. Shi Y, Ying X, Hu X, et al. Influence of high intensity focused ultrasound (HIFU) treatment to the pancreatic function in pancreatic cancer patients. *Pak J Pharm Sci* 2015;28 Suppl:1097-100.
 62. Zhao H, Yang G, Wang D, et al. Concurrent gemcitabine and high-intensity focused ultrasound therapy in patients with locally advanced pancreatic cancer. *Anticancer Drugs* 2010;21:447-52.
 63. Gao HF, Wang K, Meng ZQ, et al. High intensity focused ultrasound treatment for patients with local advanced pancreatic cancer. *Hepatogastroenterology* 2013;60:1906-10.
 64. Xiong LL, Hwang JH, Huang XB, et al. Early clinical experience using high intensity focused ultrasound for palliation of inoperable pancreatic cancer. *JOP* 2009;10:123-9.
 65. Wang K, Chen Z, Meng Z, et al. Analgesic effect of high intensity focused ultrasound therapy for unresectable pancreatic cancer. *Int J Hyperthermia* 2011;27:101-7.
 66. Wu F, Wang ZB, Zhu H, et al. Feasibility of US-guided high-intensity focused ultrasound treatment in patients with advanced pancreatic cancer: initial experience. *Radiology* 2005;236:1034-40.

67. Uchida T, Shoji S, Nakano M, et al. Transrectal high-intensity focused ultrasound for the treatment of localized prostate cancer: eight-year experience. *Int J Urol* 2009;16:881-6.
68. Blana A, Walter B, Rogenhofer S, Wieland WF. High-intensity focused ultrasound for the treatment of localized prostate cancer: 5-year experience. *Urology* 2004;63:297-300.
69. Ripert T, Azémar MD, Ménard J, et al. Six years' experience with high-intensity focused ultrasonography for prostate cancer: oncological outcomes using the new 'Stuttgart' definition for biochemical failure. *BJU Int* 2011;107:1899-905.
70. Crouzet S, Chapelon JY, Rouvière O, et al. Whole-gland ablation of localized prostate cancer with high-intensity focused ultrasound: oncologic outcomes and morbidity in 1002 patients. *Eur Urol* 2014;65:907-14.
71. Mearini L, D'Urso L, Collura D, Nunzi E, Muto G, Porena M. High-intensity focused ultrasound for the treatment of prostate cancer: A prospective trial with long-term follow-up. *Scand J Urol* 2015;49:267-74.
72. Heidenreich A, Bastian PJ, Bellmunt J, et al. EAU guidelines on prostate cancer. part 1: screening, diagnosis, and local treatment with curative intent—update 2013. *Eur Urol* 2014;65:124-37.
73. Ahmed HU, Hindley RG, Dickinson L, et al. Focal therapy for localised unifocal and multifocal prostate cancer: a prospective development study. *Lancet Oncol* 2012;13:622-32.
74. Napoli A, Anzidei M, De Nunzio C, et al. Real-time magnetic resonance-guided high-intensity focused ultrasound focal therapy for localised prostate cancer: preliminary experience. *Eur Urol* 2013;63:395-8.
75. Van Poppel H, Becker F, Cadeddu JA, et al. Treatment of localised renal cell carcinoma. *Eur Urol* 2011;60:662-72.
76. Ljungberg B, Bensalah K, Canfield S, et al. EAU guidelines on renal cell carcinoma: 2014 update. *Eur Urol* 2015;67:913-24.
77. Illing RO, Kennedy JE, Wu F, et al. The safety and feasibility of extracorporeal high-intensity focused ultrasound (HIFU) for the treatment of liver and kidney tumours in a Western population. *Br J Cancer* 2005;93:890-5.
78. Ritchie RW, Leslie T, Phillips R, et al. Extracorporeal high intensity focused ultrasound for renal tumours: a 3-year follow-up. *BJU Int* 2010;106:1004-9.
79. Wu F, Wang ZB, Chen WZ, Bai J, Zhu H, Qiao TY. Preliminary experience using high intensity focused ultrasound for the treatment of patients with advanced stage renal malignancy. *J Urol* 2003;170(6 Pt 1):2237-40.
80. Kohrman KU, Michel MS, Gaa J, Marlinghaus E, Alken P. High intensity focused ultrasound as noninvasive therapy for multilocal renal cell carcinoma: case study and review of the literature. *J Urol* 2002;167:2397-403.
81. Ritchie R, Collin J, Coussios C, Leslie T. Attenuation and de-focusing during high-intensity focused ultrasound therapy through peri-nephric fat. *Ultrasound Med Biol* 2013;39:1785-93.
82. Fry WJ, Mosberg WH Jr, Barnard JW, Fry FJ. Production of focal destructive lesions in the central nervous system with ultrasound. *J Neurosurg* 1954;11:471-8.
83. Fry WJ, Barnard JW, Fry EJ, Krumins RF, Brennan JF. Ultrasonic lesions in the mammalian central nervous system. *Science* 1955;122:517-8.
84. Fry FJ. Precision high intensity focusing ultrasonic machines for surgery. *Am J Phys Med* 1958;37:152-6.
85. Jeanmonod D, Moser D, Magara A, et al. Study of incisionless transcranial magnetic resonance-guided focused ultrasound treatment of Parkinson's disease: Safety, accuracy and initial clinical outcomes. Proceedings of the Current and Future Applications of Focused Ultrasound 2012, 3rd International Symposium; 2012 Oct 14-17; Washington, DC Metro Area, United States.
86. Elias WJ, Huss D, Voss T, et al. A pilot study of focused ultrasound thalamotomy for essential tremor. *N Engl J Med* 2013;369:640-8.
87. Lipsman N, Schwartz ML, Huang Y, et al. MR-guided focused ultrasound thalamotomy for essential tremor: a proof-of-concept study. *Lancet Neurol* 2013;12:462-8.
88. Jeanmonod D, Werner B, Morel A, et al. Transcranial magnetic resonance imaging-guided focused ultrasound: noninvasive central lateral thalamotomy for chronic neuropathic pain. *Neurosurg Focus* 2012;32:E1.
89. Wu F, Wang ZB, Cao YD, et al. Changes in biologic characteristics of breast cancer treated with high-intensity focused ultrasound. *Ultrasound Med Biol* 2003;29:1487-92.
90. Furusawa H, Namba K, Thomsen S, et al. Magnetic resonance-guided focused ultrasound surgery of breast cancer: reliability and effectiveness. *J Am Coll Surg* 2006;203:54-63.
91. Gianfelice D, Khiat A, Amara M, Belblidia A, Boulanger Y. MR imaging-guided focused US ablation of breast cancer: histopathologic assessment of effectiveness—initial experience. *Radiology* 2003;227:849-55.
92. Gianfelice D, Khiat A, Amara M, Belblidia A, Boulanger Y. MR imaging-guided focused ultrasound surgery of breast cancer: correlation of dynamic contrast-enhanced MRI with histopathologic findings. *Breast Cancer Res Treat* 2003;82:93-101.
93. Zippel DB, Papa MZ. The use of MR imaging guided focused ultrasound in breast cancer patients; a preliminary phase one study and review. *Breast Cancer* 2005;12:32-8.
94. Khiat A, Gianfelice D, Amara M, Boulanger Y. Influence of post-treatment delay on the evaluation of the response to focused ultrasound surgery of breast cancer by dynamic contrast enhanced MRI. *Br J Radiol* 2006;79:308-14.
95. Poggi MM, Danforth DN, Sciuto LC, et al. Eighteen-year results in the treatment of early breast carcinoma with mastectomy versus breast conservation therapy: the National Cancer Institute randomized trial. *Cancer* 2003;98:697-702.
96. van Dongen JA, Bartelink H, Fentiman IS, et al. Factors influencing local relapse and survival and results of salvage treatment after breast-conserving therapy in operable breast cancer: EORTC trial 10801, breast conservation compared with mastectomy in TNM stage I and II breast cancer. *Eur J Cancer* 1992;28A(4-5):801-5.
97. Myers MR. Transient temperature rise due to ultrasound absorption at a bone/soft-tissue interface. *J Acoust Soc Am* 2004;115:2887-91.
98. Zderic V, Foley J, Luo W, Vaezy S. Prevention of post-focal thermal damage by formation of bubbles at the focus during high intensity focused ultrasound therapy. *Med Phys* 2008;35:4292-9.
99. Vollenhoven BJ, Lawrence AS, Healy DL. Uterine fibroids: a clinical review. *Br J Obstet Gynaecol* 1990;97:285-98.

100. Wu F, Wang ZB, Chen WZ, et al. Extracorporeal focused ultrasound surgery for treatment of human solid carcinomas: early Chinese clinical experience. *Ultrasound Med Biol* 2004;30:245-60.
101. Smart OC, Hindley JT, Regan L, Gedroyc WM. Magnetic resonance guided focused ultrasound surgery of uterine fibroids—the tissue effects of GnRH agonist pretreatment. *Eur J Radiol* 2006;59:163-7.
102. Yoon SW, Kim KA, Cha SH, et al. Successful use of magnetic resonance-guided focused ultrasound surgery to relieve symptoms in a patient with symptomatic focal adenomyosis. *Fertil Steril* 2008;90:2018.e13-5.
103. Fennessy FM, Tempany CM, Mc Dannold NJ, et al. Uterine leiomyomas: MR imaging-guided focused ultrasound surgery—results of different treatment protocols. *Radiology* 2007;243:885-93.
104. Lénárd ZM, Mc Dannold NJ, Fennessy FM, et al. Uterine leiomyomas: MR imaging-guided focused ultrasound surgery—imaging predictors of success. *Radiology* 2008;249:187-94.
105. Mikami K, Murakami T, Okada A, Osuga K, Tomoda K, Nakamura H. Magnetic resonance imaging-guided focused ultrasound ablation of uterine fibroids: early clinical experience. *Radiat Med* 2008;26:198-205.
106. LeBlang SD, Hoctor K, Steinberg FL. Leiomyoma shrinkage after MRI-guided focused ultrasound treatment: report of 80 patients. *AJR Am J Roentgenol* 2010;194:274-80.
107. Zhang L, Chen WZ, Liu YJ, et al. Feasibility of magnetic resonance imaging-guided high intensity focused ultrasound therapy for ablating uterine fibroids in patients with bowel lies anterior to uterus. *Eur J Radiol* 2010;73:396-403.
108. Kennedy JE, Ter Haar GR, Cranston D. High intensity focused ultrasound: surgery of the future? *Br J Radiol* 2003;76:590-9.
109. Cheung VY. Sonographically guided high-intensity focused ultrasound for the management of uterine fibroids. *J Ultrasound Med* 2013;32:1353-8.
110. Chow E, Harris K, Fan G, Tsao M, Sze WM. Palliative radiotherapy trials for bone metastases: a systematic review. *J Clin Oncol* 2007;25:1423-36.
111. Hartsell WF, Scott CB, Bruner DW, et al. Randomized trial of short- versus long-course radiotherapy for palliation of painful bone metastases. *J Natl Cancer Inst* 2005;97:798-804.
112. Cleland CS. The measurement of pain from metastatic bone disease: capturing the patient's experience. *Clin Cancer Res* 2006;12(20 Pt 2):6236s-42s.
113. van der Linden YM, Lok JJ, Steenland E, et al. Single fraction radiotherapy is efficacious: a further analysis of the Dutch Bone Metastasis Study controlling for the influence of retreatment. *Int J Radiat Oncol Biol Phys* 2004;59:528-37.
114. Mundy GR. Metastasis to bone: causes, consequences and therapeutic opportunities. *Nat Rev Cancer* 2002;2:584-93.
115. Saarto T, Janes R, Tenhunen M, Kouri M. Palliative radiotherapy in the treatment of skeletal metastases. *Eur J Pain* 2002;6:323-30.
116. Catane R, Beck A, Inbar Y, et al. MR-guided focused ultrasound surgery (MRgFUS) for the palliation of pain in patients with bone metastases—preliminary clinical experience. *Ann Oncol* 2007;18:163-7.
117. Gianfelice D, Gupta C, Kucharczyk W, Bret P, Havill D, Clemons M. Palliative treatment of painful bone metastases with MR imaging-guided focused ultrasound. *Radiology* 2008;249:355-63.
118. Liberman B, Gianfelice D, Inbar Y, et al. Pain palliation in patients with bone metastases using MR-guided focused ultrasound surgery: a multicenter study. *Ann Surg Oncol* 2009;16:140-6.
119. Zeng L, Chow E, Bedard G, et al. Quality of life after palliative radiation therapy for patients with painful bone metastases: results of an international study validating the EORTC QLQ-BM22. *Int J Radiat Oncol Biol Phys* 2012;84:e337-42.
120. Napoli A, Anzidei M, Marincola BC, et al. Primary pain palliation and local tumor control in bone metastases treated with magnetic resonance-guided focused ultrasound. *Invest Radiol* 2013;48:351-8.
121. Chen W, Zhu H, Zhang L, et al. Primary bone malignancy: effective treatment with high-intensity focused ultrasound ablation. *Radiology* 2010;255:967-78.
122. Hurwitz MD, Ghanouni P, Kanaev SV, et al. Magnetic resonance-guided focused ultrasound for patients with painful bone metastases: phase III trial results. *J Natl Cancer Inst* 2014;106:dju082.
123. Aptel F, Begle A, Razavi A, et al. Short- and long-term effects on the ciliary body and the aqueous outflow pathways of high-intensity focused ultrasound cyclocoagulation. *Ultrasound Med Biol* 2014;40:2096-106.
124. Aptel F, Dupuy C, Rouland JF. Treatment of refractory open-angle glaucoma using ultrasonic circular cyclocoagulation: a prospective case series. *Curr Med Res Opin* 2014;30:1599-605.
125. Davies EJ, Bazerbashi S, Asopa S, Haywood G, Dalrymple-Hay M. Long-term outcomes following high intensity focused ultrasound ablation for atrial fibrillation. *J Card Surg* 2014;29:101-7.
126. Garcia R, Sacher F, Oses P, et al. Electrophysiological study 6 months after Epicor high-intensity focused ultrasound atrial fibrillation ablation. *J Interv Card Electrophysiol* 2014;41:245-51.
127. Colli A, Romero-Ferrer B. It is time to revisit the theory of acute conduction block: efficacy of high-intensity focused ultrasound epicardial ablation. *Eur J Cardiothorac Surg* 2013;43:451-2.