

# Intracoronary thrombus in an 18-year-old teenager. Why?

Mert I Hayiroglu, MD, Adnan Kaya \*, MD, Sahin Avsar, MD, Nijat Bakishaliev, MD, Emrah Bozbeyoglu, MD

Department of Cardiology, Dr Siyami Ersek Cardiovascular and Thoracic Surgery Hospital, Istanbul, Turkey

\* Corresponding author: adnankaya@gmail.com

Hong Kong Med J 2016;22:396–8

DOI: 10.12809/hkmj144439

## Case report

In August 2014, an 18-year-old boy with no prior history of coronary or cardiac disease presented to our tertiary cardiovascular and thoracic surgery hospital in Turkey with crushing substernal chest pain, nausea, and vomiting that had persisted for 1 hour. He had started work as a barman at a beach club 3 months earlier and denied any use of off-label drugs. His first electrocardiography (ECG) was normal with sinus rhythm (heart rate, 90 beats/min; Fig 1a). The patient, however, was tachypnoeic and reported a heavy squeezing chest discomfort. On physical examination, the pain was not relieved by position change and increased continuously.

Blood pressure was 142/75 mm Hg and pulse oximetry showed oxygen saturation to be 94%. Chest auscultation was normal, as was chest X-ray. Cardiomegaly and pneumothorax were absent and the mediastinum was not widened.

Smoking was the only risk factor for developing coronary artery disease in this young patient. Hypertension, diabetes mellitus, hyperlipidaemia, family history of heart disease, and obesity were absent as risk factors for coronary artery disease.

The patient was thought to have myocarditis and ibuprofen was prescribed for symptom relief. The pain worsened, however, and ECG showed widened QRS complexes (right bundle branch block pattern in precordial derivations) with a rate of 112 beats/min (Fig 1b). The ECG was interpreted as idioventricular rhythm. Bedside transthoracic echocardiography was performed and left ventricular anterior wall hypokinesia with 40% ejection fraction was observed. Clopidogrel and acetylsalicylic acid were started and immediate coronary angiography (CAG) was performed to identify the cause. A significant stenosis of the mid-segment of the left anterior descending (LAD) artery with a fresh thrombus image was present with distal TIMI-3 flow (Thrombolysis In Myocardial Infarction grade 3, which implies normal flow that fills the distal coronary bed completely) [Fig 2a]. Right coronary artery and left circumflex artery were normal. Since the patient's haemodynamic parameters were stable with TIMI-3 distal blood flow in the LAD, conservative treatment with intravenous glycoprotein 2b/3a (GP-2b3a) inhibitor was prescribed. After successful infusion of GP-2b3a without any complications, control CAG was performed (Fig 2b). Complete dissolution of thrombus was observed and left ventricular anterior hypokinesia was reversed.

The patient's laboratory findings were all within normal range except markers of myocardial damage. Troponin I level was 24 µg/L. Platelet count and liver function tests were normal, as was clotting panel. The patient's blood was screened for factor V Leiden mutation, prothrombin gene mutation, *MTHFR* gene mutation, protein C activity, protein S activity, plasminogen activator inhibitor-1 activity, homocysteine levels, and anti-cardiolipin

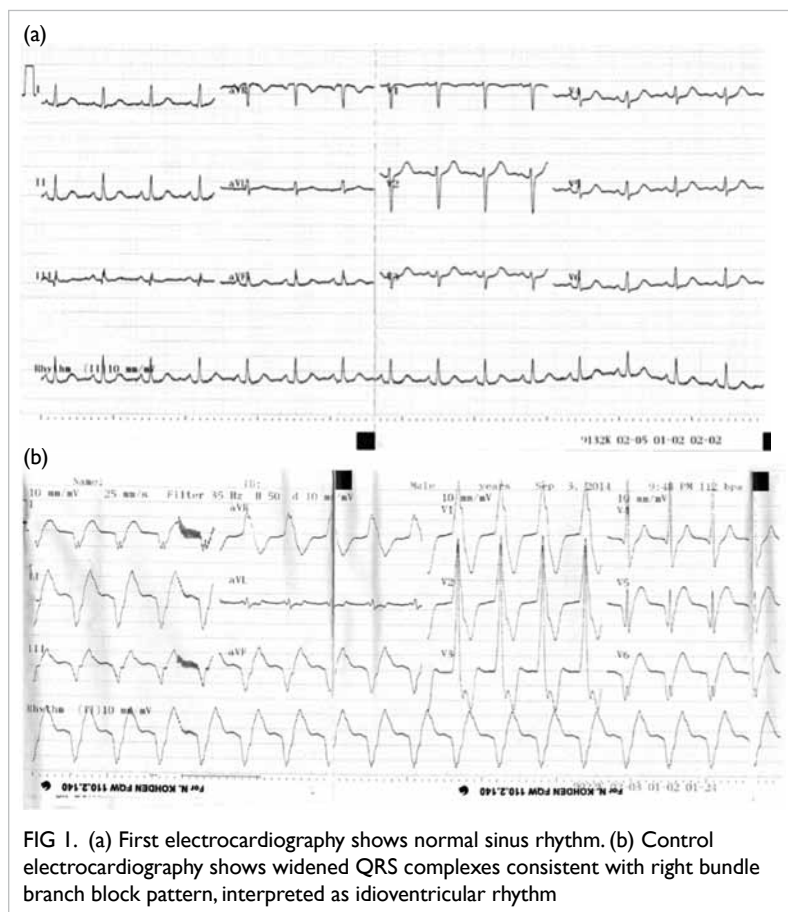


FIG 1. (a) First electrocardiography shows normal sinus rhythm. (b) Control electrocardiography shows widened QRS complexes consistent with right bundle branch block pattern, interpreted as idioventricular rhythm

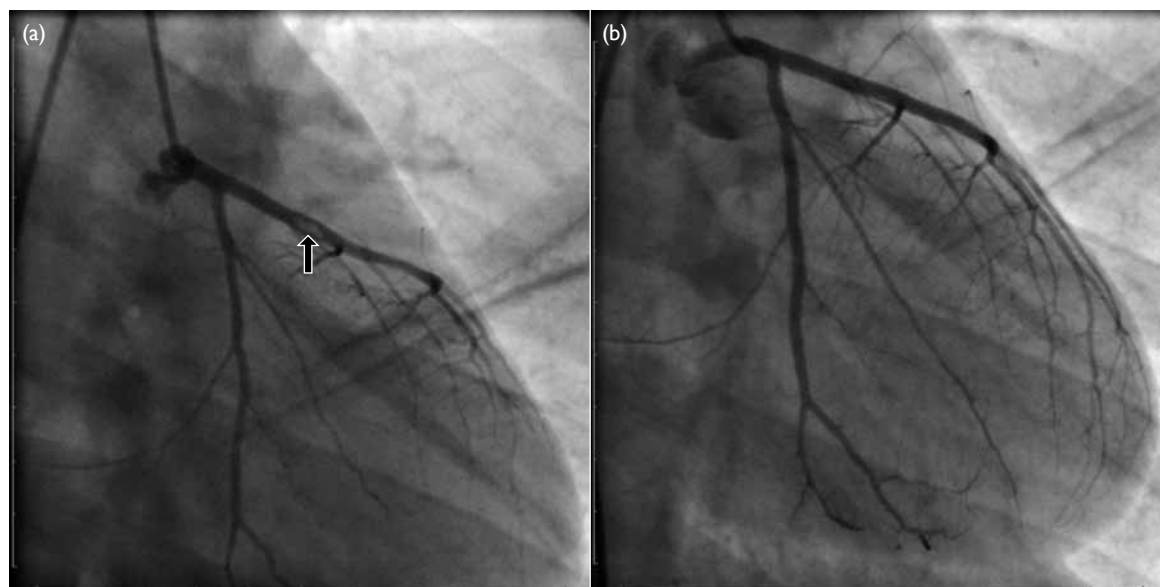


FIG 2. (a) A significant stenosis of mid-segment of left anterior descending artery with a fresh thrombus image is present with distal Thrombolysis In Myocardial Infarction grade 3 flow (arrow). (b) After successful infusion of glycoprotein 2b/3a without any complications, control coronary angiography was performed and dissolution of thrombus is observed

antibodies. No secondary aetiology was evident that could account for such thrombus formation in an 18-year-old boy so he was further questioned about drug use. This time he admitted the use of marijuana 1 hour prior to the onset of intense chest pain.

## Discussion

Acute myocardial infarction (AMI) is the leading cause of death in North America and Europe.<sup>1</sup> Despite this, AMI in an 18-year-old teenage boy is very rare. In our case the possible causes of thrombophilia were excluded and smoking of cannabis was thought to be the main cause of AMI.

Recent cannabis use is associated with acute coronary syndrome and can lead to severe cardiovascular problems and sudden death, not only in people at increased cardiovascular risk but also in young people without any medical history or risk factors.<sup>2</sup> The effects of cannabinoids are primarily mediated by the activation of cannabinoid receptors that are present in a variety of tissues including the brain (basal ganglia, pars reticulata of the substantia nigra, entopeduncular nucleus, globus pallidus, putamen, cerebellum, hippocampus, and cerebral cortex) and cells of the immune system, spleen, blood vessels, and the heart.<sup>3</sup>

The pharmacological effects of marijuana, based on stimulation of cannabinoid receptors CB1 and CB2 that are widely distributed in the cardiovascular system, have been well described. A dose-dependent increase in heart rate up to 100% of

basal rate occurs 10 to 30 minutes after beginning to smoke.<sup>4</sup> Most users experience an increase in blood pressure especially while supine<sup>4</sup> although postural hypotension after smoking marijuana is common. Tolerance to this drug can occur with frequent repeated use.<sup>5</sup> Another harmful effect of smoked marijuana is associated with an increase in carboxyhaemoglobin, resulting in decreased oxygen-carrying capacity<sup>6</sup> and subsequent demand-supply mismatch by decreasing oxygen transportation to the heart. This mechanism is suggested to underlie atherosclerotic stable coronary disease and concomitant cannabinoid use. Nonetheless in our case, the patient was too young and the lesion appearance on CAG was suggestive of a small plaque rupture with superimposed thrombus formation rather than stable atherosclerotic disease. Acute myocardial infarction associated with cannabinoid use and with normal coronary artery has been reported in the literature. Ours is an interesting case report associated with cannabinoid inhalation and superimposed thrombus formation detected by CAG. In our patient, implantation of a stent in the LAD artery was not an option because the lesion was thought to be thrombotic. Dissolution of the thrombus was achieved with GP-2b3a infusion.

Clinicians are reminded of this very rare aetiology of acute coronary syndrome and its management among young patients. Bearing in mind the increasing use of drugs such as marijuana and other synthetic cannabinoids among young people, management of associated cardiac problems is vital.

A CAG should be performed whenever drug abuse is suspected in any patient who presents with chest pain. If a thrombotic lesion is detected on CAG, infusion of GP-2b3a may dissolve the thrombus.

### References

1. Griffin BP, editor. Manual of cardiovascular medicine. 3rd ed. Philadelphia: Lippincott Williams and Wilkins; 2009: 1.
2. Casier I, Vanduyhoven P, Haine S, Vrints C, Jorens PG. Is recent cannabis use associated with acute coronary syndromes? An illustrative case series. *Acta Cardiol* 2014;69:131-6.
3. Járαι Z, Wagner JA, Varga K, et al. Cannabinoid-induced mesenteric vasodilation through an endothelial site distinct from CB1 or CB2 receptors. *Proc Natl Acad Sci USA* 1999;96:14136-41.
4. Johnson S, Domino EF. Some cardiovascular effects of marihuana smoking in normal volunteers. *Clin Pharmacol Ther* 1971;12:762-8.
5. Benowitz NL, Jones RT. Cardiovascular effects of prolonged delta-9-tetrahydrocannabinol ingestion. *Clin Pharmacol Ther* 1975;18:287-97.
6. Aronow WS, Cassidy J. Effect of marihuana and placebo-marihuana smoking on angina pectoris. *N Engl J Med* 1974;291:65-7.