

# Unexplained childhood anaemia: idiopathic pulmonary hemosiderosis

KK Siu \*, Rever Li, SY Lam

## ABSTRACT

This report demonstrates pulmonary haemorrhage as a differential cause of anaemia. Idiopathic pulmonary hemosiderosis is a rare disease in children; it is classically described as a triad of haemoptysis, pulmonary infiltrates on chest radiograph, and iron-deficiency anaemia. However, anaemia may be the only presenting feature of idiopathic pulmonary hemosiderosis in children due to occult pulmonary haemorrhage. In addition, the serum ferritin is falsely high in idiopathic pulmonary hemosiderosis which increases the diagnostic difficulty. We recommend that pulmonary haemorrhage be suspected in any

child presenting with iron-deficiency anaemia and persistent bilateral pulmonary infiltrates.

Hong Kong Med J 2015;21:172-4

DOI: 10.12809/hkmj144237

<sup>1</sup> KK Siu \*, MB, ChB, MRCPCH

<sup>2</sup> R Li, MB, ChB, FHKAM (Paediatrics)

<sup>2</sup> SY Lam, MB, BS, FHKAM (Paediatrics)

<sup>1</sup> Department of Paediatrics, Kwong Wah Hospital, Yaumatei, Hong Kong

<sup>2</sup> Department of Paediatrics, Tuen Mun Hospital, Tuen Mun, Hong Kong

\* Corresponding author: skk053@ha.org.hk

## Case report

We report the case of a 5-year-old boy, who presented with recurrent episodes of unexplained iron-deficiency anaemia in February 2010 since the age of 27 months. Serial chest X-rays (CXR) showed bilateral reticulonodular haziness. Bronchoalveolar lavage and lung biopsy confirmed the diagnosis of idiopathic pulmonary hemosiderosis (IPH).

The patient first presented at 27 months of age in Mainland China with malaise, loss of appetite, and shortness of breath for 10 days. He did not have fever, cough, or haemoptysis. He received two doses of H1N1 vaccination before pallor was noted. There was no history of drug or herb intake.

The presenting haemoglobin (Hb) level was 65 g/L (reference range [RR], 115-145 g/L), mean corpuscular volume (MCV) 84.4 fL (RR, 76-90 fL), mean corpuscular haemoglobin (MCH) level 25.8 pg (RR, 25-31 pg), and reticulocyte count 10.4% (reference level [RL], <2%). White cell count and platelet count were unremarkable. Blood smear showed moderate anisopoikilocytosis with polychromasia. Bone marrow aspiration and trephine biopsy revealed active marrow with erythroid preponderance.

Other investigations were performed for anaemia. Serum lactate dehydrogenase (LDH) level was elevated to 980 U/L (RL, <615 U/L). Haptoglobin level was reduced (<0.09 g/L; RR, 0.3-2.7 g/L). Direct Coombs test was negative. Bilirubin was normal. Urine for bilirubin and urobilinogen was negative. Haemoglobin pattern, serum vitamin B12, and G6PD activity were unremarkable. Serum ferritin level was 137 pmol/L (RR, 45-449 pmol/L). Antinuclear antibody assay was negative. Flow cytometry

showed normal expression of CD55 and CD59 which ruled out paroxysmal nocturnal haemoglobinuria. Donath-Landsteiner antibody assay was negative, which excluded the diagnosis of paroxysmal cold haemoglobinuria.

Blood work for viral infection including antibodies to parvovirus, Epstein-Barr virus (EBV), mycoplasma, and viral titres was unremarkable.

Screening for blood loss was negative. Stool for occult blood and urine for Hb were negative. Red blood cell scan showed no evidence of haemorrhage.

Blood transfusion was given to correct the anaemia. Microcytic hypochromic anaemia was noted at 2 months after presentation. Haemoglobin level was 54 g/L. Mean corpuscular volume dropped from 84.4 fL to 68 fL. Mean corpuscular haemoglobin level was 21.3 pg. Iron profile showed a low serum iron level of 3 µmol/L (RR, 5-20 µmol/L), elevated total iron-binding capacity (TIBC) of 70 µmol/L (RR, 37-68 µmol/L), and iron saturation of 4% (RR, 20-55%). However, the serum ferritin level was normal at 220 pmol/L (RR, 45-449 pmol/L). Iron supplement was started as a therapeutic trial for suspected iron-deficiency anaemia.

His Hb level remained stable in the next 2 years. However, in the subsequent 8 months, there were three intermittent episodes of anaemia (lowest Hb level, 60 g/L). The anaemia occurred with fever and cough which were considered symptoms of pneumonia and upper respiratory tract infection. There was no history of haemoptysis.

At 36 months after the presentation, he was admitted again for pallor, fatigue, and fever. This time, he needed oxygen therapy. Chest was clear with mild subcostal insucking. Hepatomegaly of

4 cm below the costal margin was noted. Chest X-ray showed bilateral reticulonodular haziness (Fig 1). Haemoglobin level was 61 g/L. Both MCV (78 fL) and MCH level (25 pg) were in the lower normal limits. The serum ferritin level was 879 pmol/L. A diagnosis of pneumonia was made; he was started on oral co-amoxiclav (amoxicillin and clavulanic acid) and azithromycin and given blood transfusion. Fever subsided and oxygen was weaned off. Ultrasonography of abdomen performed 1 month later showed no hepatomegaly; mild hepatic coarsening was suggestive of parenchymal disease. Liver function tests were normal all along. However, the patient tested positive for EBV immunoglobulin (Ig) M antibodies. Thus, he was diagnosed to have pneumonia with EBV infection.

Review of old CXRs showed similar reticulonodular shadows. In view of his history of recurrent iron-deficiency anaemia and CXR findings, pulmonary hemosiderosis was suspected. Flexible bronchoscopy was performed; bronchoscopic lavage over left lingular and right middle lobe showed blood-stained fluid. Bronchoalveolar lavage yielded abundant hemosiderin-laden macrophages (HLM index, 92%). High-resolution computed tomography of thorax showed extensive ground glass opacities and reticular shadows, suggestive of interstitial lung disease. Diffuse visceral pleural brownish deposits were noted over the entire left lung on video-assisted thoracoscopy. Lung biopsy was performed to rule out systemic disorders with pulmonary capillaritis, which could cause diffuse alveolar haemorrhage (DAH). These included Goodpasture's syndrome, IgA nephropathy, Wegener's granulomatosis, systemic lupus erythematosus, and antiphospholipid syndrome. Biopsy of lung tissue showed numerous HLM. There was no evidence of capillaritis or vasculitis. Absence of fibrosis and negative exposure history also excluded

## 兒童出現不能解釋的貧血：自發性肺鐵質沉着症

邵嘉嘉、李澤荷、林樹仁

本文指出了肺出血乃貧血的其中一個鑑別原因。自發性肺鐵質沉着症是兒童一種罕見的疾病。根據文獻引述，患者會有咳血、肺X線胸片呈浸潤及缺鐵性貧血以上三個表徵。但對兒童來說，由於有隱性肺出血，貧血可能是自發性肺鐵質沉着症的唯一表徵。再者，自發性肺鐵質沉着症患者的血清鐵蛋白會呈假性高，增加了診斷的困難。我們建議兒童若出現貧血及肺雙側持續呈浸潤之情況，應及早考慮肺出血這病因。

hypersensitivity pneumonitis. Immunostaining for IgG, IgM, and IgA was negative. The overall picture was compatible with pulmonary hemosiderosis.

Further blood investigations were performed to exclude systemic causes of pulmonary haemorrhage as stated above. Antiglomerular basement membrane antibodies, rheumatoid factor, anti-neutrophil cytoplasmic antibodies, antinuclear antibodies, anti-extractable nuclear antibodies, and anti-cardiolipin IgG antibodies were not detected. Furthermore, the patient was negative for anti-transglutaminase antibody for coeliac disease. He tested weakly positive for IgE antibodies against cow's milk. Immunoglobulin pattern was unremarkable apart from mildly raised IgA antibody level at 2.28 g/L (range, 0.5-1.92 g/L). Renal function and urinalysis were normal.

A diagnosis of IPH was made based on the above findings. Oral prednisolone was started after the diagnosis for disease control. Chest X-ray performed after 3 months of prednisolone showed improvement in reticulonodular densities (Fig 2). We

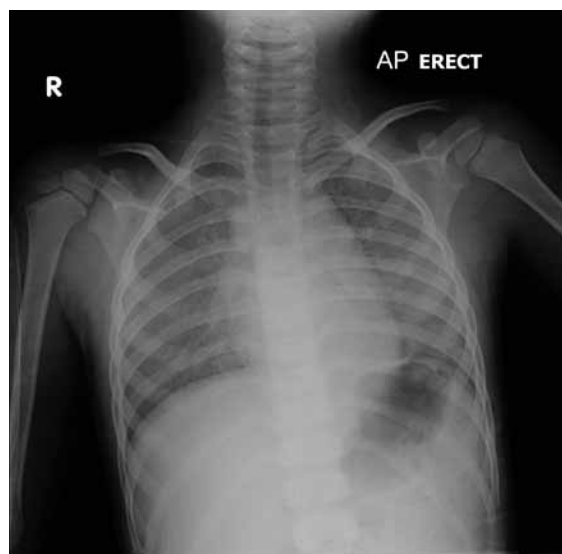


FIG 1. A chest X-ray showing bilateral reticulonodular haziness

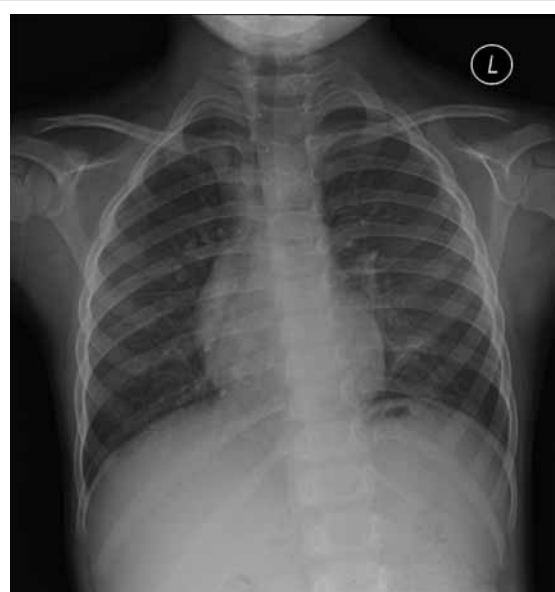

FIG 2. A chest X-ray performed after 3 months of prednisolone therapy showing improvement in reticulonodular densities

plan to monitor the disease with clinical symptoms, Hb levels, LDH levels, CXRs, and spirometry.

## Discussion

Idiopathic pulmonary hemosiderosis is a rare disease in children with an unknown aetiology. The estimated yearly incidence among Swedish children from 1960 through 1979 was 0.24 per 1000000 children.<sup>1</sup> A retrospective review of records from a tertiary paediatric hospital in northern Taiwan noted five cases over 25 years.<sup>2</sup> Patients classically presented with a triad of recurrent or chronic pulmonary symptoms (cough, dyspnoea, wheeze, haemoptysis), pulmonary infiltrates on CXR, and iron-deficiency anaemia. Our patient had only anaemia without obvious underlying causes. Subsequent CXR changes led to the suspicion of IPH.

Serum ferritin has been traditionally taken as a reliable surrogate marker of body iron stores. Hypoferritinaemia is commonly used as a diagnostic marker for iron deficiency.<sup>3</sup> However, as it is an acute-phase reactant, abnormally raised serum ferritin level may be seen during acute infection or liver disease even in the presence of iron deficiency.<sup>4</sup> In IPH, iron study usually shows low serum iron with low iron saturation, and microcytosis and hypochromia in the blood picture. However, plasma ferritin level can be normal or elevated in IPH because of alveolar synthesis and release into the circulation and does not reflect the iron deposits in the body.<sup>5</sup> This makes the diagnosis of iron-deficiency anaemia in IPH difficult. We recommend the use of serum iron and transferrin saturation (serum iron/TIBC) instead to evaluate suspected iron-deficiency anaemia.<sup>4</sup>

Diagnosis of IPH is based on exclusion of other causes of intrapulmonary haemorrhage and systemic diseases. In the absence of systemic disease, findings of HLM in bronchoscopic lavage or gastric aspirate/sputum along with chronic pulmonary symptoms lead to a diagnosis of IPH. Lung biopsy is the gold standard for diagnosis. We performed lung biopsy to exclude pulmonary capillaritis, which is one of the causes of DAH. Pulmonary capillaritis is a small-vessel vasculitis, which can occur as an isolated condition or in association with multiple systemic vasculitides. Isolated DAH without identifiable causation or associated disease is referred to as IPH.<sup>6</sup>

Daily oral corticosteroids or weekly intravenous pulse methylprednisolone is commonly used in the induction treatment of IPH. Other immunosuppressive agents such as azathioprine, cyclophosphamide, and hydroxychloroquine have also been used alone or in combination with oral corticosteroids.<sup>7-11</sup> Low-dose oral corticosteroids, azathioprine, or methotrexate are used in maintenance phase. As there is lack of large patient series and inadequate follow-up in previous studies, the prognosis of IPH remains unclear. However,

aggressive treatment with the use of corticosteroids and immunosuppressive agents are associated with a prolonged survival and improved prognosis.<sup>12</sup> Long-term low-dose corticosteroid therapy was also reported to result in a milder disease course and prevent bleeding crisis.<sup>13</sup>

In conclusion, iron-deficiency anaemia results from poor dietary intake of iron in infants and toddlers. However, every child older than 24 months presenting with iron-deficiency anaemia should be evaluated for chronic blood loss. In this report, we have illustrated that anaemia without any respiratory symptoms can be the sole presenting feature of IPH, preceding other signs and symptoms, especially in young children. Haemoptysis may not be present in young children with IPH, as they tend to swallow their sputum. We recommend that when children present with unexplained anaemia and bilateral lung infiltrations, pulmonary haemorrhage should be suspected.

## References

- Kjellman B, Elinder G, Garwicz S, Svan H. Idiopathic pulmonary haemosiderosis in Swedish children. *Acta Paediatr Scand* 1984;73:584-8.
- Yao TC, Hung IJ, Wong KS, Huang JL, Niu CK. Idiopathic pulmonary haemosiderosis: an Oriental experience. *J Paediatr Child Health* 2003;39:27-30.
- Rybo E. Diagnosis of iron deficiency. *Scand J Haematol Suppl* 1985;43:5-39.
- Li CH, Lee AC, Mak TW, Szeto SC. Transferrin saturation for the diagnosis of iron deficiency in febrile anaemic children. *Hong Kong Pract* 2003;25:363-6.
- Ioachimescu OC, Sieber S, Kotch A. Idiopathic pulmonary haemosiderosis revisited. *Eur Respir J* 2004;24:162-70.
- Fullmer JJ, Langston C, Dishop MK, Fan LL. Pulmonary capillaritis in children: a review of eight cases with comparison to other alveolar hemorrhage syndromes. *J Pediatr* 2005;146:376-81.
- Milman N, Pedersen FM. Idiopathic pulmonary haemosiderosis. Epidemiology, pathogenic aspects and diagnosis. *Respir Med* 1998;92:902-7.
- Rossi GA, Balzano E, Battistini E, et al. Long-term prednisolone and azathioprine treatment of a patient with idiopathic pulmonary hemosiderosis. *Pediatr Pulmonol* 1992;13:176-80.
- Colombo JL, Stolz SM. Treatment of life-threatening primary pulmonary hemosiderosis with cyclophosphamide. *Chest* 1992;102:959-60.
- Zaki M, al Saleh Q, al Mutari G. Effectiveness of chloroquine therapy in idiopathic pulmonary hemosiderosis. *Pediatr Pulmonol* 1995;20:125-6.
- Bush A, Sheppard MN, Warner JO. Chloroquine in idiopathic pulmonary haemosiderosis. *Arch Dis Child* 1992;67:625-7.
- Saeed MM, Woo MS, MacLaughlin EF, Margetis MF, Keens TG. Prognosis in pediatric idiopathic pulmonary hemosiderosis. *Chest* 1999;116:721-5.
- Kiper N, Göçmen A, Özçelik U, Dilber E, Anadol D. Long-term clinical course of patients with idiopathic pulmonary hemosiderosis (1979-1994): prolonged survival with low-dose corticosteroid therapy. *Pediatr Pulmonol* 1999;27:180-4.