

# Delayed cholestatic hepatitis due to methimazole

YT Hung, WK Yu, E Chow

**We report on a 71-year-old man who presented to the medical department of Our Lady of Maryknoll Hospital with progressive cholestatic hepatitis. Tests for hepatitis viral markers gave negative results and ultrasonography revealed no dilated bile ducts. Endoscopic retrograde cholangiopancreatography showed a normal biliary tree. The patient had completed a 5-month course of methimazole to treat thyrotoxicosis a few weeks before the onset of the jaundice. Methimazole was suspected to be the cause of the cholestatic hepatitis; this diagnosis was supported by the results from a liver biopsy. The presentation of the patient was unusual by virtue of the delayed onset and prolonged course of cholestasis.**

*HKMJ 1999;5:200-1*

*Key words: Cholestasis/chemically induced; Hepatitis, toxic; Methimazole/adverse effects*

## Introduction

Methimazole and carbimazole are commonly prescribed for patients who are thyrotoxic. The serious side effect of agranulocytosis caused by these two drugs is well known. In this case report, we present a rare case of delayed cholestatic hepatitis due to methimazole treatment.

## Case report

A 71-year-old man presented to a private practitioner in April 1996 with a hand tremor. Thyrotoxicosis was diagnosed and the patient was given a 5-month course of methimazole. In December 1996, jaundice developed and the patient produced tea-coloured urine and pale, bulky stool. He was tested for the presence of viral hepatitis markers; results were negative. Ultrasonography of the abdomen did not show any obstruction, and this was confirmed by endoscopic retrograde cholangiopancreatography, which showed a normal biliary tree. Because the cause of the jaundice could not be settled, the patient was admitted to the medical department of Our Lady of Maryknoll Hospital for further investigation in January 1997.

The patient was deeply jaundiced and had scratch marks all over his body. He had neither hepatosplenomegaly, nor any abdominal mass; he gave no history of using herbal medicine. The serum alanine aminotransferase level was 40 U/L (normal range, 0-35 U/L), the conjugated bilirubin level was 680  $\mu\text{mol/L}$  (normal range, 0-4  $\mu\text{mol/L}$ ), and the alkaline phosphatase level was 600 U/L (normal range, 30-120 U/L). Both the thyroid-stimulating hormone and total thyroxine levels were within normal ranges; hence, hypothyroidism was excluded. Ultrasonography of the abdomen was repeated and confirmed the absence of dilated bile ducts. Cholestatic hepatitis, secondary to methimazole usage was diagnosed. Subsequently, cholestyramine, ursodeoxycholic acid, and chlorpheniramine were given. As the patient was no longer receiving methimazole, the adverse reaction to the drug was expected to subside with time. He was followed up in March 1997; the jaundice had subsided and the patient's condition had improved. The total bilirubin level was 164  $\mu\text{mol/L}$ , that of alanine aminotransferase was 90 U/L, and that of alkaline phosphatase was 253 U/L.

Because the previous ultrasound scan had revealed the presence of gallstones, and because the patient had given a history of suspected acute cholecystitis, a cholecystectomy was performed in June 1997. An intra-operative liver biopsy was also performed and showed that the portal tracts were infiltrated with lymphocytes, eosinophils, and neutrophils; that there was peripheral ductular proliferation; and evidence of feathery degeneration of hepatocytes. These features were consistent with the diagnosis of cholestatic

---

Our Lady of Maryknoll Hospital, Shatin Pass Road, Wongtaisin, Hong Kong;

Department of Medicine

YT Hung, MB, ChB, FHKAM (Medicine)

E Chow, MB, BS, FHKAM (Medicine)

Department of Surgery

WK Yu, MB, BS, FHKAM (Surgery)

Correspondence to: Dr YT Hung

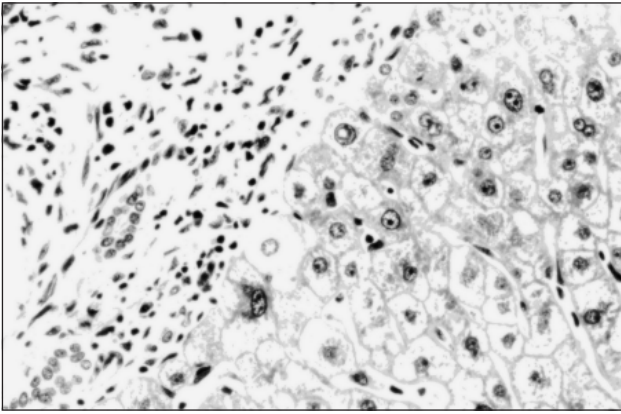


Fig. Liver biopsy showing oedema and inflammation of portal tract  
Note the ductular proliferation and cholestatic changes in hepatocytes (H&E, x28.8)

hepatitis (Fig). The eosinophilic infiltration suggested an adverse drug reaction, while the lack of bile plugs in the larger ducts or bile lakes indicated that changes secondary to the passage of gallstones were unlikely. The bilirubin level had now decreased to 15.5  $\mu\text{mol/L}$  and the alkaline phosphatase level had decreased to 173 U/L.

### Discussion

Both carbimazole and methimazole have been reported to be causes of cholestatic jaundice<sup>1</sup> and the time-course can be quite variable. In 1996, there were 20 reports of antithyroid drug-induced cholestatic hepatitis since the introduction of methimazole in 1949 and carbimazole in 1953.<sup>2</sup> This case is unusual in the following respects: jaundice developed a few weeks

after the patient had finished a 5-month course of methimazole, and the jaundice persisted for 6 months after the methimazole treatment had ceased. In contrast, Devereaux et al<sup>3</sup> have reported cases of jaundice due to flucloxacillin treatment, which began weeks after the drug treatment was stopped. Furthermore, Hunt and Washington<sup>4</sup> reported obstructive jaundice secondary to tetracycline use, in which the bilirubin level normalised 2 years after the tetracycline treatment was stopped.

This report is the first to recognise a delayed onset of a hypersensitivity reaction to methimazole from our department. Although the patient in this report had not been rechallenged with methimazole, the detailed drug history, absence of viral hepatitis markers, and the liver biopsy results indicated that methimazole was the cause of the cholestatic hepatitis.

### References

1. Sadoul JL, Canivet B, Freychet P. Toxic hepatitis induced by antithyroid drugs: four cases including one with cross-reactivity between carbimazole and benzylthiouracil. *Eur J Med* 1993;2: 473-7.
2. Schwab GP, Wetscher GJ, Vogl W, Redmond E. Methimazole-induced cholestatic liver injury, mimicking sclerosing cholangitis. *Langenbecks Arch Chir* 1996;381:225-7.
3. Devereaux BM, Crawford DH, Purcell P, Powell LW, Roeser HP. Flucloxacillin associated cholestatic hepatitis. An Australian and Swedish epidemic? *Eur J Clin Pharmacol* 1995;49:81-5.
4. Hunt CM, Washington K. Tetracycline-induced bile duct paucity and prolonged cholestasis. *Gastroenterology* 1994;107: 1844-7.