

Parvovirus B19-associated hydrops foetalis: the first confirmed case in Hong Kong

PKS Chan, KF To, SK Yip, JSL Tam, AFB Cheng

We describe a case of asymptomatic human parvovirus B19 infection during pregnancy that led to hydrops foetalis and foetal death. The diagnosis was confirmed by the presence of parvovirus B19-specific IgM antibodies in the maternal serum and the pathognomonic findings, which showed intranuclear eosinophilic viral inclusions and margination of chromatin in foetal cells of haemopoietic lineage. Details of clinical, virological, and histological findings are presented. Difficulties in confirming the diagnosis of parvovirus B19 infection in Hong Kong are discussed.

HKMJ 1998;4:321-3

Key words: Fetal death/etiology; Hydrops fetalis/etiology; Parvoviridae/immunology; Parvovirus B19, human; Pregnancy complications, infections/microbiology

Introduction

Human parvovirus B19—the only known human pathogenic parvovirus—was discovered accidentally in 1975 by Yvonne Cossart and co-workers in human serum that was being screened for hepatitis B surface antigen.¹ Subsequent studies confirmed the virus' aetiological role in a broad spectrum of diseases. The immune response and haematological status of the infected host appear to be critical determinants of the clinical manifestations of parvovirus B19 infection. In the normal host, infection results in a self-limiting subclinical erythroid aplasia that is followed by a presumably immunologically mediated rash, and/or arthralgia. Parvovirus infection in individuals with decreased production of, or increased destruction of erythrocytes can result in a dramatic fall in haemoglobin level and aplastic crisis. In the immunocompromised host, parvovirus B19 infection can become chronic, resulting in a state of chronic aplastic anaemia. The virus has also been linked to haemophagocytic syndrome, vasculitis, polyarteritis nodosa, Kawasaki

disease, systemic lupus erythematosus, liver dysfunction, and heart failure.² While these findings are very interesting, the pathophysiological role of parvovirus in these diseases needs to be further substantiated.

The developing foetus, by virtue of a rapid expanding red cell volume, a diminished red cell survival (45-70 days), and an immature immune response, represents a unique host for parvovirus infection. Foetal transmission occurs in 25% to 33% of cases of maternal infection and may cause hydrops foetalis, foetal anaemia, or abortion; infection can also be a self-limiting episode.³ Studies in America and Japan have demonstrated the presence of parvovirus B19 DNA in 10% to 18% of foetuses with non-immune hydrops foetalis.^{4,5} In Hong Kong, the epidemiology of parvovirus B19 infection during pregnancy is unknown. We report, to the best of our knowledge, the first confirmed case of parvovirus B19-associated hydrops foetalis in Hong Kong in an attempt to increase the awareness and interests of local virologists, pathologists, and obstetricians about this important disease.

Case report

A 34-year-old Chinese woman who had previously delivered a normal full-term male infant was in her second pregnancy. Her foetus was found to be hydropic following a routine ultrasound scan at 20 weeks of gestation in October 1996. On the following day, she was admitted to the Prince of Wales Hospital for

The Chinese University of Hong Kong, Prince of Wales Hospital, Shatin, Hong Kong:

Department of Microbiology

PKS Chan, MSc, MRCPPath

JSL Tam, PhD

AFB Cheng, MD, FRCPath

Department of Anatomical and Cellular Pathology

KF To, MB, ChB, FRCPA

Department of Obstetrics and Gynaecology

SK Yip, MRCOG, FHKAM (Obstetrics and Gynaecology)

Correspondence to: Dr PKS Chan

treatment. During an extended interview, the patient recalled that both the frequency and intensity of foetal movements had decreased for 2 weeks. She had not experienced any symptoms such as fever, rash, malaise, or arthralgia. The maternal blood group was B rhesus positive and there were no atypical antibodies; she gave no family history of inherited haemoglobinopathy. The haemoglobin level, mean red cell volume, and liver and renal functions were normal at the time of admission to hospital. An ultrasound scan performed on the day of admission revealed a singleton foetus with generalised subcutaneous oedema, ascites, and pericardial and pleural effusions. The placenta and umbilical cord were also oedematous. No foetal heart movements were detected and intrauterine death was diagnosed. A macerated pale hydropic foetus was delivered by induction.

Virological investigations

The maternal blood sample that was taken on the day of admission (20 weeks of gestation) was positive for both immunoglobulins (Ig) G and M (titres, 1:512 and 1:32, respectively) against parvovirus B19, by using a parvovirus B19 recombinant VP1 antigen-based immunofluorescent assay (Biotrin International, Dublin, Ireland). A pretreatment step, as recommended by the manufacturer, was performed to minimise interference of the IgM test by rheumatoid factor and the high level of IgG. Immunoglobulin M antibodies to rubella virus, cytomegalovirus, and *Toxoplasma gondii* were not detectable; rheumatoid factor was also not detectable. Antenatal blood samples taken previously were not available for testing. No viruses were isolated from placental and foetal hepatic tissues by using human foetal lung fibroblasts, monkey kidney cells, and human epithelial cell lines.

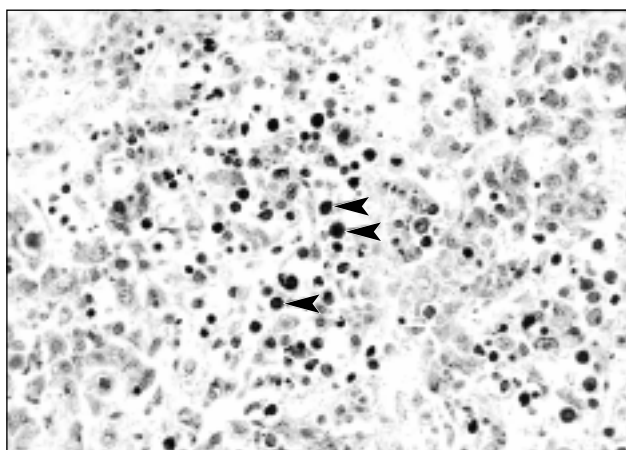


Fig 1. Section of foetal liver tissue

Numerous virus inclusion-bearing cells (arrowheads) are present in the intravascular spaces. Note the ground-glass-like nuclei and margined chromatin: typical features of parvovirus infection (H&E, x400)

Pathological findings

The slightly macerated foetus weighed 245 g; organ maturity reached that of 16 to 18 weeks of gestation. The phenotypically female foetus appeared hydropic and had generalised subcutaneous oedema, ascites, and pericardial and pleural effusions. No dysmorphic features or malformations were identified. Histological examination showed numerous cells that had eosinophilic inclusion bodies and that displayed margination of chromatin within the slightly enlarged nuclei, which had a ground-glass appearance. Such cells were present within the immature chorionic villi capillaries, hepatic sinusoids, splenic red pulps, pulmonary and renal vascular spaces, and focally within the bone marrow (Fig 1). The infected cells were interpreted as being normoblasts, erythrocyte precursor cells, and circulating nucleated red blood cells, and inclusion-bearing myocardial cells were also seen. Electron microscopy examination of foetal tissue revealed intranuclear inclusions, which is a morphological feature typical of viral infection (Fig 2). The overall findings were consistent with parvovirus B19 infection. The foetal karyotype was normal.

Discussion

The causes of hydrops foetalis can be classified as immune and non-immune types. In the immune type, the majority of cases result from incompatibility of

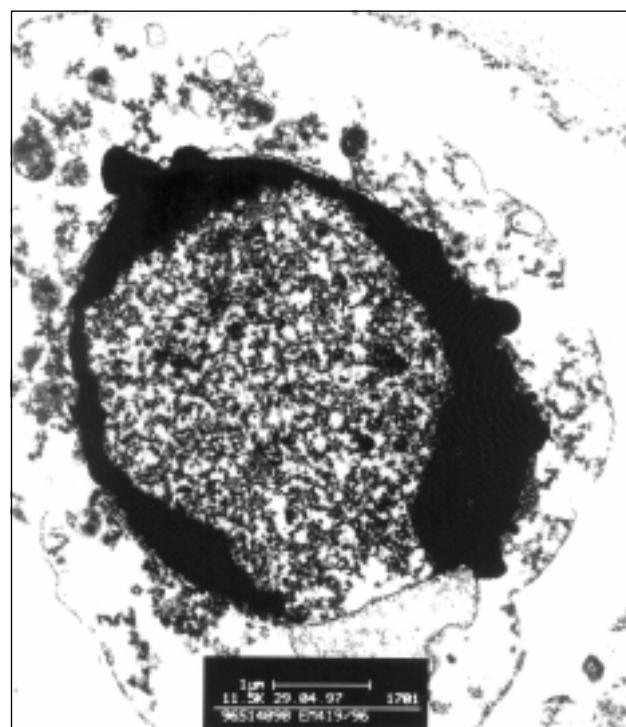


Fig 2. Electron micrograph of foetal lung tissue showing a typical virus inclusion-bearing cell

Note the margination of chromatin and lattice-like virion particles that occupy most of the intranuclear space (x11500)

rhesis groups between the mother and foetus. The incidence of rhesus group incompatibility is low among the local Chinese population, and the prevention of maternal isoimmunisation has led to non-immune hydrops foetalis becoming the more common type of disease. The aetiology of non-immune hydrops foetalis includes chromosomal defects such as Turner's syndrome or trisomy 21, cardiac dysrhythmia or structural abnormalities, and infectious agents. In half of all cases of non-immune hydrops foetalis, the cause is unknown.⁶ Haemoglobin Bart's disease is a common cause of hydrops foetalis in Hong Kong. In the present case, the negative results of the test for maternal α -thalassaemia carrier state (ie normal mean red cell volume) excluded this differential diagnosis. The association with parvovirus B19 infection in this case was confirmed serologically by the presence of parvovirus B19-specific IgM antibodies in the maternal serum. Although false positive results due to cross-reactions with IgM against rubella virus or with rheumatoid factor have been reported,⁷ these possibilities had been excluded in this case. Parvovirus infection was confirmed histologically by the pathognomonic findings, which showed intranuclear viral inclusions in foetal cells of haematopoietic cell lineage.

The diagnosis of maternal parvovirus B19 infection is becoming more important, because intervention by using intrauterine transfusion can improve the outcome of hydrops foetalis in some cases.⁸ To confirm a recent maternal parvovirus infection may not be as straightforward as in this case. The interval between maternal infection and the occurrence of foetal hydrops is often 4 to 5 weeks but may be as long as 11 weeks. Thus, IgM antibodies may not be detectable in the maternal blood when hydrops foetalis is diagnosed. Theoretically, diagnosis can be confirmed by testing the maternal serum at the time of admission to antenatal care, in parallel with the recent sample to demonstrate an IgG seroconversion. Most laboratories in Hong Kong, however, do not keep antenatal blood samples long enough for this purpose. Direct detection of viral particles or genomes in maternal blood is of little help, since viraemia seldom persists for more than 2 weeks in immunocompetent individuals.⁹ When the diagnosis is in doubt, direct detection of viral particles or genomes in amniotic fluid and/or foetal blood may be necessary. In Hong Kong, parvovirus B19 serological assays are currently available only in a few major laboratories, and molecular detection of the viral genome is not yet a routine service. These factors, and the proportion (around one third) of asymptomatic infections, mean that underdiagnosis is expected.

The distribution of parvovirus B19 is worldwide. By the age of 15 years, approximately 50% of children have detectable IgG to the virus. Infection continues to occur in adults and reaches a seroprevalence of 90% in the elderly.¹⁰ The epidemiology of parvovirus infection in Hong Kong has not been fully studied. A parvovirus serological diagnostic service has been available at the Department of Microbiology at the Prince of Wales Hospital since September 1995. Up to December 1996, 120 serum samples had been tested for anti-parvovirus antibodies, based on clinical suspicion; only two samples (including the one from this patient; the other was from a 64-year-old female presenting with pure red cell aplasia) were positive for anti-parvovirus IgM antibodies. Parvovirus serological assays are also available at the Government Virus Unit and at the Department of Microbiology at the Queen Mary Hospital. So far, no laboratory-confirmed cases of parvovirus-associated hydrops foetalis have been documented (Lo JY and Peiris JS, personal communications). Based on these limited data, one cannot conclude on the incidence of parvovirus-associated hydrops foetalis in Hong Kong. Further studies to elucidate the local epidemiology and the impact of parvovirus infection are needed.

References

1. Cossart YE, Field AM, Cant B, Widdows D. Parvovirus-like particles in human sera. *Lancet* 1975;1:72-3.
2. Heegaard ED, Hornsleth A. Parvovirus: the expanding spectrum of disease. *Acta Paediatr* 1995;84:109-17.
3. Public Health Laboratory Service Working Party on Fifth Disease. Prospective study of human parvovirus (B19) infection in pregnancy. *BMJ* 1990;300:1166-70.
4. Jordan JA. Identification of human parvovirus B19 infection in idiopathic nonimmune hydrops foetalis. *Am J Obstet Gynecol* 1996;174:37-42.
5. Yaegashi N, Okamura K, Yajima A, Murai C, Sugamura K. The frequency of human parvovirus B19 infection in non-immune hydrops foetalis. *J Perinat Med* 1994;22:159-63.
6. Keeling JW. Hydrops foetalis and other forms of excess fluid collection in the fetus. In: Wigglesworth JS, Singer DB, editors. *Textbook of fetal and perinatal pathology*. Boston: Blackwell Scientific Publications, 1991:429-54.
7. Patou G, Ayliffe U. Evaluation of commercial enzyme linked immunosorbent assay for detection of B19 parvovirus IgM and IgG. *J Clin Pathol* 1991;44:831-4.
8. Fairley CK, Smoleniec JS, Caul OE, Miller E. Observational study of effect of intrauterine transfusions on outcome of fetal hydrops after parvovirus B19 infection. *Lancet* 1995;346:1335-7.
9. Anderson MJ, Higgins PG, Davis LR, et al. Experimental parvoviral infection in humans. *J Infect Dis* 1985;152:257-65.
10. Cohen BJ, Buckley MM. The prevalence of antibody to human parvovirus B19 in England and Wales. *J Med Microbiol* 1988;25:151-3.