

A case of colonic tuberculosis mimicking Crohn's disease

CF Lau, AMC Wong, KS Yee, CK Loo, PK Hui, KM Lam

A 26-year-old Thai woman who has lived in Hong Kong for the past 3 years presented with a 2-month history of feverishness, intermittent epigastric discomfort, anorexia, and weight loss. She had had per rectal bleeding for 10 days. Colonoscopy on two separate occasions revealed multiple ulcerations involving the entire colon, with rectal sparing. Histological examination of the two sets of colonic biopsies that were obtained during colonoscopy suggested Crohn's disease. There was no response to mesalazine and metronidazole, but the patient responded promptly to a therapeutic trial of antituberculous drugs. Cultures from the first set of colonic biopsies were negative for acid-fast bacilli, but 8 weeks after the second colonoscopy, cultures from the second set of biopsies yielded *Mycobacterium tuberculosis*. This case illustrates that the diagnosis of colonic tuberculosis requires a high index of suspicion. In cases where the information available does not reveal a definite differentiation between colonic tuberculosis and Crohn's disease, corticosteroids should be withheld. The administration of corticosteroids to a patient with colonic tuberculosis may have disastrous results, and a therapeutic trial of antituberculous drugs should be considered instead.

HKMJ 1998;4:63-6

Key words: Crohn disease; Diagnosis, differential; *Mycobacterium tuberculosis*; Tuberculosis, gastrointestinal

Introduction

Intestinal tuberculosis is much more difficult to diagnose than pulmonary tuberculosis. One of the reasons is the very low diagnostic yield of endoscopic biopsy specimens. For example, in a series of 50 patients with colonic tuberculosis that was collected over a 10-year period, specific diagnostic features such as the presence of caseation on histological study, positive staining for acid-fast bacilli, or a positive culture for *Mycobacterium tuberculosis* were seen in only 18% of patients.¹ We report below a case of diffuse colonic tuberculosis closely mimicking Crohn's colitis. The differentiation between the two conditions and their management are discussed.

Case report

A 26-year-old Thai woman with previously good health

presented to the Department of Medicine at the Kwong Wah Hospital on 2 March 1996. She gave a 2-month history of feverishness, intermittent epigastric discomfort, anorexia, and weight loss. She also complained of per rectal bleeding in the form of blood mixed with stool during the 10 days prior to admission, but she had not had diarrhoea. The patient had come to Hong Kong 3 years previously and had married a local resident. She was a housewife and had not travelled outside Hong Kong during the past 3 years. She had had a bilateral breast implantation for cosmetic reasons in Thailand before coming to Hong Kong; there had been no pain in her breasts since the operation. She did not have a family history of inflammatory bowel disease.

On physical examination, her body build was normal. She had a maximum temperature of 39.5°C and was pale but not jaundiced. Her liver was palpable 3 cm below the costal margin; it was soft and the surface was smooth. No other abdominal mass was palpable; the lymph nodes were also not palpable. There was no local tenderness over her breast region.

Initial blood tests revealed hypochromic, microcytic anaemia. The haemoglobin level was 71 g/L (normal range, female, 115-155 g/L). The white cell count was raised, at 14.5×10^9 /L (normal range, 3.5 - 9.8×10^9 /L), with 80.4% neutrophils (normal range, 40.0%-

Kwong Wah Hospital, 25 Waterloo Road, Kowloon, Hong Kong:

Department of Medicine

CF Lau, MB, BS, FHKAM (Medicine)

AMC Wong, MB, ChB, MRCP

KS Yee, MB, ChB, MRCP

CK Loo, MB, BS, FHKAM (Medicine)

KM Lam, MB, BS, FHKAM (Medicine)

Department of Pathology

PK Hui, MB, BS, FHKAM (Pathology)

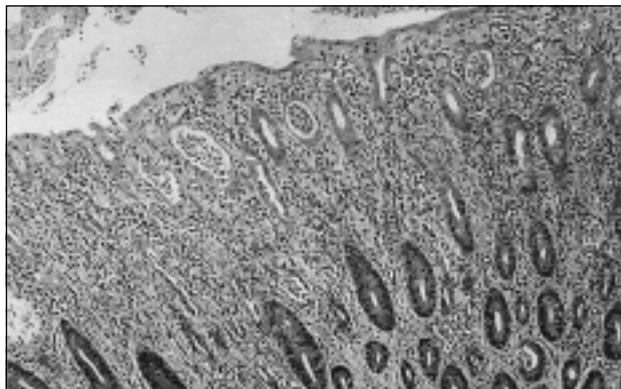
Correspondence to: Dr CF Lau

74.0%) and 11.3% lymphocytes (normal range, 19.0%-48.0%). The platelet count was $637 \times 10^9/L$ (normal range, $130-400 \times 10^9/L$), and the erythrocyte sedimentation rate was raised, at 107 mm/hr (normal, 26-year-old woman, <23 mm/hr). Liver function tests revealed a lowered serum albumin level of 23 g/L (normal range, 40-60 g/L), raised globulin level of 43 g/L (normal range, 20-35 g/L), slightly raised bilirubin of $22 \mu\text{mol/L}$ (normal range, $2-18 \mu\text{mol/L}$), and raised alkaline phosphatase level of 149 U/L (normal range, 30-120 U/L). Her serum glutamic-oxaloacetic transaminase, serum glutamate pyruvate transaminase, and renal function tests were normal. The chest X-ray was normal except for the shadows from the breast implants. Serum iron was reduced to $3 \mu\text{mol/L}$ (normal range, female, $11-29 \mu\text{mol/L}$); total iron binding capacity was $37 \mu\text{mol/L}$ (normal range, $40-72 \mu\text{mol/L}$); and serum ferritin was $48 \mu\text{g/L}$ (normal range, premenopausal, $18-300 \mu\text{g/L}$). Haemoglobin pattern analysis revealed an α -thalassaemic trait. Blood culture, stool culture, and fresh stool were negative for amoebae. The test for anti-amoeba antibody was also negative.

Colonoscopy revealed multiple ulcerations involving the caecum, ascending colon, transverse colon, descending colon, and sigmoid colon. The intervening mucosa appeared normal and the rectum was spared. Histological examination of colonic biopsies revealed an increased frequency of plasma cells, cryptitis, crypt abscesses, and submucosal epithelioid granulomas with occasional giant cells, but caseation was absent (Figs 1a and 1b). The crypts showed an irregular reduction in the frequency of goblet cells, and some glands had an irregular outline. No acid-fast bacilli were detected. The histological diagnosis was benign ulceration and chronic colitis, which were consistent with active inflammatory bowel disease, particularly Crohn's disease. Upper gastrointestinal endoscopy revealed no abnormalities. Small bowel enema revealed slightly thickened mucosal folds in the terminal ileum.

An ultrasound scan of the abdomen revealed an enlarged liver that had normal echogenicity and no dilated ducts. A liver biopsy was performed because of persistent fever and impaired liver function. It revealed mild inflammatory infiltration of the portal tract by plasma cells, histiocytes, and polymorphs. A few small foci of spotty necrosis and a collection of intrasinusoidal polymorphs were also observed. Granuloma was not detected. The histological features were non-specific and were suggestive of sepsis rather than primary liver disease. Bone marrow aspiration and biopsy showed normal cell morphology and iron stores.

1a.



1b.

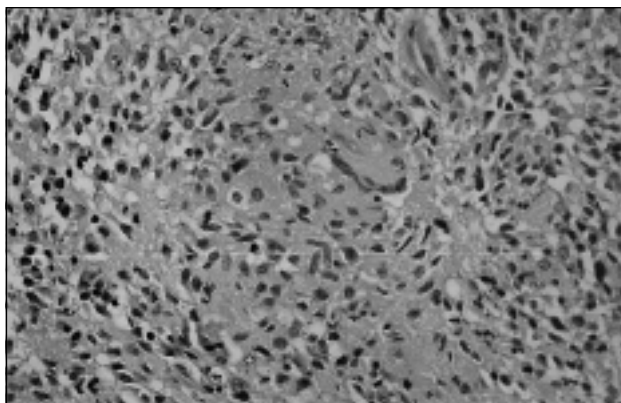


Fig 1. Photomicrographs of colonic biopsies Photomicrographs showing (1a) cryptitis and crypt abscess (H&E, x125) and (1b) epithelioid granuloma (H&E, x200)

The patient was given a course of mesalazine 3 g/day; metronidazole 400 mg, three times a day, was given 1 week later. These two medications were continued for 4 weeks but the fever persisted. Colonoscopy was repeated and gave findings similar to the initial examination. Biopsies were also repeated; the histological examination of this second set of colonic biopsies revealed pathological findings similar to the first set. At the time of both colonoscopies, biopsies were also tested for the presence of acid-fast bacilli by culture. After the second colonoscopy, administration of mesalazine and metronidazole was stopped and the patient was given the following drug therapy: isoniazid 300 mg/day, rifampicin 450 mg/day, pyrazinamide 1.5 g/day, and ethambutol 600 mg/day. Four days later, the patient's fever began to subside and a further 3 days later, she became completely afebrile. The first colonic biopsies that were cultured for acid-fast bacilli gave negative results. Eight weeks after the second colonoscopy, cultures from the second colonic biopsies yielded *M. tuberculosis*. Three months after the commencement of antituberculous drugs, a follow-up colonoscopy revealed the complete healing of all colonic ulcers.

Discussion

The differentiation between intestinal tuberculosis and Crohn's disease based on clinical features, radiology, endoscopy, and histology is often difficult, as illustrated by this case report. Although the colonic biopsies performed on two occasions suggested Crohn's disease, the absence of diarrhoea throughout the patient's illness was not typical of Crohn's disease: diarrhoea is usually present in patients with active Crohn's disease.² This patient's chest X-ray showed no evidence of pulmonary tuberculosis. This is not surprising, since less than half of patients with abdominal tuberculosis have associated pulmonary disease³; and in one study, the proportion was 19%.^{3,4}

Tuberculosis may affect any part of the gastrointestinal tract, but it most commonly involves the terminal ileum and ileocaecal region, as does Crohn's disease.⁵ In an analysis of six series of patients with abdominal tuberculosis, colonic tuberculosis accounted for 12.1% of all cases of gastrointestinal tuberculosis, and 6% of all cases of abdominal tuberculosis (peritoneal, gastrointestinal, and mesenteric).⁴

The colonoscopic features of colonic tuberculosis include erythema, mucosal nodules, ulcers, strictures, and a deformed ileocaecal valve.^{1,6,7} These features are non-specific, however, and can also occur in Crohn's disease. In contrast, distinguishing histological features of granulomas in intestinal tuberculosis and Crohn's disease have been described.⁵ Caseation, if present, strongly suggests tuberculosis, but central acute necrosis of granulomas may also be seen occasionally in Crohn's disease. Further, hyalinisation of granulomas is a typical feature of tuberculosis but is uncommon in Crohn's disease.⁵ One must bear in mind, however, that sampling error on biopsy may lead to the failure of detecting granulomas in biopsy specimens from patients with either condition. In addition, granulomas in colonic tuberculosis may not always show caseation, despite repeated, multiple colonoscopic biopsies, as in our case.

Various methods have been described to facilitate the diagnosis of intestinal tuberculosis before resorting to laparotomy. These include: the sonographic detection of a thickening of the bowel wall in the ileum, caecum, and/or ascending colon, especially in association with ascites; an increased mesenteric thickness; an increased mesenteric echogenicity; and mesenteric lymphadenopathy.^{8,9} The transrectal instillation of water can improve the sonological imaging of the lumen and wall of the colon—a technique termed

colonic sonography—and this can increase the sensitivity of the detection of colonic tuberculosis to 91%.¹⁰ The various sonographic findings described above are, however, not specific for intestinal tuberculosis and clinical correlation is necessary.

At colonoscopy, the use of endoscopic fine needle aspiration cytology has been reported to facilitate the diagnosis of ileocaecal tuberculosis.¹¹ *Mycobacterium tuberculosis* DNA from endoscopic biopsy specimens can be assayed by the polymerase chain reaction; this technique has been reported to aid the diagnosis of intestinal tuberculosis and to allow the exclusion of Crohn's disease with a specificity of 100% and a sensitivity of 26.5% to 75.0%.¹²⁻¹⁴ Enzyme-linked immunosorbent assay to detect antibodies against saline-extracted mycobacterial antigen has been shown to have a sensitivity of 81% and a specificity of 88% for the serological diagnosis of abdominal tuberculosis, and thus may also be useful for differentiating intestinal tuberculosis from Crohn's disease.¹⁵ The detection of anti-cord factor antibodies has recently been shown to facilitate the diagnosis of intestinal tuberculosis, and to differentiate it from Crohn's disease and ulcerative colitis, with a sensitivity of 85% and a specificity of 95%.¹⁶ Unfortunately, many of the subsidiary tests mentioned above, however desirable, are not widely available. The differentiation between intestinal tuberculosis and Crohn's disease still often depends on histology, bacterial culture, and even a therapeutic trial of antituberculous medication.

This case report illustrates that the diagnosis of colonic tuberculosis requires a high index of suspicion. In cases where there is any doubt about the diagnosis of Crohn's disease, and even if the histology of the colonic biopsies suggests Crohn's disease, corticosteroids should be withheld. This is because administering corticosteroids to patients with colonic tuberculosis may have disastrous results such as causing disseminated tuberculosis.¹⁷ On the other hand, if the information available cannot allow a definite differentiation between colonic tuberculosis and Crohn's disease, a therapeutic trial of antituberculous drugs is justifiable because these would not aggravate Crohn's disease. In fact, antimycobacterial drug therapy has been reported to be beneficial in some Crohn's disease patients.¹⁸ If the clinical picture is compatible with colonic tuberculosis and there is a good response to antituberculous drug therapy, a full course of antituberculous drugs should be given. This should be done even if the bacterial culture from an endoscopic biopsy turns out to be negative for *M. tuberculosis*, since only a minority of patients with

intestinal tuberculosis show the presence of this bacterium on culture.^{1,12}

References

1. Shah S, Thomas V, Mathan M, et al. Colonoscopic study of 50 patients with colonic tuberculosis. *Gut* 1992;33:347-51.
2. Farmer RG, Hawk WA, Turnbull RB Jr. Clinical patterns in Crohn's disease: a statistical study of 615 cases. *Gastroenterology* 1975;68:627-35.
3. Dawson A. The Respiratory System. In: Haubrich WS, Schaffner F, Berk JE, editors. *Bockus Gastroenterology*. 5th edn. Philadelphia: WB Saunders, 1995;3404-19.
4. Marshall JB. Tuberculosis of the gastrointestinal tract and peritoneum. *Am J Gastroenterol* 1993;88:989-99.
5. Hamilton RS, Morson BC. Crohn's Disease Part 1 (Pathology). In: Haubrich WS, Schaffner F, Berk JE, editors. *Bockus Gastroenterology*. 5th edn. Philadelphia: WB Saunders, 1995;1398-1409.
6. Pettengell KE, Pirie D, Simjee AE. Colonoscopic features of early intestinal tuberculosis. Report of 11 cases. *S Afr Med J* 1991;79:279-80.
7. Bhargava DK, Kushwaha AK, Dasarathy S, Shrinivas, Chopra P. Endoscopic diagnosis of segmental colonic tuberculosis. *Gastrointest Endosc* 1992;38:571-4.
8. Lee DH, Ko YT, Yoon Y, Lim JH. Sonographic findings of intestinal tuberculosis. *J Ultrasound Med* 1993;12:537-40.
9. Jain R, Sawhney S, Bhargava D, Berry M. Diagnosis of abdominal tuberculosis: sonographic findings in patients with early disease. *AJR Am J Roentgenol* 1995;165:1391-5.
10. Walter DF, Govil S, William RR, Bhargava N, Chandy G. Colonic sonography: preliminary observations. *Clin Radiol* 1993;47:200-4.
11. Kochhar R, Rajwanshi A, Goenka MK, et al. Colonoscopic fine needle aspiration cytology in the diagnosis of ileocecal tuberculosis. *Am J Gastroenterol* 1991;86:102-4.
12. Manjunath N, Shankar P, Rajan L, Bhargava A, Saluja S, Shrinivas. Evaluation of a polymerase chain reaction for the diagnosis of tuberculosis. *Tubercle* 1991;72:21-7.
13. Anand BS, Schneider FE, El-Zaatari FA, Shawar RM, Clarridge JE, Graham DY. Diagnosis of intestinal tuberculosis by polymerase chain reaction on endoscopic biopsy specimens. *Am J Gastroenterol* 1994;89:2248-9.
14. Gan H, Ouyang Q, Bu-H, et al. Value of polymerase chain reaction assay in diagnosis of intestinal tuberculosis and differentiation from Crohn's disease. *Chin Med J (Engl)* 1995;108:215-20.
15. Bhargava DK, Dasarathy S, Shrinivas MD, Kushwaha AK, Duphare H, Kapur BM. Evaluation of enzyme-linked immunosorbent assay using mycobacterial saline-extracted antigen for the serodiagnosis of abdominal tuberculosis. *Am J Gastroenterol* 1992;87:105-8.
16. Kashima K, Oka S, Tabata A, et al. Detection of anti-cord factor antibodies in intestinal tuberculosis for its differential diagnosis from Crohn's disease and ulcerative colitis. *Dig Dis Sci* 1995;40:2630-4.
17. Diaz Oller J, Cano Munoz R, Fuentes Vaamonde ME, et al. Synchronous intestinal, tonsillar and pulmonary tuberculosis. *Rev Esp Enferm Dig* 1995;87:673-6.
18. Prantera C, Kohn A, Mangiarotti R, Andreoli A, Luzi C. Antimycobacterial therapy in Crohn's disease: results of a controlled, double-blind trial with a multiple antibiotic regimen. *Am J Gastroenterol* 1994;89:513-8.