

Creutzfeldt-Jakob disease in Hong Kong

KKP Ng, PCK Li, CK Wong, JHM Chan, JHM Yeung, KT Loo

Two elderly patients presented with rapidly progressive dementia and their electroencephalograms showed periodic discharges. Creutzfeldt-Jakob disease was pathologically confirmed in one of the patients. Striking clinical features and characteristic electroencephalograms should prompt the clinical diagnosis in most patients.

HKMJ 1997;3:439-43

Key words: Creutzfeldt-Jakob syndrome; Dementia; Electroencephalography; Encephalopathy, bovine spongiform; Prion diseases

Introduction

Creutzfeldt-Jakob disease (CJD) is one of the human spongiform encephalopathies which also include kuru, Gerstmann-Straussler-Scheinker disease and fatal familial insomnia. Patients with CJD typically present with rapidly progressive and eventually profound dementia, cerebellar ataxia, and diffuse myoclonic jerks in patients over the age of 50 years. Prodromal symptoms such as fatigue, depression, weight loss, and disturbances of sleep and appetite may also be present.

The annual incidence of sporadic CJD has been estimated to be about 0.3 to 1.0 case per one million people,^{1,2} and the condition is probably underdiagnosed in Hong Kong. Recently, there has been much interest in the condition; more than 10 cases of variant CJD in patients under the age of 42 years have been reported in England and a link to the bovine spongiform encephalopathy (BSE) epidemic has been postulated.^{3,4} It is important to increase the awareness of and knowledge about CJD among local clinicians, and to study its epidemiology so as to detect any changes in the pattern of the disease in Hong Kong. We report two patients diagnosed with CJD at the Queen Elizabeth Hospital (QEH) within the past 3 years.

**Queen Elizabeth Hospital, Kowloon, Hong Kong:
Department of Medicine**

KKP Ng, MB, BS, FHKAM (Medicine)

PCK Li, MB, BS, FHKAM (Medicine)

CK Wong, MB, BS, FHKAM (Medicine)

JHM Chan, MB, BS, FHKAM (Medicine)

JHM Yeung, MB, BS, FHKAM (Medicine)

Department of Pathology

KT Loo, MB, BS, FHKAM (Pathology)

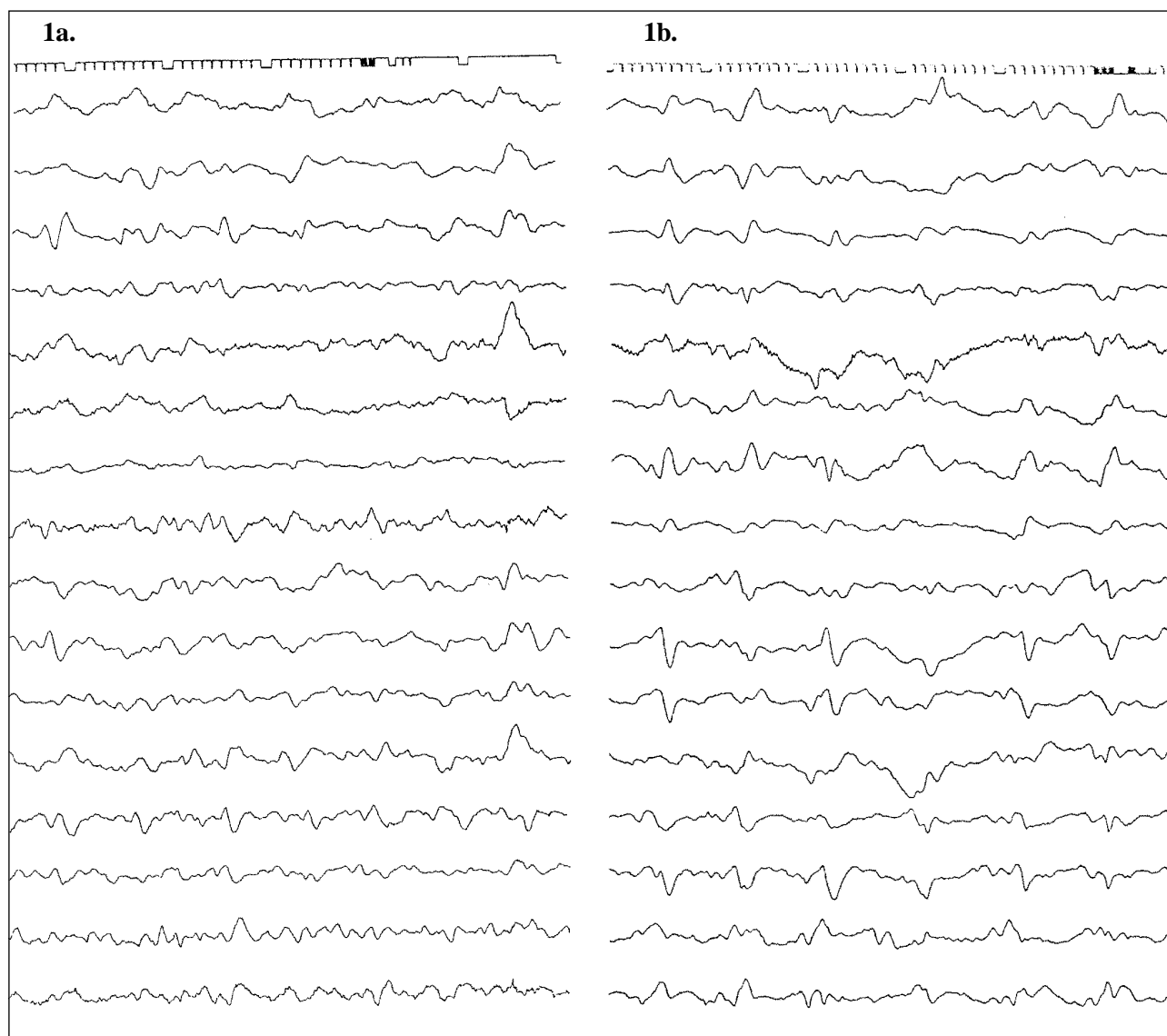
Correspondence to: Dr KKP Ng

Case 1

A 66-year-old Chinese man presented to the QEH in late October 1993 for progressive deterioration of mental state and generalised weakness. He was born in the Guangdong province of China and came to Hong Kong at the age of 10 years. From then on, he had infrequently travelled to mainland China. He had worked as a janitor and retired at the age of 60 years. He had no special dietary preferences. Apart from an elevated blood pressure, for which he did not seek medical advice, he had no other medical illnesses. He was the only child of his family and was married with four children. There was no family history of any neurological diseases.

During the two months prior to presentation to the QEH, the patient had recurrent dizziness and lower limb weakness which were attributed to influenza for which he had consulted a private general practitioner for treatment. He was assessed by a private geriatrician in early October because of deteriorating symptoms, and magnetic resonance imaging (MRI) of the brain showed findings suggestive of ischaemic changes in the bilateral frontal areas. A diagnosis of multi-infarct dementia was made, but his condition continued to deteriorate despite a course of physiotherapy. He became forgetful and was unable to cope with his daily activities. He was subsequently transferred to the QEH for further treatment.

A neurological examination given on admission showed an apathetic patient who was disoriented in time, place and person, and who had little spontaneous speech. Apart from the presence of brisk symmetrical reflexes, there was no focal neurological deficit and the Babinski sign was negative. Routine investigations



Figs 1a and 1b. Case 1 — EEG shows widespread theta and delta waves, signifying a moderate to severe degree of widespread cerebral dysfunction in the first week (Fig 1a); low amplitude, generalised, periodic sharp waves of 1.0 to 1.5 cps in the third week (Fig 1b)

gave normal findings. These included blood counts; liver and renal function tests; determination of erythrocyte sedimentation rate; assays for thyroid hormone, spot cortisol, complement 3, complement-reactive protein, serum and red cell folate, and vitamin B12; and examination of cerebrospinal fluid. The VDRL test, and tests for anti-nuclear factor and rheumatoid factor were negative. An initial electroencephalogram (EEG) showed a moderate to severe degree of widespread cerebral dysfunction during the first week of hospitalisation (Fig 1a). Generalised, periodic sharp waves of 1.0 to 1.5 cycles per second (cps) appeared in the EEGs during the third and fourth weeks (Fig 1b). Myoclonus of the limbs and a startle response were evident soon after admission. The patient continued to deteriorate and became mute, severely demented, and bedridden. He developed repeated

episodes of urinary tract infection and hypostatic pneumonia, and finally succumbed 2 months after admission. A postmortem examination was not performed.

Case 2

A 69-year-old Chinese woman presented to the QEH in late January 1996 because of progressive deterioration in her walking gait. She was born in the southern part of the Guangdong province of China and came to Hong Kong 40 years ago. She had a history of subsequently visiting Europe and mainland China. She previously worked as a housemaid and was married. She had no special dietary preferences, enjoyed good health, and did not have a family history of any neurological diseases.

During the month prior to hospitalisation, she had noticed a progressive unsteadiness. A physical examination showed an alert patient who had mild dysarthria and bilateral cerebellar signs in the upper limbs. Muscle tone and power were normal, as were tendon reflexes. A plain computed tomography (CT) scan of the brain showed ill-defined hypodense areas in both cerebellar hemispheres and a mild degree of generalised cerebral atrophy. She was transferred to the Kowloon Hospital for rehabilitation, pending MRI of the brain to delineate the pathology in the cerebellum.

During the next month, there was a progressive deterioration in her neurological condition. She had decreased speech and mobility, and became mute and unable to recognise her relatives. The muscle tone over the right side of her body increased; and a startle response and myoclonus were obvious. Blood inves-

tigations were normal. A cerebrospinal fluid examination showed a raised protein level of 0.87 g/L but was otherwise normal. Serial EEGs showed generalised, periodic sharp waves of 1.0 to 1.5 cps (Fig 2). Her condition stabilised and she was discharged to a home for the elderly in mid-April 1996. She was readmitted to the QEH in May because of a chest infection, a further deterioration in her neurological condition, and frequent myoclonic jerks. Her general condition steadily deteriorated and she finally died in July 1996.

A pathological examination of the brain revealed diffuse cortical atrophy of the cerebral hemispheres and cerebellum. On microscopic examination, a prominent spongiform change was found throughout the cerebral cortex which involved the entire cortical thickness in many areas (Fig 3). Neuronal depletion

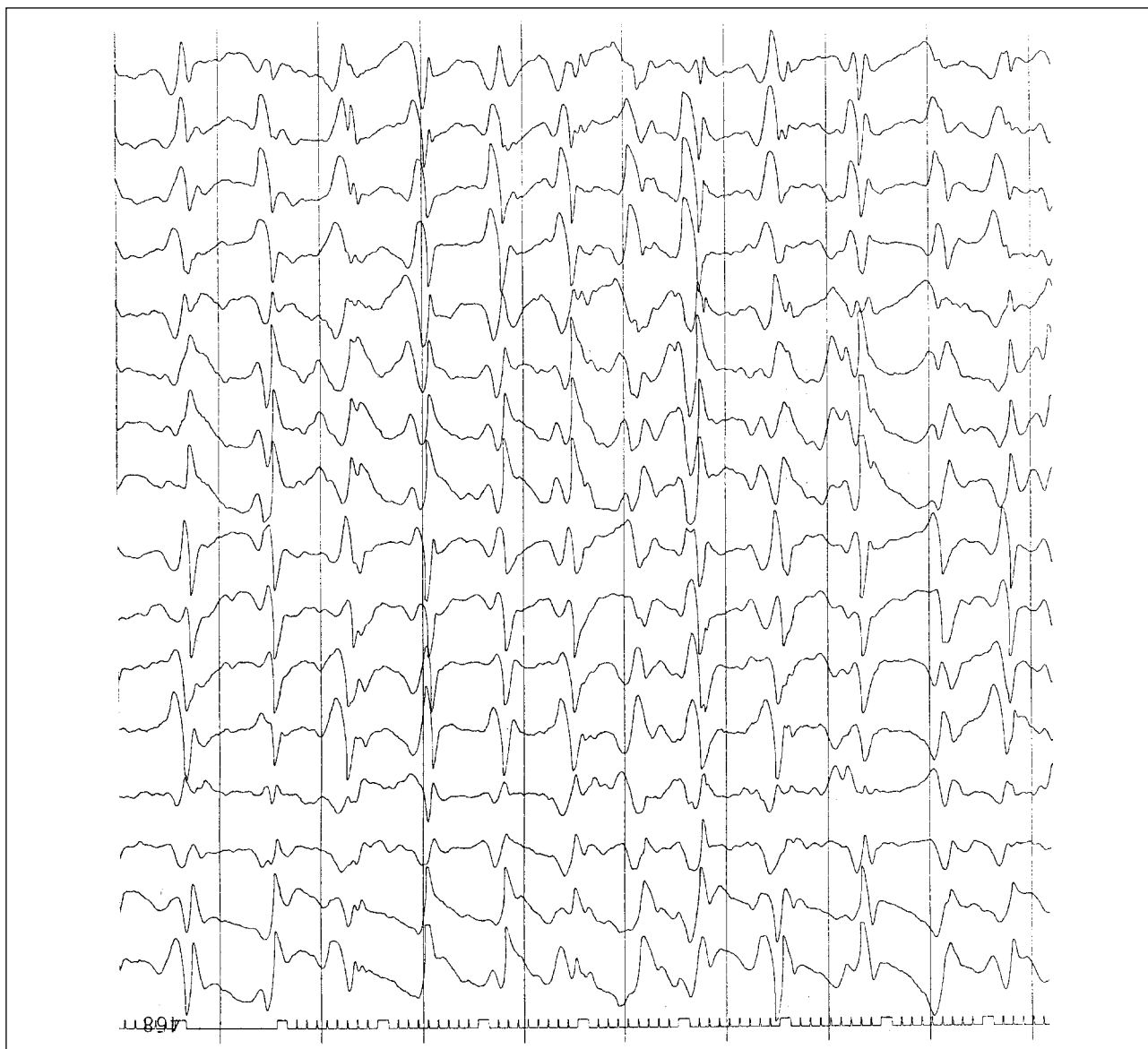


Fig 2. Case 2 — EEG showing high amplitude, generalised, periodic sharp waves of 1.0 to 1.5 cps

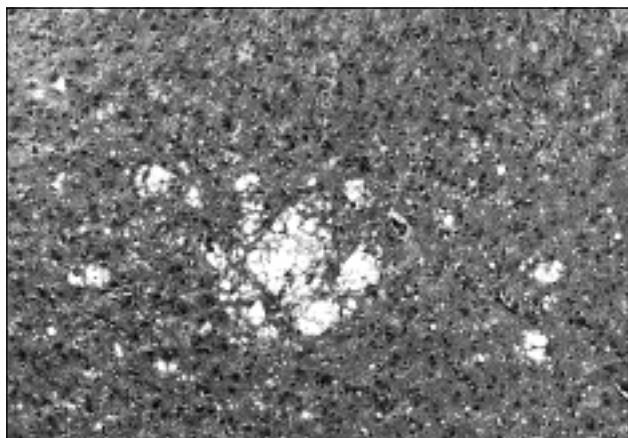


Fig 3. Photomicrograph of a section from the cerebral cortex. Note the spongiform change, neuronal loss and increase in the number of reactive cells (H&E, x 30)

and astrocytosis were also evident, but amyloid plaques were not detected. Similar abnormalities were seen in the cerebellar cortex, both in nature and in severity. The basal ganglia and the brain stem were, however, unaffected.

Discussion

The diagnosis of CJD is based on its striking clinical features and characteristic EEG changes, and can be confirmed by neuropathological findings. Although a pathological examination was not performed on the first patient, the typical clinical presentation and EEG changes were sufficient for a confident diagnosis. The EEG changes in CJD are distinctive and consist of diffuse, periodic, high-voltage, biphasic or triphasic, sharp, slow wave complexes of 1 to 2 cps over a slow background. As the disease progresses, the periodic discharges may decrease in amplitude and background activity.⁵ Although not pathognomonic of CJD, this distinctive EEG pattern, in the context of compatible clinical features, can establish the diagnosis without requiring pathological confirmation.⁶⁻⁹

An examination of the cerebrospinal fluid in CJD patients gives invariably normal results although a raised protein level may be seen in a small number of patients. Other laboratory investigations including blood tests are generally not helpful. Structural neuroimaging often shows a varying degree of cerebral atrophy and MRI may show an increased signal in the basal ganglia on T-2 weighted images.¹⁰ A macroscopic pathological examination may indicate a normal or atrophic brain. Microscopic changes, however, usually involve extensive portions of the cerebral cortex, although the severity varies in different regions of the

brain; the deep grey matter is variably involved and the putamen is the most susceptible region. The brain stem is usually spared. The degeneration and demyelination of the lateral corticospinal tract are seen in the spinal cord in some cases. Spongiform changes are striking and more severe than those which occur in degenerative disorders; they are accompanied by pronounced neuronal loss and reactive astrocytosis. The white matter may also demonstrate myelin loss, spongiform changes and reactive astrocytosis. In 5% of cases, amyloid plaques are observed in the cortex. Histological confirmation consists of immunocytochemical studies using prion protein-specific antibodies; positive reactivity may be demonstrated in the spongiform neuropil and neurones, and when present, in the amyloid plaques. Recent techniques for detecting abnormal prion protein (PrP), or a mutant PrP genotype in the DNA extracted from peripheral tissue have made it possible to confirm the diagnosis in even the asymptomatic patient.¹¹

CJD has been reported in patients who have used growth hormone or gonadotropin that has been derived from the human pituitary gland, in recipients of dura mater or corneal grafts, and in neurosurgical patients who have undergone an implantation of depth EEG electrodes. The most likely cause in such patients is an exposure to contaminated material that has been derived from or been exposed to a patient with CJD. It can be familial in 5% to 15% of cases and some patients have an apparently dominant pattern of inheritance. The incidence has been found to be unusually high among Israelis born in Libya or in the Orave region of Slovakia. The majority (>85%) of CJD cases are, however, sporadic.¹¹

In all spongiform encephalopathies, there is an accumulation of modified PrP in the brain. Normal PrP is encoded by a gene on the short arm of chromosome 20, and a prion is believed to be involved in its post-translational modification and subsequent accumulation which will result in progressive neurodegeneration. In familial spongiform encephalopathies, the mutation of the PrP gene at different codon positions is the underlying pathogenetic mechanism.¹¹ A species barrier exists but prion modification may allow the passage of PrP between species: this is the current postulated link between BSE and variant CJD.⁴ No specific treatment is available for CJD and the disease is invariably fatal. Although the inherited form can be prevented by genetic counselling, coupled with prenatal DNA screening, such testing is not without ethical considerations. Gene therapy may ultimately provide an effective treatment.

The true incidence of CJD in Hong Kong is unknown. The only case report was described by Chan et al in 1987.¹² Personal communication with other neurologists in Hong Kong have revealed that at least five other sporadic cases have been diagnosed in other hospitals within the territory during past few years. The reported annual worldwide incidence is 0.3 to 1.0 per million,^{1,2} so the disease is likely to have been underdiagnosed in the territory. Clinicians should be more alert about the possibility of CJD as a diagnosis and any patient with rapidly progressive dementia should have an EEG examination performed to look for the changes in the EEG which are characteristic of CJD. A neuropathological examination should be arranged for patients who are suspected to have CJD but who give atypical EEGs. Finally a surveillance system should be set up in Hong Kong to examine the local incidence, pattern and clinical characteristics of the disease. In the light of the recent reports of patients developing a form of variant CJD in England, and its possible link with the BSE epidemic,^{3,4} baseline epidemiological information will be vital to detect any similar outbreaks in Hong Kong.

Addendum

After writing this report, two still living elderly patients (one male and one female) were diagnosed to have CJD in March 1997 at the QEH; they had compatible clinical features and characteristic EEGs.

Acknowledgement

The authors gratefully acknowledge the technical assistance and advice given by the Department of

Anatomical and Cellular Pathology, Prince of Wales Hospital.

References

1. Will RG, Matthews WB, Smith PG, Hudson C. A retrospective study of Creutzfeldt-Jakob disease in England and Wales 1970-1979 II: epidemiology. *J Neurol Neurosurg Psychiatry* 1986; 49:749-55.
2. Brown P, Cathala F, Gajdusek DC. Creutzfeldt-Jakob disease in France III: epidemiological study of 110 patients dying in the decade 1968-1977. *Ann Neurol* 1979;6:438-46.
3. Gore SM. Bovine Creutzfeldt-Jakob disease? *BMJ* 1996;312: 791-2.
4. Brown P. Bovine spongiform encephalopathy and Creutzfeldt-Jakob disease. *BMJ* 1996;312:790-1.
5. Niedermeyer E, Da Silva FL. *Electroencephalography: basic principles, clinical applications and related fields*. 3rd ed. Baltimore: Williams and Wilkins; 1993:296-7.
6. Levy SR, Chiappa KH, Burke CJ, Young RR. Early evolution and incidence of electroencephalographic abnormalities in Creutzfeldt-Jakob disease. *J Clin Neurophysiol* 1986;3:1-21.
7. Brown P, Cathala F, Castaigne P, Gajdusek DC. Creutzfeldt-Jakob disease: clinical analysis of a consecutive series of 230 neuropathologically verified cases. *Ann Neurol* 1986;20: 597-602.
8. Smith SJ, Kocen RS. A Creutzfeldt-Jakob like syndrome due to lithium toxicity. *J Neurol Neurosurg Psychiatry* 1988;51: 120-3.
9. Hormes JT, Benarroch EE, Rodriguez M, Klass DW. Periodic sharp waves in baclofen-induced encephalopathy. *Arch Neurol* 1988;45:814-5.
10. Di Rocco A, Molinari S, Stollman AL, Decken A, Yahr MD. MRI abnormalities in Creutzfeldt-Jakob disease. *Neuroradiology* 1993;35:584-5.
11. Pruisner SB, Hsiao KK. Human prion diseases. *Ann Neurol* 1994;35:385-95.
12. Chan YW, Ho HC, Kay CS, Li SW, Ip YM. Creutzfeldt-Jakob disease in Hong Kong. A case report. *J Neurol Sci* 1987;80: 143-52.