

The natural history of chronic hepatitis B infection

GKK Lau, CL Lai, PC Wu

Chronic hepatitis B infection is a global health problem that affects about 300 million people. Of these, 75% are Chinese. Most Chinese who become chronic carriers, contract the virus during the perinatal period. The natural history of these chronic hepatitis B carriers includes an initial immune tolerance phase, followed by immune clearance and an inactive hepatitis B non-replicative phase with the development of cirrhosis that may be complicated by hepatocellular carcinoma. The classification of hepatocellular carcinoma has recently been revised. Based on immunohistochemical studies, it has been found that patients with hepatocellular carcinoma and biliary markers have a poorer survival than patients with hepatocellular carcinoma but who have negative biliary markers. Sometimes, a fourth phase, a hepatitis B envelope-negative hepatitis B virus replicative phase, reflecting the emergence of a pre-core mutant strain, may follow. Our improved understanding of the natural history of chronic hepatitis B infection has led to more effective approaches towards the control of this viral infection and its sequelae. Most importantly, immunisation against hepatitis B virus in the perinatal setting has been shown to prevent chronic infection.

HKMJ 1997;3:283-8

Key words: Hepatitis B virus; Carcinoma, hepatocellular; Hepatitis, chronic active; Hepatitis, viral, human; Immune tolerance

Introduction

Hepatitis B virus (HBV) infection is one of the most common viral infections in humans. It has been estimated that chronic hepatitis B infection affects approximately 300 million individuals, or 5% of the world's population.¹ This is of particular concern in the Asia-Pacific region, where chronic HBV infection is prevalent, with a carrier rate of approximately 10%. Of the chronic HBV carriers, between 25% to 40% will eventually die from liver disease (cirrhosis with or without hepatocellular carcinoma [HCC]); the death rate being 50% for male carriers and 15% for female carriers.² The natural history of chronic HBV infection in Chinese is characterised by an initial active viral replicative state with minimal liver damage (immune tolerance phase), followed by an active immune clearance phase with chronic active hepatitis and later an inactive HBV non-replicative phase with the development of cirrhosis that may be complicated by

HCC.³ In addition, some patients enter a stage that is characterised by viraemia and chronic active hepatitis in the absence of hepatitis B envelope (HBe) antigenaemia.⁴

Establishment of chronic hepatitis B virus infection

The age at infection is the single most important factor affecting chronic HBV carriage. There is an inverse relationship between the risk of chronicity of HBV infection and age. The risk is 80% to 90% for infections that occur before the age of one year, 20% to 50% for infections in early childhood, and only 1% to 2% for infections in adults.⁵ Unlike Caucasians who acquire HBV infection in adulthood, Chinese usually acquire the infection perinatally.⁶

The high frequency of maternal transmission among Chinese is related to the prevalence of carrier mothers with HBe antigen (HBeAg), a marker of HBV replication and infectivity. The prevalence of HBeAg positivity is estimated to be 40%, 15%, and 10% among Chinese, African, and Caucasian carrier mothers, respectively.⁷⁻⁹ Because of the infectivity of the carrier mothers and the possibly interfering role of HBeAg, which can cross the placenta and induce HBV-specific host tolerance, HBV infection becomes chronic in

Queen Mary Hospital, Pokfulam, Hong Kong:
Division of Gastroenterology and Hepatology
GKK Lau, MB, BS, FHKAM (Medicine)
Department of Medicine
CL Lai, MD, FHKAM (Medicine)
Department of Pathology
PC Wu, MD, FHKAM (Pathology)

Correspondence to: Prof PC Wu

approximately 90% of infants born to HBeAg-positive mothers.¹⁰ The highly infectious maternal blood may infect the newborn through placental leakage during labour, or through the disrupted mucous membrane and skin of the newborn in the birth canal. In approximately 3% of these newborns, HBV infection is believed to occur in utero, and transplacental leakage of the maternal blood may be the most likely route of intrauterine infection. Once the infection becomes chronic, hepatitis B surface antigen (HBsAg) carriage is sustained, with an overall incidence of loss of HBsAg in 0.6% of child carriers per year. This low percentage of HBsAg clearance persists in adult carriers.¹¹ Seroconversion to hepatitis B surface antibody (anti-HBs) occurs even less frequently. In such instances, serum HBV DNA is cleared and is undetectable even by polymerase chain reaction (PCR) assay. However, HBV DNA may still be present in low levels in the liver.

The different phases of hepatitis B virus infection

In Hong Kong Chinese, most chronic HBV carriers acquire the infection during the perinatal period. There are generally three phases in the evolution of chronic HBV infection: (1) the immune tolerance phase; (2) the immune clearance phase; and (3) the residual non-replicative integrated HBV phase. Sometimes, a fourth phase with HBeAg-negative HBV replication, reflecting the emergence of a pre-core mutant strain, may follow (Fig 1).

The immune tolerance phase

The immune tolerance phase is characterised by a lack of clinical symptoms. The livers in these young HBV carriers, however, usually show some abnormalities histologically, albeit mild and non-specific ones. This is supported by the frequent finding of a slightly elevated serum alanine aminotransferase (ALT) level.¹² This liver pathology is also observed in asymptomatic young adults. The disease activity is low during this phase despite active HBV replication—high serum HBV DNA and HBeAg levels and abundant hepatitis B core antigen (HBcAg) in hepatocyte nuclei. The short term prognosis during this period is good.

The exact mechanism that leads to the development of immune tolerance is not known. Experiments in mice suggest that the transplacental transfer of maternal HBeAg may induce a specific unresponsiveness of helper T cells to HBeAg in neonates born to HBeAg-positive carrier mothers.¹³ As HBeAg and HBcAg are highly cross-reactive at the T-cell level, a reduced helper T-cell response to HBeAg would also impair the T-cell response to HBcAg, resulting in an ineffective cytotoxic T-cell lysis of infected hepatocytes.¹⁴ This hypothesis is supported by the lack of a proliferative response and increase in the interleukin-2 (IL-2) receptors of peripheral blood mononuclear cells after stimulation by recombinant HBcAg.¹⁵ Unresponsiveness can be restored by depleting suppressor T cells, which supports a defect in helper T cells as being the problem.¹⁶ Immune tolerance accounts for the lack of symptoms and inactive liver disease despite the high levels of HBV replication.

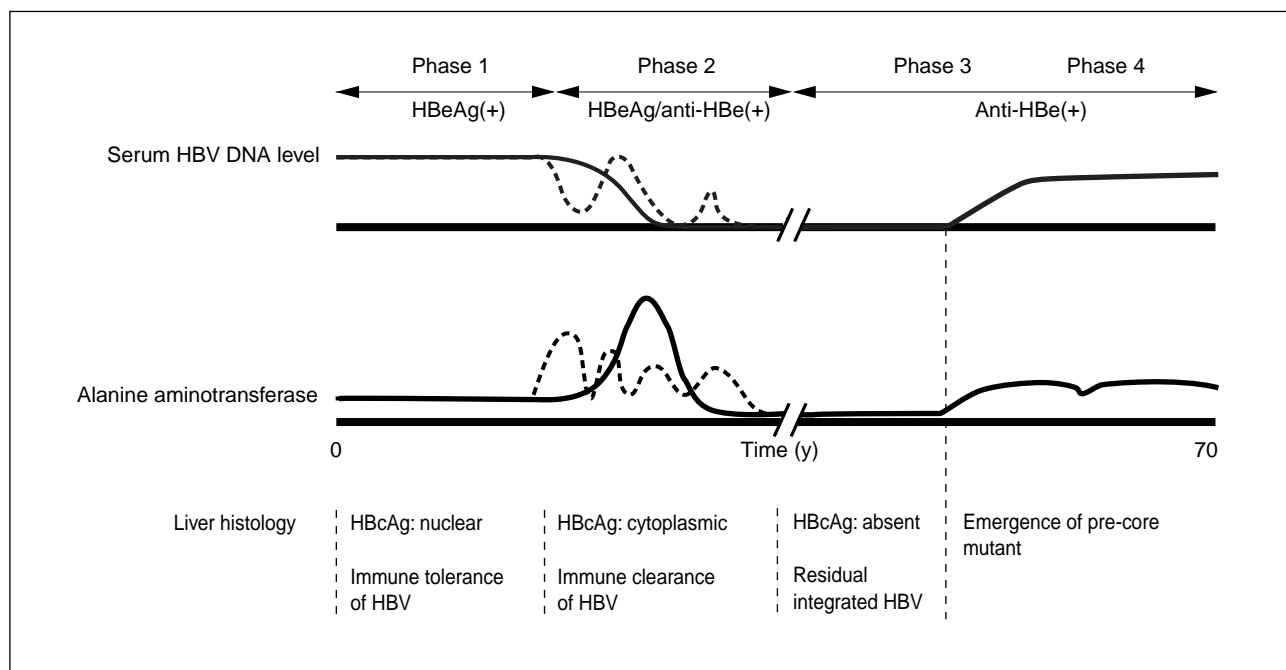


Fig 1. Natural history of chronic hepatitis B virus infection

The immune clearance phase

The immune clearance phase marks the transition from the replicative immune tolerance phase to the non-replicative phase. It is characterised by seroconversion from HBeAg to anti-HBe positivity. With the development of anti-HBe, viral replication usually ceases and the liver disease becomes inactive. However, subsequent reactivation of HBV replication with reappearance of HBV DNA and HBeAg in the serum and a recrudescence of the underlying liver disease may develop. This change is well documented in carriers when immunosuppressive therapy is withdrawn,¹⁷ but the spontaneous reactivation of hepatitis B infection has also been described.¹⁸ A spontaneous clearance of HBeAg is rarely seen during the first two decades of life. The rate of clearance of HBeAg increases with the age of the patient. The cumulative probabilities of spontaneous sustained clearance of HBeAg at the end of one and five years, post-infection, are estimated to be 2% and 12% for patients aged below 20 years, 8% and 32% for patients aged between 21 to 40 years, and 16% and 48% for those older than 40 years.¹⁹ The estimated annual rate of sustained clearance of HBeAg is only 2.8% for patients below the age of 20 years. This low rate of spontaneous clearance of HBeAg, particularly during the first two decades of life, helps to explain why 50% of Chinese HBV adult carriers have serological markers of HBV replication and accounts for the high frequency of maternal to infant transmission in the Chinese. It is uncertain if the spontaneous clearance of HBeAg occurs as a result of breakdown in immune tolerance with age, gradual decrease in production of tolerogenic HBeAg secondary to the development of pre-core mutants, or the appearance of new, non-tolerant HBcAg epitopes through the selection of mutants after numerous cycles of HBV replication.

Disease activity, however, increases during the transition phase. Clinically, a previously asymptomatic carrier may have bouts of symptoms and signs suggestive of acute hepatitis, i.e. acute exacerbations of chronic HBV infection. Expression of histocompatibility antigen class I antigen on the hepatocyte increases, thus favouring the attack on HBV-infected hepatocytes by cytotoxic T lymphocytes.²⁰ The viral antigen responsible for the immunopathogenesis is likely to be HBcAg, because early in the course of acute exacerbations, specific cellular immune responses to HBcAg increase, as revealed by amplified T-cell proliferative responses to HBcAg.²¹ This is further supported by an increase in cytoplasmic HBcAg expression in chronic active hepatitis (CAH).²² In contrast, the nuclear expression of HBcAg and the nuclear and

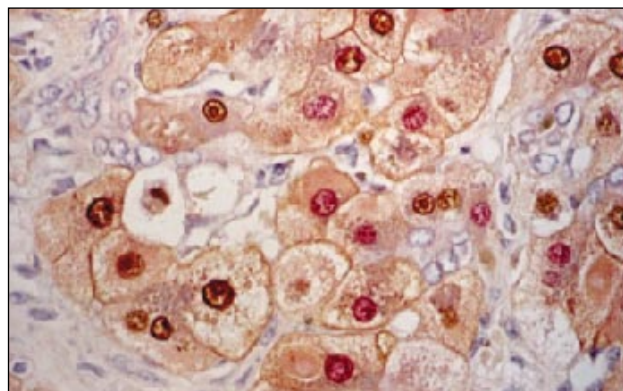


Fig 2. Expression of hepatitis B core antigen in a patient with chronic active hepatitis. Hepatitis B core antigen (brown) shows prominent nuclear and cytoplasmic staining; Hepatitis B envelope antigen (pink) is largely confined to the nuclei (x 350)

cytoplasmic expression of HBeAg show a trend from the carrier state and chronic persistent hepatitis (CPH), through CAH, to cirrhosis, with or without HCC (Fig 2). The presence of cytoplasmic HBcAg has also been found to correlate significantly with lobular activity, portal inflammation, and hepatic activity. During this period, therefore, the liver suffers continuous and repeated bouts of damage, documented by elevated serum ALT, which increases to high levels during acute exacerbations. The acute exacerbation is usually self-limiting, although a small proportion of patients may suffer liver failure during the acute exacerbation, especially those who have cirrhosis. Lobular hepatitis becomes active, and the histological changes may mimic acute hepatitis.²³ There are differences, in terms of immunohistochemical staining, between lobular hepatitis and acute hepatitis. Hepatitis B surface antigen can be demonstrated in hepatocytes in lobular hepatitis but not in acute hepatitis B. In addition, HBcAg is frequently seen in the cytoplasm.²⁴

The histological picture varies from CPH to CPH with lobular hepatitis, to CAH, and active cirrhosis. However, the histological findings that lead to the diagnosis of CAH and CPH with lobular hepatitis are interchangeable. It is not unusual for an HBeAg-positive HBsAg carrier to have CPH with prominent lobular hepatitis or CAH during an acute exacerbation, but after recovering from the exacerbation, the liver may show a typical histological picture of CPH. If cirrhosis does not supervene, after seroconversion to anti-HBe, the liver may show only minimal histological abnormalities or may even appear normal.²⁵ After a series of acute exacerbations, the liver shows cirrhotic changes in about 40% of those with severe CAH. The incidence of cirrhosis has been shown to be

approximately 2% per year.²⁶ Those with persistent HBcAg in the liver and higher serum HBV DNA are more likely to have aggressive forms of the disease, which often progress to cirrhosis.²⁵

Residual hepatitis B virus integrated phase

During this phase, the active replication of HBV ceases. The HBV DNA often has become integrated into the host's chromosomal genome, but HBsAg is continuously being produced by the liver cells that contain these integrated HBV genome.²⁶ Due to the absence of active HBV replication or very low viral replication in the liver, the hepatocytes are spared from attack by the immune cells. The outcome of chronic HBV infection appears to be dependent on the severity of liver injury before HBV replication ultimately ceases. Thus, patients with prolonged and fluctuating transition from the replicative to non-replicative phase (with recurrent exacerbations) are more likely to develop cirrhosis and HCC.^{27,28} Recurrent exacerbations are more frequent in male patients and this may explain why male carriers of HBV are more likely to develop HBV-related cirrhosis and HCC, compared with female carriers. The residual underlying pathology of the liver already present at the time when HBV replication ceases, is crucial for determining the outcome of the HBsAg carrier.²⁹ If cirrhosis has not developed, the previously active hepatitis will regress to an inactive state with a well-preserved liver architecture remaining. On the other hand, if cirrhotic changes are present at the time of HBeAg seroconversion, the cirrhosis will remain and progress, although slowly and usually asymptotically. In those patients with cirrhosis and active HBV replication, the cirrhotic process will remain active. The prognosis is then poor, and hepatic failure or other complications of cirrhosis may appear relatively quickly. A significant proportion of HBsAg carriers will develop HCC,³⁰ especially those with cirrhosis.

Hepatitis B envelope antigen-negative replicative phase

The HBeAg-negative replicative phase is characterised by elevated serum aminotransferase in the absence of HBeAg in serum. The serum anti-HBe may be either positive or negative.³¹ These changes are accompanied by the emergence of an HBV pre-core mutant. The predominant mutation involves a G to A change at nucleotide 1896 in the pre-core region; the mutant is able to form viral particles, but not HBeAg.³¹ As a result, viral replication can remain high in the absence of serum HBeAg. It is not known if this mutation directly affects viral pathogenicity. During this phase, the liver histology shows aggressive liver disease.

Chronic persistent hepatitis is seen in a few patients while changes of severe CAH with active necro-inflammation are seen in more than 50% of cases. Ground-glass hepatocytes with abundant cytoplasmic HBsAg are frequent and HBcAg is detected both in the nucleus and cytoplasm of hepatocytes. The amount of cytoplasmic HBcAg is sometimes impressive, indicating abundant formation and retention in the cytoplasm.³² A membranous localisation of HBcAg has also been observed, supporting the view that it represents a target of immune attack by cytotoxic T lymphocytes.³³

The consequences of chronic hepatitis B virus infection

Patients with chronic HBV infections may ultimately suffer from decompensated cirrhosis and die from its complications (portal hypertension with variceal bleeding, spontaneous bacterial peritonitis, and hepatic failure). Many others, however, die of other concurrent diseases unrelated to their chronic viral infections or liver disease. In addition, it has been estimated that the relative risk of HCC developing in chronic HBV carriers is 100 times higher than that in matched controls.³⁴ The aetiological role of HBV in HCC is further supported by the increased prevalence of tissue HBsAg in cases of HCC, with or without cirrhosis^{35,36} and the association between tissue HBsAg and liver cell dysplasia.³⁷ The mechanisms of carcinogenesis are not clear and appear complex. Hepatitis B virus-induced hepatocarcinogenesis has been ascribed to a variety of causes, including the insertional deregulation of cellular growth control genes by the integrated viral DNA sequences that are commonly found in HCC; the random deregulation of cellular growth control genes by chromosomal and genetic lesions caused by increased hepatocellular turnover and the mutagenic environment of the inflamed liver; and the transcriptional deregulation of cellular growth control genes by the viral transactivating protein (the X protein) that may itself be deregulated secondary to structural changes in the viral genome that occur during integration.

Integrated HBV DNA can be detected in tumour tissue from most HBsAg-positive patients with HCC. As integration appears to occur at random sites in the host genome, it may not play a key role in hepatocarcinogenesis.³⁸ On the other hand, the p53 tumour suppressor gene has been found in about 30% of human HCCs. Somatic mutations at codon 249 of the p53 gene are observed more often in countries where there is dietary contamination by aflatoxin, a mycotoxin capable of inducing HCC in animals.

Aflatoxin B1 is a mutagen that induces G to T base substitutions and shows a preference for p53 codon 249 in assays in vitro.³⁹ The role of this mutation in human HCC is still uncertain.

Previously, primary liver cancer has been classified into HCC and cholangiocarcinoma with a rare combined type of hepatocellular-cholangiocellular carcinoma. Hepatocellular carcinoma has always been considered a single disease based on the assumption that it originates from a single cell type, the hepatocyte or 'hepatocyte precursor cell.' Cholangiocarcinoma is believed to originate from biliary epithelial cells. The diverse clinical and pathobiological behaviours seen, however, suggest that HCC is a heterogeneous disease. Recent evidence from experimental chemical carcinogenesis models of HCC have suggested that 'oval cells,' which possess both hepatocyte and biliary cell markers, are closely related to pluripotent stem cells and have dual potential to differentiate into either hepatocytes or biliary epithelial cells. Can HCC be reclassified, based on the presence or absence of biliary markers and would such reclassification of HCC provide better clinical and pathobiological information?⁴⁰ Liver tissue from 290 Chinese patients with HCC were studied; HBsAg was positive in 86.1% and histological evidence of cirrhosis was identified in 122/151 (80.8%) tissue blocks where adequate liver tissue was available for assessment. The liver specimens included 201 needle biopsies, 73 surgical resection specimens, and 16 specimens from autopsies. Using immunohistochemistry techniques, the expression of hepatocytic differentiation markers (HEP-PAR reactive antigen) and biliary differentiation markers (AE1-AE3, CK19) were studied. It was found that no patient with HCC with biliary markers survived for more than 27 weeks, compared with a 22.6% survival rate for patients with HCC negative for biliary markers.

In the course of chronic HBsAg carriage, HCC can emerge at any time, even as early as three years of age. The cancer is more likely to develop in maternally-transmitted HBsAg carriers, usually becoming apparent after the age of 40 years. Contrary to previous beliefs, HCC grows relatively slowly, at least in its early stage, the volume doubling time being 110 days, on average.⁴¹ There are no symptoms attributable to HCC when the cancer is small. Symptoms develop only after the tumour is big.⁴² The perception of HCC in the past as a rapidly progressive, fatal malignancy is generally erroneous. It may take years for a tumour to grow to a size large enough to cause symptoms.

Conclusion

A better understanding of the natural history of chronic HBV infection would enable us to treat this infection more effectively. As most chronic HBV carriers who are Chinese acquired their HBV infection perinatally, large scale immunoprophylaxis at birth would be the most effective preventive measure.⁴³ To date, interferon is the only agent approved in the West for the treatment of chronic HBV infection. However, the response to interferon in Chinese is unsatisfactory. This is largely due to the presence of the immune tolerance phase in Chinese. Hence, the response to interferon is higher in those Chinese patients with elevated aminotransferase levels (i.e. during the immune clearance phase).⁴⁴ Screening with ultrasound and detecting serum α -fetoprotein has enabled us to detect early resectable HCCs. However, it is still uncertain whether these measures improve the long term survival of patients with HCC.⁴⁵ Further studies on the mechanisms of viral persistence, immunopathogenesis, and hepatocarcinogenesis will shed more light on this important viral infection, and eventually yield more practical and effective means for its control and treatment.

Acknowledgement

This paper was supported by a research grant from the Hong Kong Jockey Club Charities Trust, Hong Kong.

References

1. Maynard JE, Kane MA, Alter MJ, Hadler SC. Control of hepatitis B by immunization: global perspective. In: Zuckerman AJ, editor. *Viral hepatitis and liver disease*. New York: Alan R Liss Inc., 1988:967-9.
2. Lai CL. Chronic hepatitis B-related disease in Hong Kong. *Chronicle*, R Coll Phys Edin 1985;15:157-80.
3. Wu PC, Fang JW, Lai CL, et al. Hepatic expression of hepatitis B virus genome in chronic hepatitis B virus infection. *Am J Clin Pathol* 1996;105:87-95.
4. Carman WF, Jacyna MR, Hadziyannis S, et al. Mutation preventing formation of HB e antigen in patients with chronic hepatitis B infection. *Lancet* 1989;2:588-91.
5. Lok AS. Natural history and control of perinatally-acquired hepatitis B virus infection. *Dig Dis Sci* 1992;10:46-52.
6. Stevens CE, Beasley RP, Tsui J, Lee WC. Vertical transmission of hepatitis B antigen in Taiwan. *N Engl J Med* 1975; 292:771-4.
7. Botha JF, Ritchie MJ, Dusheiko GM, Mouton HW, Kew MC. Hepatitis B virus carrier state in black children in Ovamboland: role of perinatal and horizontal infection. *Lancet* 1984;1:1210-2.
8. Wong VC, Ip HM, Reesink HW, et al. Prevention of the HBsAg carrier state in newborn infants of mothers who are chronic carriers of HBsAg and HBeAg by administration of hepatitis B vaccine and hepatitis B immunoglobulin. Double-blind randomised placebo-controlled study. *Lancet* 1984;1:921-6.

9. Derso A, Boxall EH, Tarlow MJ, Flewett TH. Transmission of HBsAg from mother to infant in four ethnic groups. *BMJ* 1978;1:949-52.
10. Stevens CE, Neurath RA, Beasley RP, Szmuness W. HBeAg and anti-HBe detection by radioimmunoassay: correlation with vertical transmission of hepatitis B virus in Taiwan. *J Med Virol* 1979;3:237-41.
11. Liaw YF, Sheen IS, Chen TJ, Chu CM, Pao CC. Incidence, determinants and significance of delayed clearance of serum HBsAg in chronic hepatitis B virus infection: a prospective study. *Hepatology* 1991;13:627-31.
12. Chen DS. Hepatitis B virus infection, its sequelae, and prevention in Taiwan. In: Okuda K, Ishak KG, editors. *Neoplasm of the liver*. Tokyo: Springer-Verlag, 1987:71-80.
13. Milich DR, Jones JE, Hughes JL, Price J, Raney AK, McLachlan A. Is a function of the secreted hepatitis B e antigen to induce immunologic tolerance in utero? *Proc Natl Acad Sci USA* 1990;87:6599-603.
14. Milich DR, McLachlan A. The nucleocapsid of the hepatitis B virus is both a T-cell independent and a T-cell dependent antigen. *Science* 1986;234:1398-401.
15. Hsu HY, Chang MH, Hsieh KH, et al. Cellular immune response to HBcAg in mother-to-infant transmission of hepatitis B virus. *Hepatology* 1992;15:770-6.
16. Lok AS. Treatment of chronic hepatitis B. *J Vir Hepatitis* 1994;1:105-24.
17. Lau JY, Lai CL, Lin HJ, et al. Fatal reactivation of chronic hepatitis B virus infection following withdrawal of chemotherapy in lymphoma patients. *Q J Med* 1989;73:911-7.
18. Lok AS, Lai CL, Wu PC, Leung EK, Lam TS. Spontaneous hepatitis B e antigen to antibody seroconversion and reversion in Chinese patients with chronic hepatitis B virus infection. *Gastroenterology* 1987;92:1839-43.
19. Lok AS. Replication of hepatitis B virus in Chinese patients with chronic hepatitis B virus infection [MD thesis]. Hong Kong: Univ. of Hong Kong, 1990.
20. Montano L, Miescher GC, Goodall AH, Wiedmann KH, Janossy G, Thomas HC. Hepatitis B virus and HLA antigen display in the liver during chronic hepatitis B virus infection. *Hepatology* 1982;2:557-61.
21. Tsai SL, Lai MY, Yang PM, et al. Acute exacerbations of chronic type B hepatitis are accompanied by increased T cell responses to hepatitis B core and e antigens: implications for hepatitis B e antigen seroconversion. *J Clin Invest* 1992;89:87-96.
22. Wu PC, Lau JY, Lau TK, Lau SK, Lai CL. Relationship between intrahepatic expression of hepatitis B viral antigens and histology in Chinese patients with chronic hepatitis B virus infection. *Am J Clin Pathol* 1993;100:648-53.
23. Liaw YF, Chu CM, Su IJ, Huang MJ, Lin DY, Chang-Chien CS. Clinical and histological events preceding hepatitis B e antigen seroconversion in chronic type B hepatitis. *Gastroenterology* 1983;84:216-9.
24. Hsu HC, Su IJ, Lai MY, et al. Biologic and prognostic significance of hepatocyte hepatitis B core antigen expressions in the natural course of chronic hepatitis B virus infection. *J Hepatol* 1987;5:45-50.
25. Su IJ, Lai MY, Hsu HC, et al. Diverse virological, histopathological and prognostic implications of seroconversion from hepatitis B e antigen to anti-HBe in chronic hepatitis B virus infection. *J Hepatol* 1986;3:182-9.
26. Lok AS, Ma OC. Hepatitis B virus replication in Chinese patients with hepatocellular carcinoma. *Hepatology* 1990;12:582-8.
27. Lok AS, Lai CL. Acute exacerbation in Chinese patients with chronic hepatitis B virus (HBV) infection: incidence, predisposing factors and etiology. *J Hepatol* 1990;10:29-34.
28. Liaw YF, Tai DI, Chu CM, Chen TJ. The development of cirrhosis in patients with chronic type B hepatitis: a prospective study. *Hepatology* 1988;8:493-6.
29. Chen DS, Sung JL. Hepatitis B e antigen and its antibody in chronic type B hepatitis. *J Gastroenterol Hepatol* 1987;2:255-70.
30. Beasley RP. Hepatitis B virus. The major etiology of hepatocellular carcinoma. *Cancer* 1988;61:1842-56.
31. Hadziyannis S, Bramou T, Alexopoulou A, et al. Immunopathogenesis and natural course of anti-HBe-positive chronic hepatitis with replicating B virus. In: Hollinger FB, Lemon SM, Margolis HS, editors. *Viral hepatitis and liver disease*. Baltimore: Williams & Wilkins, 1992:673-6.
32. Bonino F, Rosina F, Rizzetto M, et al. Chronic hepatitis in HBsAg carriers with serum HBV-DNA and anti-HBe. *Gastroenterology* 1986;90:1268-73.
33. Naoumov NV, Portmann BC, Tedder RS, et al. Detection of hepatitis B virus antigens in liver tissue. A relation to viral replication and histology in chronic hepatitis B infection. *Gastroenterology* 1990;99:1248-53.
34. Beasley RP, Hwang LY, Lin CC, Chien CS. Hepatocellular carcinoma and hepatitis B virus. A prospective study of 22707 men in Taiwan. *Lancet* 1981;2:1129-33.
35. Wu PC. Detection of hepatitis B surface antigen in liver biopsies from 655 Chinese patients in Hong Kong. *Asian J Infect Dis* 1978;2:223-9.
36. Ho JC, Wu PC, Gibson JB. Hepatitis B surface antigen in hepatocytes at necropsy: comparison with serological results obtained postmortem or antemortem. *Arch Pathol Lab Med* 1980;104:255-7.
37. Ho JC, Wu PC, Mak TK. Liver cell dysplasia in association with hepatocellular carcinoma, cirrhosis and hepatitis B surface antigen in Hong Kong. *Int J Cancer* 1981;28:571-4.
38. Fung TY, Lai CL, Todd D, et al. Evidence against insertion mutations of cellular oncogenes in HBV-associated hepatomas. In: Szmuness W, Alter HJ, Maynard JE, editors. *Proceedings of the International Symposium on Viral Hepatitis*. Philadelphia: WB Saunders, 1984.
39. Hsu IC, Metcalf RA, Sun T, Welsh JA, Wang NJ, Harris CC. Mutational hotspot in the p53 gene in human hepatocellular carcinomas. *Nature* 1991;350:427-8.
40. Wu PC, Fang JW, Lau VK, Lai CL, Lo CK, Lau JY. Classification of hepatocellular carcinoma according to hepatocellular and biliary differentiation markers. Clinical and biological implications. *Am J Pathol* 1996;149:1167-75.
41. Sheu JC, Sung JL, Chen DS, et al. Growth rate of asymptomatic hepatocellular carcinoma and its clinical implications. *Gastroenterology* 1985;89:259-66.
42. Lai CL, Lam KC, Wong KP, Wu PC, Todd D. Clinical features of hepatocellular carcinoma: review of 211 patients in Hong Kong. *Cancer* 1981;47:2746-55.
43. Ellis RW, editor. *Hepatitis B vaccines in clinical practice*. New York: Marcel Dekker, 1993.
44. Lok AS, Wu PC, Lai CL, et al. A controlled trial of interferon with or without prednisone priming for chronic hepatitis B. *Gastroenterology* 1992;102:2091-7.
45. Kang JY, Lee TP, Yap I, Lun KC. Analysis of cost-effectiveness of different strategies for hepatocellular carcinoma screening in hepatitis B virus carriers. *J Gastroenterol Hepatol* 1992;7:463-8.