

Clinical management of a child with melanotic neuroectodermal tumour of infancy

SHY Wei, LK Cheung, H Tideman, PC Wu

A rare case of melanotic neuroectodermal tumour of infancy affecting the maxilla is reported. These are rare, mainly benign neoplasms that present during infancy. Prompt surgery and rehabilitation using partial dentures are essential to minimise the effects of the deformity. The integrated surgical and prosthodontic management needed to attain good restoration of aesthetic and masticatory function in a child are emphasised. Additional partial dentures need to be made that accommodate the changes in the dental arch that occur as the child grows.

HKMJ 1996;2: 177-180

Key words: Neoplasms, embryonal and mixed; Odontogenic tumors; Surgery, oral; Denture, partial, removable

Introduction

Melanotic neuroectodermal tumour of infancy (MNTI) is a rare, benign neoplasm that presents during infancy.¹ This paper presents a case where the tumour was diagnosed when the child was only four months old. Prompt surgical excision and rehabilitation using a partial denture at the earliest possible time and the subsequent timely replacement with new partial dentures minimised the child's deformity and restored her aesthetic facial profile and masticatory function.

Case report

A Caucasian four-month-old girl was first referred to the Prince Philip Dental Hospital because she had a gradually enlarging pigmented swelling in the anterior part of the right maxilla. Her parents had first noticed this swelling approximately five weeks earlier. The infant had some facial asymmetry (Fig 1a) and the right side was enlarged at the right paranasal area and upper lip.

The intra-oral examination revealed a bluish globular swelling that measured approximately 2 cm in diameter in the right maxilla around the canine and first primary molar region (Fig 1b). The dental alveolus appeared to be displaced downwards into the intra-oral cavity. The lesion was well-defined and firm when palpated. The pigmented mucosa gave the appearance of an eruption cyst.

The periapical radiograph showed a large radiolucent lesion area with a diffuse margin in the right anterior portion of the maxilla, and the lateral incisor and canine appeared to be displaced. An aspiration biopsy was attempted to see if any fluid could be withdrawn but this was unsuccessful. An elliptical incisional biopsy was made over the labial aspect of the swelling and a piece of pigmented tissue was sent for histological examination.

Histopathology of the mucosal biopsy confirmed the clinical diagnosis of MNTI. This is characterised by two distinct populations of neoplastic cells arranged in nests, chords, and alveoli among fairly cellular fibrous tissue. One type of neuroblast-like cells have small, round, deeply basophilic nuclei and scanty cytoplasm while other larger pigmented cells with paler nuclei and moderate cytoplasm usually containing abundant melanin pigment are also present (Fig 2).

A computed tomography (CT) scan was arranged, the details of this finding having been previously re-

Faculty of Dentistry, The University of Hong Kong, Prince Philip Dental Hospital, 34 Hospital Road, Hong Kong:

Department of Children's Dentistry and Orthodontics

SHY Wei, DDS, FRACDS (Dental Surgery)

Department of Oral and Maxillofacial Surgery

LK Cheung, PhD, FRACDS(OMS)

H Tideman, MD, PhD

Department of Pathology

PC Wu, MD, FRCPath

Correspondence to: Prof SHY Wei

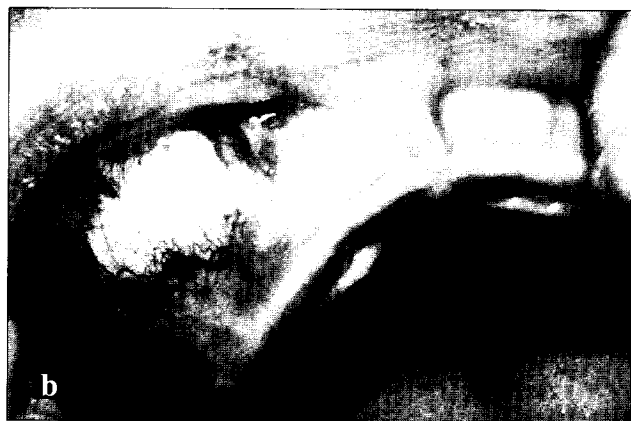
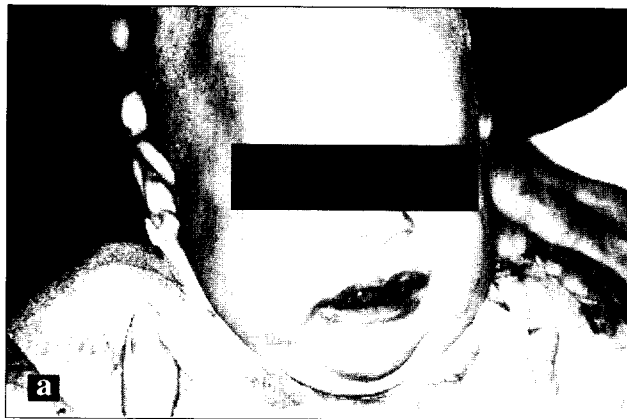
Fig 1a. The four-month-old infant presenting with enlargement of the right maxilla. **Fig 1b.** The intra-oral appearance of the melanotic neuroectodermal tumour of infancy.

ported.² The CT scan showed that the lesion extended from the midline to the right deciduous molar region, with the main mass localised in the alveolus. It produced a well-defined, dome-shaped expansion laterally and was lined by a thin layer of bone; medially, the margin was irregular. The centre was homogeneous. The teeth adjacent to the tumour were displaced laterally. One tooth germ was found inside the lesion. Some irregular radiodense areas were seen in the superior portion of the lesion. In the coronal plane, the lesion was localised to the anterior and middle portions of the maxilla (Fig 3). In the anterior maxilla, the tumour bulged downwards and laterally with no overlying cortical bone. It extended backwards with invasion of the maxillary sinus. The lateral nasal wall was thinned but intact and the orbital floor was not affected.

The patient was admitted to have the lesion surgically excised under general anaesthesia. By that time, the lesion had grown significantly and appeared to be more deeply pigmented and was protruding from the oral cavity. A hemi-maxillectomy

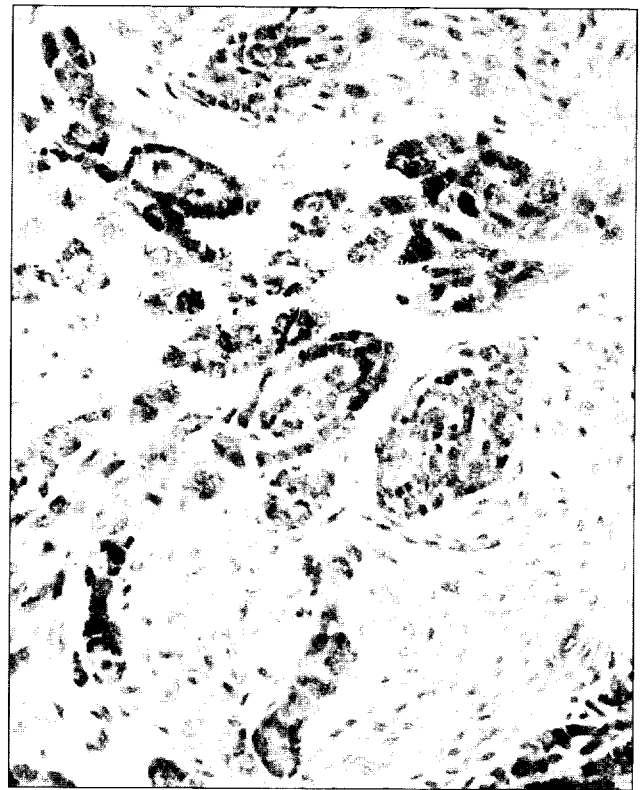


Fig 2. Histopathology of the excised melanotic neuroectodermal tumour of infancy revealed two distinct types of neoplastic cells: small, round, dark cells with scanty cytoplasm and larger, melanin-laden cells with paler nuclei and moderate cytoplasm (H&E, x 200)

was performed via the transoral approach. A mucosal incision was made labially beyond the margin of the lesion, followed by reflection of a mucoperiosteal flap to expose the buccal and superior aspects of the tumour. Incision was then made palatally and with flap raising to delineate the palatal margin.

The tumour was confirmed to be well-encapsulated. It extended medially just beyond the maxillary midline, superiorly to the infra-orbital rim, and posteriorly to the tuberosity region. The tumour was enucleated from the maxillary bone and the rudimentary sinus. Complete clinical excision was achieved. Three tooth germs in close proximity to the tumour were extracted. The extent of the mucosal defect was approximately 3 x 3 cm and was able to be closed primarily by labial advancement flap. No immediate bony reconstruction was attempted. The baby recovered well from the operation and oral healing progressed uneventfully without wound dehiscence.

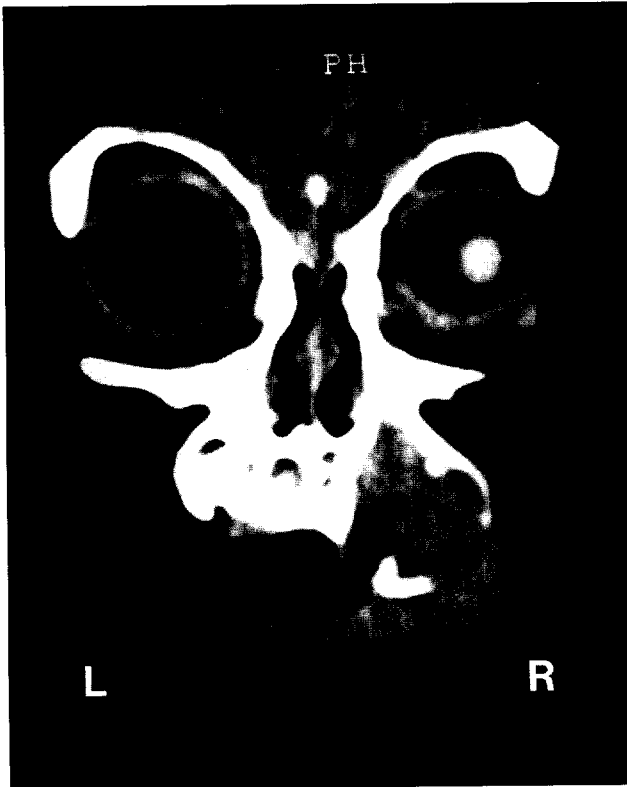


Fig 3. Coronal CT scan showing a homogeneous soft tissue swelling in the right maxillary alveolus. The lesion extends into the undeveloped maxillary antrum. A tooth germ has been displaced downward by the mass.

The excised tumour in the anterior maxilla was a well-circumscribed, solid, grey-black tumour that measured 30 x 28 x 16 mm. It elevated the mucosa anteroinferiorly and was surrounded by an incomplete, thin rim of bone with two displaced tooth germs lying on its lateral sides near the mucosal surface. Histologically, it showed typical features of MNTI similar to those of the previous biopsy.

The patient was seen regularly at three-monthly and subsequently, at six-monthly intervals after the surgery. When the eruption of the remaining primary teeth was complete in September 1991, a partial denture was constructed for the patient. A second new maxillary partial denture was made to accommodate the changes in the patient's growing dental arch.

The intra-oral appearance of the maxilla and the patient's remaining dentition in June 1993 are shown (Fig 4a) and the partial denture in the maxilla is shown (Fig 4b). In June 1995, the right first permanent molar erupted. A new partial denture will need to be con-

structed when the maxillary permanent molars become more fully erupted. The partial denture helped to restore the function and facial appearance as can be seen in photographs of the patient without a partial denture (Fig 5a) and with a partial denture in place (Fig 5b).

Discussion

Melanotic neuroectodermal tumour of infancy is a rare, benign neoplasm^{1,3,4} that requires accurate and prompt diagnosis and radical surgical excision because of the rapid growth of the lesion in an infant.^{5,6} The clinical manifestations are not unlike those of an eruption cyst or hematoma and apart from the facial enlargement may be asymptomatic for quite some time.^{7,8} An incisional biopsy should confirm the diagnosis with certainty.^{9,10}

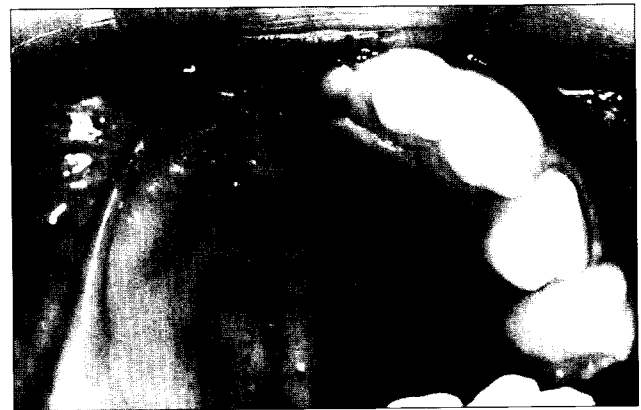

Fig 4a. Intra-oral view of the maxilla after complete healing and eruption of the primary teeth on the left side

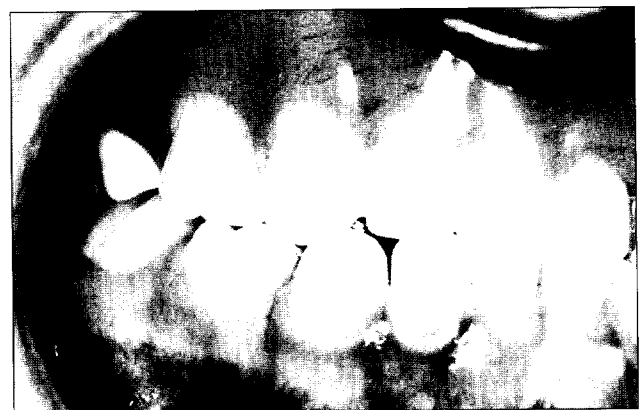

Fig 4b. The intra-oral view of the partial denture providing good aesthetics and function

The use of CT scans to more precisely locate the size, anatomical location, and lesion borders are particularly helpful to the surgeon in planning the most

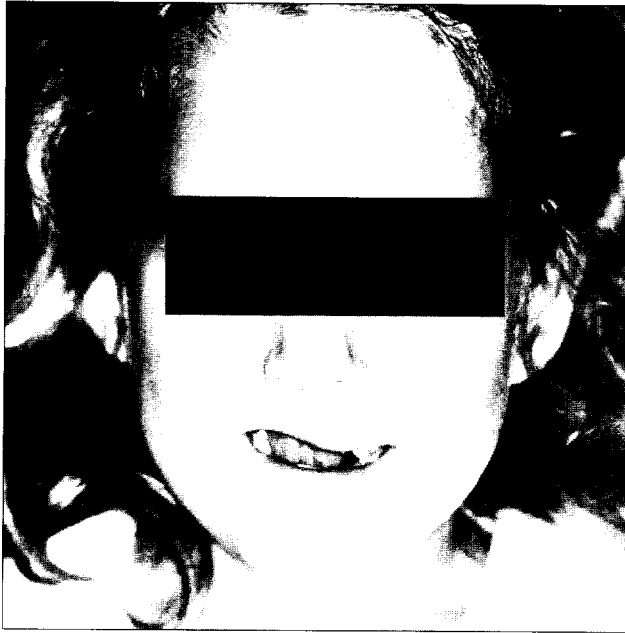

Fig 5a. There is considerable facial deformity and compromised aesthetics without the partial denture in place

conservative surgical approach to preserve as much as possible of the vital band tissue remaining for maxillary growth.² The location of permanent tooth germs, if available, is also helpful and every attempt should be made to prevent the first permanent molars from becoming carious because they provide good denture retention anchorage.

The use of the partial denture even when the patient was only three years old was without major problems. The remaining primary teeth provided a firm anchorage for clasping of the partial denture on one side, while the maximal tissue-bearing denture base was provided on the other side. Good sulcus depth for the necessary denture retention was important. The facial appearance was markedly improved with the prosthesis in place as it supported the lips and facial muscles.

There will be a need to monitor the fit of the prosthesis at regular intervals with the growth of the residual maxilla and new partial dentures will have to be made accordingly. Furthermore, the need to have optimal oral health and the use of fluorides to preserve the remaining sound dentition becomes a high priority so that the partial denture support is not compromised or jeopardised. Because of the extent of the bone and jaw deficiency after the partial maxillectomy, it is felt that the patient would benefit from oral rehabilitation when an adult. A titanium mesh implant to which fixed prosthodontic anchors could be built will be inserted.

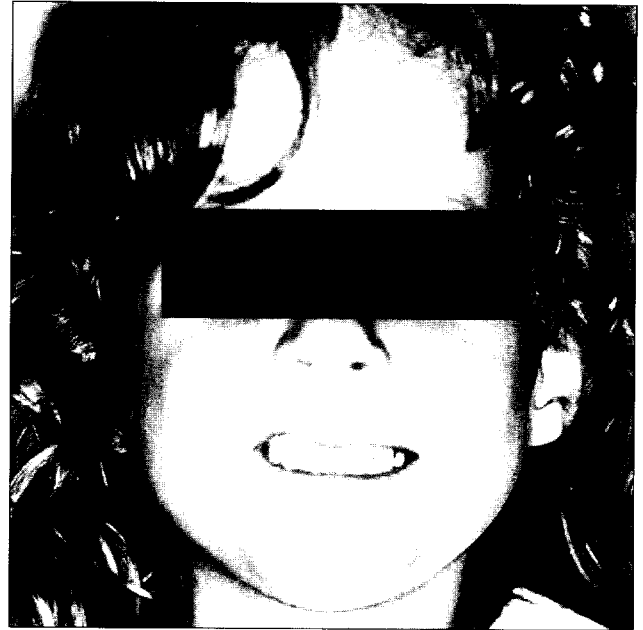

Fig 5b. The partial denture helps to support the facial musculature resulting in improved aesthetics and function

These implants are integral to the making of a functional and aesthetic prosthesis for a patient.

References

1. Borello ED, Gorlin RJ. Melanotic neuroectodermal tumor of infancy – a neoplasm of neural crest origin: report of a case associated with high urinary excretion of vanillylmandelic acid. *Cancer* 1966;19:196-206.
2. Cheung LK, Piette EM, Tideman H. Melanotic neuroectodermal tumour of infancy: a case report emphasizing the importance of computed tomography. *Dentomaxillofac Radiol* 1991;20:172-4.
3. Stokke T. Pigmented jaw tumor in an infant: a melanocytoma. *Acta Odontol Scand* 1968;26:657-66.
4. Lopez J, Jr. Melanotic neuroectodermal tumor of infancy: review of the literature and report of a case. *J Am Dent Assoc* 1976;93:1159-64.
5. Johnson RE, Scheithauer BW, Dehlin DC. Melanotic neuroectodermal tumour of infancy: a review of seven cases. *Cancer* 1983;52:661-6.
6. Nagase M, Ueda K, Fukushima M, Nakajima T. Recurrent melanotic neuroectodermal tumour of infancy: case report and survey of 16 cases. *J Oral Maxillofac Surg* 1983;11:131-6.
7. Hupp JR, Topazian RG, Krutchkoff DJ. The melanotic neuroectodermal tumor of infancy: report of two cases and review of the literature. *Int J Oral Surg* 1981;10:432-66.
8. Handley GH, Peters GE. Melanotic neuroectodermal tumor of infancy. *South Med J* 1988;81:170-2.
9. Dehner LP, Sibley RK, Sauk JJ, et al. Malignant melanotic neuroectodermal tumor of infancy: a clinical, pathologic, ultrastructural and tissue culture study. *Cancer* 1979;43:1389-410.
10. Culter L, Chaudhry AP, Topazian RG. Melanotic neuroectodermal tumor of infancy: an ultrastructural study, literature review and reevaluation. *Cancer* 1981;48:257-70.