

Surgical reconstruction of the jaws after ablative surgery

N Samman, LK Cheung, H Tideman

Ablative surgery of the jaws may be necessary when malignant disease or destructive benign disease occurs. Surgical reconstruction needs to include the restoration of masticatory function so that the quality of life after operation is optimal. This paper describes some current concepts in functional reconstruction after mandibulectomy and maxillectomy and includes case examples that illustrate bone-grafting procedures and occlusal rehabilitation by implant-borne restorations.

HKMJ 1996;2: 161-166

Key words: Mandible; Maxilla; Surgery, oral; Titanium; Bioprosthesis; Implants, artificial; Prosthesis, dental

Introduction

Ablative surgery can be defined as any operation which entails the extirpation of pathological tissue. Defects resulting from such surgery vary from one anatomical region to another in their aesthetic and functional impact on the patient. Reconstruction normally refers to the replacement and rebuilding of an original form and function that has been lost. Surgical reconstruction does not simply involve the replacement of a missing part after extirpative surgery, rather, the concept includes restoration of the appropriate function. Hence, when planning reconstruction, the extent of ablation, the type of missing tissue, and the precise functions served by the missing parts are important considerations.

Oral tumour resection results in serious aesthetic and functional disorder of the face and mouth, however, recent advances in reconstructive surgery have significantly improved the quality of life of these patients. When resection includes part of the upper or lower jaw, the aim of reconstruction should encompass not only the restoration of aesthetics, speech, and swallowing, but also the recreation of an alveolar ridge suitable for prosthetic rehabilitation of the dental oc-

clusion so that masticatory function can also be restored. Specifically, successful jaw rehabilitation requires the restoration of bone continuity, dental arch form, height and bulk, and the provision of a fixed or removable (preferably endosseous) implant-borne dental prosthesis.

In this paper, we present our concepts for the reconstruction of the mandible and maxilla, illustrated by selected examples, and discuss existing limitations and possible developments. No attempt is made to review the subject in a comprehensive manner.

The mandible

Ablative surgery in the mandible takes one of three forms: enucleation, resection with preservation of continuity (marginal resection), and resection with continuity defect (segmental resection). The location of the lesion as well as the extent of the surgery in the mandible are additional considerations when planning reconstruction.

Enucleation

This treatment may be applied to benign cysts and aggressive lesions such as keratocysts and cystic ameloblastomas but is contraindicated for solid ameloblastomas and malignant disease. Enucleation entails the removal of teeth surrounded by the lesion, the extirpation of lesional tissue with minimum oral soft tissue loss, and the preservation of inferior alveolar nerve integrity. Mandibular bony continuity is also preserved although the residual bone forms a shallow

Department of Oral and Maxillofacial Surgery, The University of Hong Kong, Prince Philip Dental Hospital, 34 Hospital Road, Hong Kong

N Samman, MRCS, FDSRCS
LK Cheung, BDS (Glasg), PhD
H Tideman, MD, DDS

Correspondence to: Dr N Samman

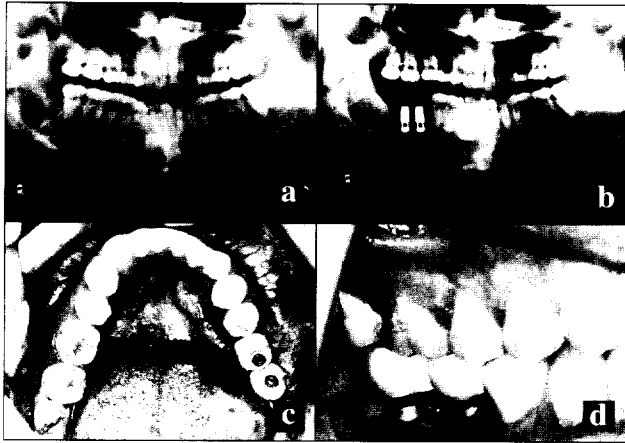


Fig 1. Keratocyst of the right mandible in a 19-year-old woman. 1a. The lesion extended widely into the ramus and undermined the molar teeth. 1b. Fourteen months after enucleation, spontaneous bone regeneration permitted IMZ endosseous implant insertion in the new bone. 1c and 1d. Restoration of masticatory function was achieved by implant-borne restorations of the missing molars.

trough. Spontaneous bone regeneration within this trough and alveolar ridge remodelling occur within 18 months, and restoration of masticatory function requires only the replacement of teeth removed during the enucleation process. The location and extent of the procedure within the mandible are of no great influence on the outcome, and the regenerated bone is usually sufficient to permit endosseous implant-borne restorations, if desired (Fig 1).

Marginal resection

In this procedure, a segment of the alveolar process and teeth is excised together with the surrounding soft tissues. The extent of resection varies with the size of the lesion, and access for surgery may be intraoral or transcuteaneous, which requires lip splitting and mandibular swing. The procedure normally preserves the integrity of the inferior alveolar nerve, does not lead to loss of skin or tissue bulk, but frequently results in a degree of soft tissue loss intraorally. When the excised segment is located posteriorly, closure of the defect is achieved either primarily or by pedicled or free soft tissue transfer and microvascular anastomosis, depending on the requirements of each individual case. Primary osseous augmentation is not normally undertaken. The patient may be given a conventional or implant-borne dental prosthesis, but in most cases this requires a vestibuloplasty procedure¹ to deepen the buccal and lingual sulci and to enable the fabrication of an adequately functional prosthesis.

When the excised segment is extensive, or when it is located centrally within the dental arch leaving intact dentoalveolar segments on either side of the defect, immediate reconstruction by primary bone grafting is necessary. A typical example of this situation and the available methods of rehabilitation, is when a marginal resection in the region of the mandibular symphysis is performed (Fig 2). This results in preservation of the chin contour externally, but the missing anterior alveolus and teeth cause the lower lip to collapse inwards into the mouth. This causes loss of the oral seal and aesthetic problems in addition to the obvious masticatory compromise.

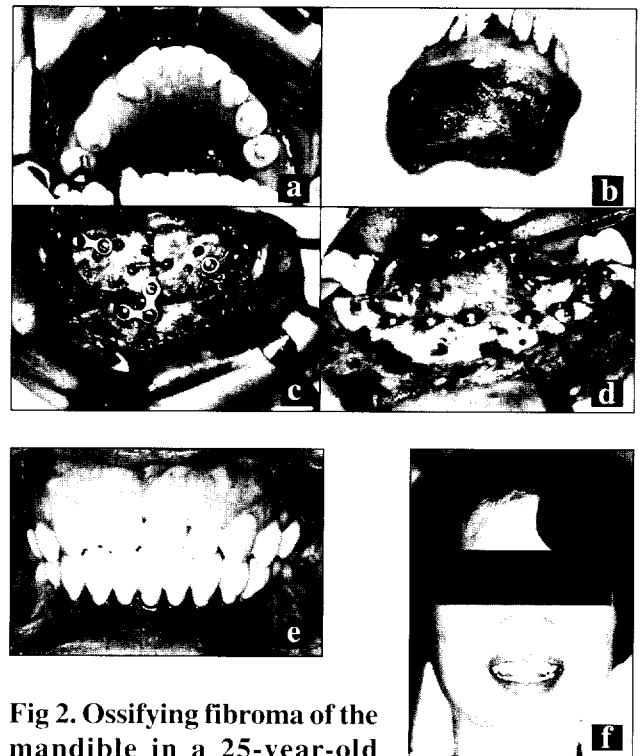


Fig 2. Ossifying fibroma of the mandible in a 25-year-old woman. 2a. The expanding lesion in the symphysis. 2b. Resection of the lesion by marginal mandibulectomy. 2c. Immediate cortico-cancellous iliac bone graft fixed by titanium miniplates. 2d. Nine months after surgery, endosseous implants were inserted into the reconstructed alveolus. Note the adequate height and bulk of the bone. 2e. Completed implant-borne restorations. 2f. The external clinical appearance on completion of treatment.

These sequelae can be avoided by the immediate reconstruction of the anterior alveolus with autogenous free-bone grafting at the same time. Bone is normally harvested from the ilium in the form of corticocancellous block graft or cancellous chips. Block grafts can then be segmented to simu-

late the curved contour of the excised segment and to restore the alveolar bone height. These are fixed to the residual mandible using titanium bone mini-plates and screws or osteosynthesis wires. Adequate soft tissue closure over such a graft is mandatory for success, and often can be achieved primarily by advancing tissue from the periphery of the excision. This temporarily compromises the free movement of the tongue and lower lip which is later regained by a vestibuloplasty procedure after graft healing. Masticatory function is restored by endosseous implant insertion into the new bone, and an implant-borne fixed or removable prosthesis is fabricated (Fig 2).

Segmental resection

This is frequently combined with neck dissection and results in significant tissue loss, both intraorally and externally. A segmental mandibulectomy causes collapse and instability of the residual mandible segments due to muscle pull, and results in severe aesthetic and functional compromise (Figs 3a and 3b). Although a lateral defect can be tolerated and is compatible with life, a defect that includes the symphyseal region may compromise the patency of the airway due to loss of tongue anchorage. Hence, reconstruction may vary greatly in extent and various methods and techniques have been applied to this problem.

Bridging the defect with a metallic plate stabilizes the segments and often restores facial contour. A metallic plate may be combined with a pedicled soft tissue flap or a free flap with microvascular anastomosis to provide additional soft tissue bulk or the cover that may be required. Although this treatment may be ideal for some patients, it cannot be considered a functional reconstruction in the true sense, because it does not permit the restoration of masticatory ability. Metallic plates may also be combined with a free bone graft in the form of a rib or a cortico-cancellous block from the ilium, but these have a strong tendency to undergo irregular resorption within a short time. Equally, the use of a free-rib graft alone is prone to failure due to fracture or resorption, and even successful cases are unable to provide the osseous bulk to support a prosthesis (Fig 3).

Preformed alloplastic cribs permit the restoration of mandibular shape and contour including the symphysis and gonial angle, thus restoring an aesthetic facial contour. When the resection includes the mandibular condyle, a free costochondral graft can also be harvested and stabilized within the dacron or titanium mesh crib, enabling the mandibular joint to be

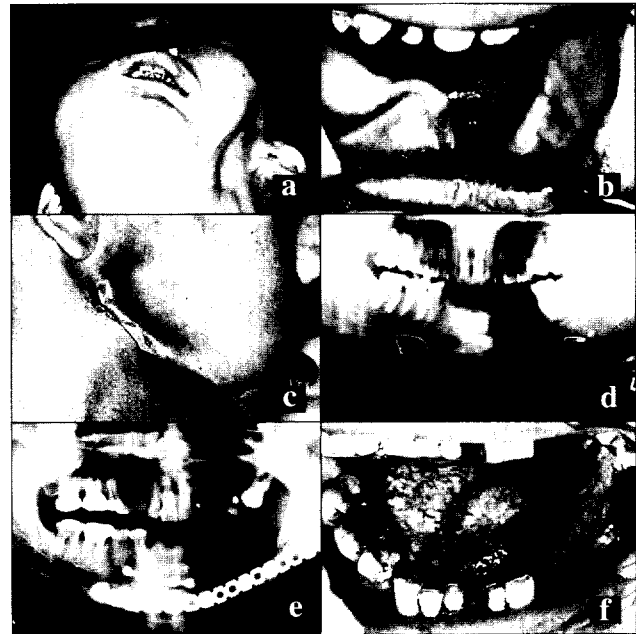


Fig 3. Problems after mandibular resection. 3a. Without reconstruction, mandibulectomy causes a significant aesthetic compromise. 3b. Unstable segments collapse and are disabling. 3c. The bridging plate stabilised the mandible but was later extruded and had to be removed. 3d. Bridging by a free-rib graft failed due to resorption and non-union with the mandible. 3e. A bridging plate in combination with a free-bone graft does not improve on the use of either of them alone. 3f. A vascularised free flap may solve the problem of tissue loss and give cover but generally does not permit occlusal rehabilitation.

reconstructed simultaneously (Fig 4b). The method also provides sufficient bone height and bulk to accommodate endosseous implants and achieve ideal rehabilitation of masticatory function (Fig 4).

Our experience is that the reconstructed bony bridge retains 80% of its original height in the long term, with limited resorption occurring mostly in the first six months after reconstruction.² The method has a failure rate of 20% due to infection and loss of the grafted bone. This mostly occurs when the reconstruction is performed immediately after the tumour resection. Metal cribs are known to enhance the amount of radiation absorbed in the tissues adjacent to the metal, however, this does not occur with the dacron mesh.³ Hence, post-operative radiotherapy does not specifically contribute to mucosal dehiscence in cases where the dacron mesh is used, but may do so when metallic plates or cribs are used.

The use of free vascularised osseous or osteo-cutaneous tissue for mandibular reconstruction is a recent advance that has revolutionised reconstruction of the oral cavity after ablative surgery.^{4,5} As with any method, there are advantages and disadvantages involved and correct selection of the patient and the donor tissue are essential for success.⁶ Further reference to this important aspect of reconstruction is beyond the scope of this paper.

The restoration of lower lip sensation in mandibular reconstruction is now standard procedure. A suitable length of sural nerve is harvested and grafted into the defect by microneural anastomosis to the proximal and distal residual stumps of the inferior alveolar nerve (Figs 4c and 4d). Our preference is for the nerve graft to be of sufficient length to loop around the lower border of the reconstructed mandible to reduce the likelihood of its being dam-

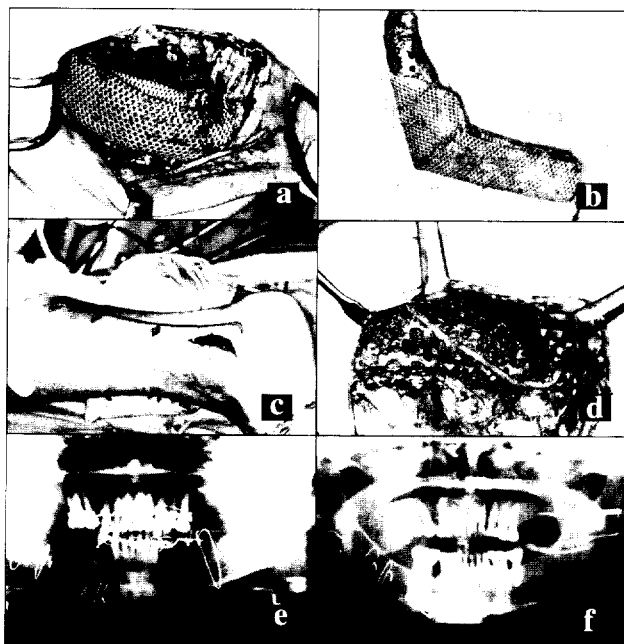


Fig 4. Mandibular reconstruction by the dacron or titanium mesh technique. 4a. Preformed dacron mesh can restore the symphyseal contour. 4b. Dacron tray accommodating the free costochondral graft to replace the condylar segment. 4c. The sural nerve graft harvest is done at the same time as the bone graft harvest. 4d. Sural nerve grafting in addition to the bone grafting completes the functional reconstruction of the mandible. 4e. Post-operative appearance two weeks after reconstruction of the right mandible by dacron tray and bone graft. 4f. Appearance five years after jaw reconstruction, showing full occlusal rehabilitation by implant-borne restorations.

aged during placement of the endosseous dental implants at a later stage.

The maxilla

Maxillectomy ranges from a limited resection of the dentoalveolar segment via an intraoral approach to a radical resection that includes the orbital floor by a transfacial approach. In some cases, facial skin and/or orbital contents may be included in the resection. Complex reconstructions such as this are beyond the scope of this paper. The aim of this section is to address the problem of the intraoral hemimaxillectomy defect.

Traditionally, the hemimaxillectomy defect was grafted with split skin and filled with a removable prosthesis, presumably to allow frequent inspections for tumour recurrence. It is generally accepted that such a defect is a social and functional handicap, which can only partly be remedied by a prosthetic device. With the advent of computed tomography and flexible fiberoptic nasendoscopy that has replaced naked eye inspection for tumour recurrence, the traditional view favouring obturation instead of reconstruction has been challenged. Many patients also undergo maxillectomy for the removal of locally aggressive lesions, and these patients cannot be denied reconstruction. Therefore, it is necessary to develop a successful reconstructive method that restores facial appearance and occlusal function after maxillectomy.

Soft tissue closure of the maxillectomy defect is feasible by various methods. Local flaps of palatal mucosa from the contralateral side or ipsilateral cheek mucosa can be used for small defects, whereas pedicled regional flaps are advocated for larger defects. The buccal fat pad is an extremely useful bundle of tissue which may be able to cover moderate-sized defects in the posterior maxilla.⁷ By far the most popular pedicled flap, however, is the ipsilateral temporalis myofascial flap. Microvascular-free tissue transfer has also gained in popularity and provides an increasing range of flaps to choose from. Radial forearm, latissimus dorsi, rectus abdominis, and jejunum flaps have been advocated. Although these techniques may find ready application in many circumstances, they rarely provide a unique solution.

Our experience suggests that the temporalis flap is the simplest, most versatile, and readily available source of well-vascularised soft tissue cover for the maxillectomy defect.⁸ The flap is rotated into the mouth, medial to the zygomatic arch, with the fascial surface left exposed in the oral cavity without the need for a skin graft cover.

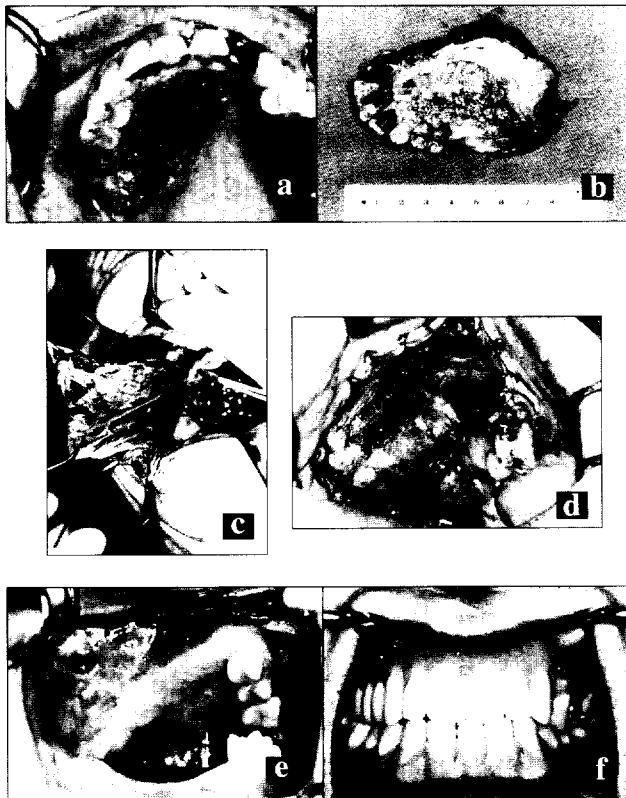


Fig 5. Rehabilitation after maxillectomy with ipsilateral temporalis myofascial flap. 5a. Squamous cell carcinoma of the right maxilla. 5b. Right maxillectomy. 5c. The ipsilateral temporalis myofascial flap is rotated below the zygomatic arch and brought into the oral cavity. 5d. The defect is closed by suturing the temporalis flap to the excision margins, with the fascial surface left exposed in the oral cavity. 5e. Appearance after vestibuloplasty. The fascial surface is now covered by regenerated oral mucosa. 5f. Functional removable denture in situ.

The fascia granulates gradually over a period of six to eight weeks, and a mucosal surface is obtained that is suitable for rehabilitation using a conventional removable denture (Fig 5). The temporal depression left by the flap transposition is reliably camouflaged with mouldable acrylic⁹ or by rotating the residual posterior muscle fibres forward. Although this soft tissue reconstruction may be entirely adequate for many patients, the denture may be subject to undesirable movement during function due to the inherent mobility of the underlying soft tissue flap. It is therefore necessary to attempt osseous reconstruction for certain patients, notably the young and those with benign disease, in order to optimise the occlusal function.

In 1993, we described a new method for immediate reconstruction following maxillectomy.¹⁰ After resection, the ipsilateral temporalis myofascial flap is rotated below the zygomatic arch to reach the defect. The flap is then divided in its sagittal plane to obtain two layers of tissue, the medial one being used to isolate the maxillary sinus and nasal cavity. The lateral layer with the fascial surface provides oral lining over the autogenous bone graft packed into a prefabricated titanium mesh that is anchored to the zygomatic buttress and the bony resection margins (Figs 6a and 6b). Studies of the temporalis muscle vasculature have confirmed the bipenniform anatomy of the muscle, and

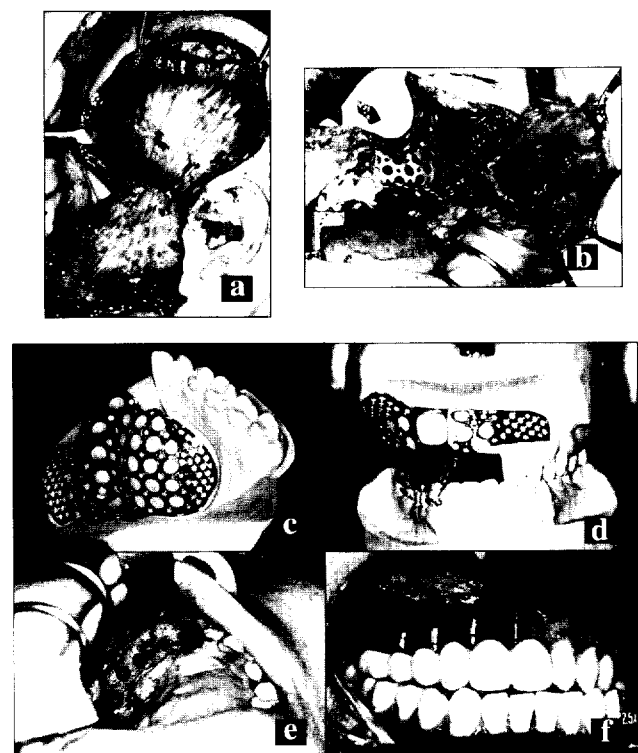


Fig 6. New method of osseous reconstruction after maxillectomy. 6a. Ipsilateral temporalis myofascial flap divided in the sagittal plane. 6b. Titanium mesh fixed in position with the medial layer of the divided temporalis flap sutured to isolate the nasal and sinus cavities from the mesh and bone graft. The lateral layer is ready to cover the mesh after insertion of the bone graft. 6c. Pre-planned titanium mesh, individually fabricated on a model of the patient's upper jaw, with the position of future dental implants already determined. 6d. Prosthetic splint made to aid correct positioning of the mesh to achieve an optimal jaw relationship. 6e. The reconstructed maxilla at implant insertion showing adequate arch form and bone bulk. 6f. Completed rehabilitation using fixed implant-borne restorations.

have explained the feasibility and reliability of surgically splitting the temporalis muscle in this reconstructive technique (unpublished observations).

Six months post-operatively, endosseous dental implants are inserted into the reconstructed alveolar ridge to enable prosthetic rehabilitation as illustrated (Figs 6e and 6f). Our experience so far is that the results are excellent in most cases, with some failure due to infection of the bone graft, as happens with other methods that use free bone-grafting techniques. The method is still being evaluated by a prospective case series.

Research and development

There are two areas of research being conducted locally that are of immediate relevance to jaw reconstruction. The first is in the field of bone substitutes where current efforts are testing the effects of demineralised bone matrix on improving the quality and quantity of bone grafts.¹¹⁻¹³ The second involves the development of a pre-operative planning process for the titanium mesh, with the aim of securing optimal positioning of the reconstruction. This enables symmetry and perfection of the facial contour to coincide with the ideal occlusal relationship, both being needed to achieve good dental aesthetics and masticatory function.¹⁴

References

1. Tideman H. A technique of vestibuloplasty using a free mucosal graft from the cheek. *Int J Oral Surg* 1972;1:76-80.
2. Cheung LK, Samman N, Tong AC, Tideman H. Mandibular reconstruction with the dacron urethane tray: a radiologic assessment of bone remodeling. *J Oral Maxillofac Surg* 1994;52:373-80.
3. Schwartz HC, Wollin M, Leake DL, Kagan AR. Interface radiation dosimetry in mandibular reconstruction. *Arch Otolaryngol* 1979;105:293-5.
4. Hayter JP, Cawood JI. Oral rehabilitation with endosteal implants and free flaps. *Int J Oral Maxillofac Surg* 1996;25:3-12.
5. Urken ML, Weinberg H, Vickery C, Buchbinder D, Lawson W, Biller HF. Oromandibular reconstruction using microvascular composite free flaps. *Arch Otolaryngol Head Neck Surg* 1991;117:733-44.
6. Ip WY, Chow SP. Microvascular free flaps for reconstruction. *J Hong Kong Med Assoc* 1994;46:263-7.
7. Samman N, Cheung LK, Tideman H. The buccal fat pad in oral reconstruction. *Int J Oral Maxillofac Surg* 1993;22:2-6.
8. Cheung LK, Samman N, Tideman H. Reconstructive options for maxillary defects. *Ann R Aust Coll Dent Surg* 1994;12:244-51.
9. Cheung LK, Samman N, Tideman H. The use of mouldable acrylic for restoration of the temporalis flap donor site. *J Cranio- Maxillo- Fac Surg* 1994;22:335-41.
10. Tideman H, Samman N, Cheung LK. Immediate reconstruction following maxillectomy: a new method. *Int J Oral Maxillofac Surg* 1993;22:221-5.
11. Rabie AB, Deng YM, Samman N, Hägg U. The effect of demineralised bone matrix on the healing of intramembranous bone grafts in rabbit skull defects. *J Dent Res* 1996;75:1044-50.
12. Rabie AB, Lie Ken Jie RK. Integration of endochondral bone grafts in the presence of demineralised bone matrix. *Int J Oral Maxillofac Surg*. In press.
13. Rabie AB, Zhou D, Samman N. Ultrastructural identification of cells involved in the healing of intramembranous and endochondral bones. *Int J Oral Maxillofac Surg*. In press.
14. Clark RK, Chow TW, Luc HW, Tideman H, Chung WC, Samman N. Prosthodontic aspects of a new method for functional reconstruction following maxillectomy. *J Prosthet Dent* 1995;73:559-62.