

Halo-pelvic traction: a means of correcting severe spinal deformities

Louis CS Hsu, FHKAM (Orthopaedic Surgery)
 Guest Author, Education and Research Committee
 Hong Kong Museum of Medical Sciences Society

The 'Halo', a metal ring secured with four screws into the outer dipole of the skull, was popularised by Perry and Nickel in the 1970s for prolonged cervical traction in place of the old-fashioned, two-screw skull tongs used in cervical fractures. With pins inserted into the lower femur, they devised the halo-femoral traction for correction of spinal deformities. This proved to be inefficient and the femoral pins got infected very easily. The patient also had to remain in bed during the traction.

With extension of the Sandy Bay Convalescent Home to become the Duchess of Kent Children's Hospital in the late 1960s, Prof A Hodgson, Prof A Yau, and Dr J O'Brien developed the pelvic attachment of the halo-pelvic traction (HPT) device. The pelvic ring is secured to the two halves of the pelvis by two threaded pins that traverse the whole length of the two halves of the pelvis. Extension bars fitted to the halo and pelvic rings provide fixation and traction when the bars are gradually elongated. The apparatus provided very powerful corrective forces (Fig 1a). It also allowed the patient to remain ambulant during treatment (Fig 2).

In the later stages of the HPT improvement, gauges attached to extension bars were used to measure the forces generated through the spine and helped the surgeons to monitor and regulate the speed of distraction. Initially, the gauges were

a mechanical compression spring attached to the bottom of the bars (Fig 1b). Later, electrical cells were used and attached to the middle of the bars (Fig 1c).

Halo-pelvic traction was ideal for the treatment of severe and rigid spinal deformities such as healed tuberculous kyphosis. The strong fixation allowed osteotomies of the rigid deformity to be staged and distraction forces to be gradually applied between stages of surgery without fear of instability or spinal cord compression (Fig 3).

The apparatus can also be used for corrective treatment of various types of severe scoliosis such as that due to neurofibromatosis and poliomyelitis. Again, the powerful distraction forces generated can provide very dramatic correction of the rigid deformities. Spinal fusions are performed after correction of the deformities (Fig 4).




FIG 1. Three specimens of the halo-pelvic traction apparatus donated to the Hong Kong Museum of Medical Sciences by the Department of Orthopaedic Surgery, Queen Mary Hospital, in March 1996: the (a) classical and two later versions that incorporate (b) mechanical and (c) electronic measuring gauges

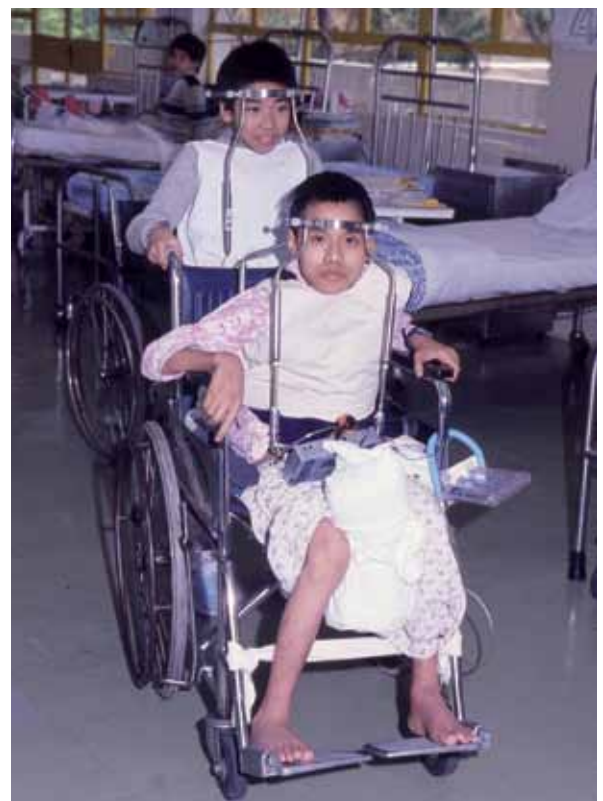

FIG 2. Photographs of patients in the Duchess of Kent Children's Hospital with the apparatus in situ

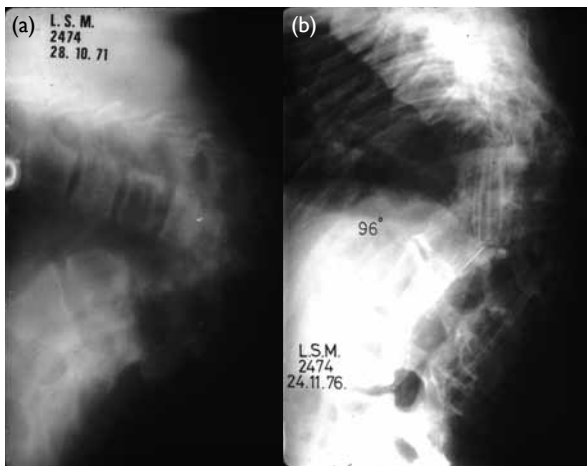


FIG 3. Radiographs of a tuberculous kyphotic spine (a) before and (b) after halo-pelvic traction and fusion

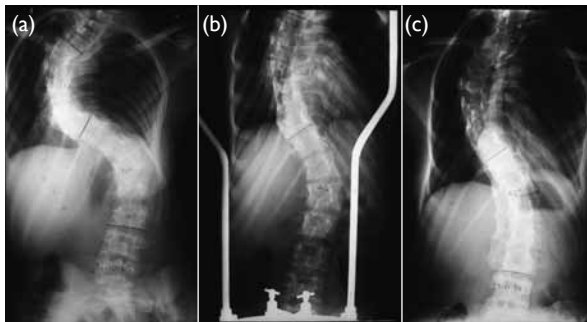


FIG 4. Serial radiographs of a severely scoliotic spine (a) before and (b) during treatment with the halo-pelvic traction device, and (c) after traction correction and fusion

Spinal tuberculosis and poliomyelitis epidemics in Hong Kong in the 1950s and 60s left the region with a significant number of patients with rigid spinal deformities. Halo-pelvic traction came at the right time as many patients could be appropriately treated with this apparatus. Over 150 patients received HPT treatment at the Duchess of Kent Children's Hospital during 1970 to 1982. All of them had severe spinal deformities. They usually wore the apparatus for 3 to 6 months, and a few of them for up to a year.

However, the powerful distraction forces along the spine, which houses the spinal cord, and prolonged immobilisation resulted in some alarming and unexpected complications.

During distraction, stretching the spine also

stretches the nerves that run from the skull to the trunk. The cranial nerves, especially the sixth, tenth, eleventh and twelfth, and the brachial plexus, especially the fifth and sixth nerve roots, can suffer from traction injuries. In kyphotic patients, the spinal cord may also be compressed by internal kyphosis. Detected early, these patients usually recover. Daily neurological examination is an important routine in managing the patients.

The cervical spine, being the most flexible part of the spine, can be dramatically elongated by HPT. The spinal cord may not keep pace. A small number of patients with tuberculous kyphosis, despite a gradual and slow distraction, suddenly developed swinging temperatures and fluctuating rises in blood pressure. These changes were attributed to an early 'coning' of the medulla oblongata through the foramen magnum, causing disturbances in the temperature and blood pressure control centres. These were quickly reverted by loosening the distraction; the patients had no long-term effects from these episodes.

An unexpected complication was discovered in the odontoid process of the second cervical vertebra. The blood supply to this process is essentially derived from ligaments attached to this bone. With tension in the ligaments from distraction, blood supply to the odontoid process is jeopardised leading to avascular necrosis. This was a rather common complication in HPT. The necrosis itself recovered, but stiffness and early degeneration of the cervical spine developed in almost all of the patients.

Powerful traction to the flexible and fragile cervical spine would cause minor damages to the intervertebral ligaments and discs leading to mild swelling, bleeding, and inflammatory changes. Together with prolonged immobilisation, spontaneous fusion had occurred in the cervical spine in some patients.

With improvements in public health, especially with infectious disease control and school screening programmes for spinal deformities, severe deformities requiring surgery are becoming rare. The HPT device is now very rarely used, if at all, in Hong Kong and in the rest of the world. Like many other surgical instruments and equipment, it has become a historical relic, though the service it provided to the many deformed patients earns it a place in the Hong Kong Museum of Medical Sciences.

References

1. O'Brien JP, Yau AC, Hodgson AR. Halo pelvic traction: a technic for severe spinal deformities. *Clin Orthop Relat Res* 1973;93:179-90.
2. Dove J, Hsu LC, Yau AC. The cervical spine after halo-pelvic traction. An analysis of the complications of 83 patients. *J Bone Joint Surg Br* 1980;62-B:158-61.
3. Yau AC, Hsu LC, O'Brien JP, Hodgson AR. Tuberculosis kyphosis: correction with spinal osteotomy, halo-pelvic distraction, and anterior and posterior fusion. *J Bone Joint Surg Am* 1974;56:1419-34.