

Plombage treatment for pulmonary tuberculosis in Hong Kong

TW Wong, FHKAM (Emergency Medicine)
Member, Education and Research Committee
Hong Kong Museum of Medical Sciences Society

Tuberculosis (TB) became a notifiable disease in 1939 in Hong Kong. In that year, 4443 deaths were attributed to TB, which accounted for 9.2% of all deaths. In short, TB was an important killer in the early part of the 20th century. The state of TB treatment in 1949, when the Columban Sisters began their service in Hong Kong, was described as follows by Sister Gabriel of Ruttonjee Sanatorium:

“In 1949 there were over 7,000 notifications and 2,600 deaths from TB in the Colony. TB was in epidemic proportions, the highest incidence being in children and young adults. Meningitis was rife and many infants with miliary TB died of the disease. There were no anti-TB drugs at this time; the only treatment advised was good food, bed rest and isolation of the infectious. BCG vaccination did not come for another two years. Streptomycin was the only medicine which could kill the bacilli but it was not available in HK except for what was confiscated at the China border. This could only be used, under order from the medical department, for children with meningitis or with miliary disease. The management of patients being admitted was not very encouraging.”¹

Before the advent of anti-TB drugs, there was no specific treatment for this infection. Surgical treatment could be offered in some early cases. In the 1930s, the three most commonly performed operations were sectioning of the phrenic nerve, creating an artificial pneumothorax, and thoracoplasty by removing some ribs.² The aims of these operations were to collapse the part of the lung harbouring the disease and, hopefully, halt disease progression. The Annual Medical Report of the government for the year 1934 reported that the University Medical Unit at Government Civil Hospital had started a special clinic for artificial pneumothorax of pulmonary TB cases.

Plombage as a special form of collapse therapy was introduced in the 1930s. This procedure entailed placing some inert substance in the extrapleural space to cause collapse of the lung. The X-ray shown in Figure 1 shows the right upper lobe of the lung

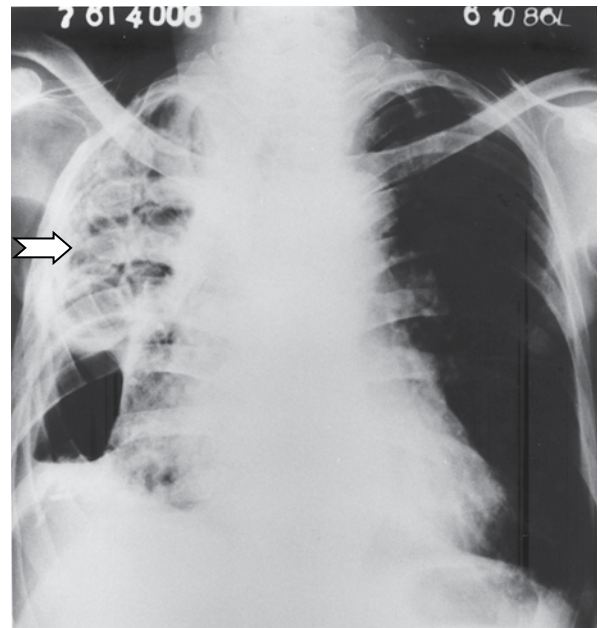


FIG 1. Chest radiograph showing plastic plombage balls in situ

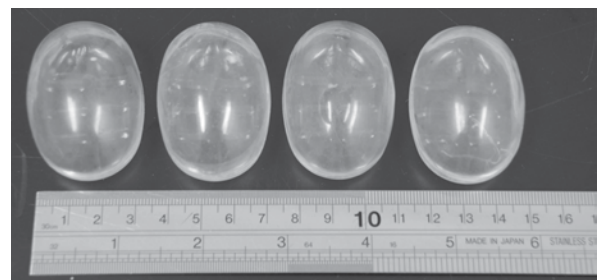


FIG 2. Plastic plombage balls, similar to the ones shown in Figure 1, donated to the Hong Kong Museum of Medical Sciences by Ruttonjee Sanatorium in 1996 when these were no longer in use

being collapsed by the use of plastic balls (Figure 2). Other inert substances like paraffin wax, oil, etc, could also be used. However, complications including haemorrhage, infection, and fistula formation were not uncommon. Plombage treatment fell into disfavour with the advent of anti-TB drugs in the 1950s.

References

1. O'Mahoney MG. A time of transition. Columban Sisters 2005: 11.
2. Li SF. Indications contraindications and end results in the surgical treatment of pulmonary TB. *Caduceus* 1931;10:167-77.