

# Ketamine-induced cholangiopathy

KL Lui <sup>\*1</sup>, WK Lee <sup>2</sup>, Michael KK Li <sup>1</sup>

Hong Kong Med J 2014;20:78.e1-2  
DOI: 10.12809/hkmj133796

A 28-year-old woman presented to us in November 2010 because of deranged liver function test results; predominantly she had raised ductal enzyme levels (gamma-glutamyl transferase, 1088; reference range, 12-57 IU/mL); alkaline phosphatase (ALP) 579 (reference range, 46-127) IU/mL, alanine transaminase (ALT) 183 (reference range, 10-57) IU/mL with normal bilirubin levels. Upon further questioning, she had been a ketamine abuser for 5 years and was followed up by psychiatrists. She was completely asymptomatic and physical examination yielded nil abnormal. Her ALP level was excessive (154 IU/mL) and her ALT level was 48 IU/mL. Ultrasound of hepatobiliary system (HBS) showed a dilated common bile duct (CBD) of 1.1 cm in diameter with tapering over lower end. A gallstone was present in the gallbladder. Therefore, the endoscopic retrograde cholangiopancreatography (ERCP) was performed in November 2011, and showed a 5-cm stricture at the lower end of the CBD together with small bilateral segmental strictures in the intrahepatic ducts (Fig 1). Brush cytology of the stricture of CBD revealed no malignant cells. A plastic stent bypassing the CBD was inserted for drainage. Liver function test findings did not improve after stenting but repeated ultrasonography of the HBS showed that with the 5.7-mm stent in situ, the CBD was not

dilated. A liver biopsy was therefore performed, and showed mild-to-moderate portal fibrosis with ductular proliferation (Fig 2) and periportal copper deposits were noted (Fig 3). These findings were consistent with chronic cholestasis at both the extrahepatic and intrahepatic level. There were no features suggestive of primary biliary cirrhosis, or primary sclerosing cholangitis. The colonoscopy was normal and showed no evidence of inflammatory bowel disease. The patient's liver function improved

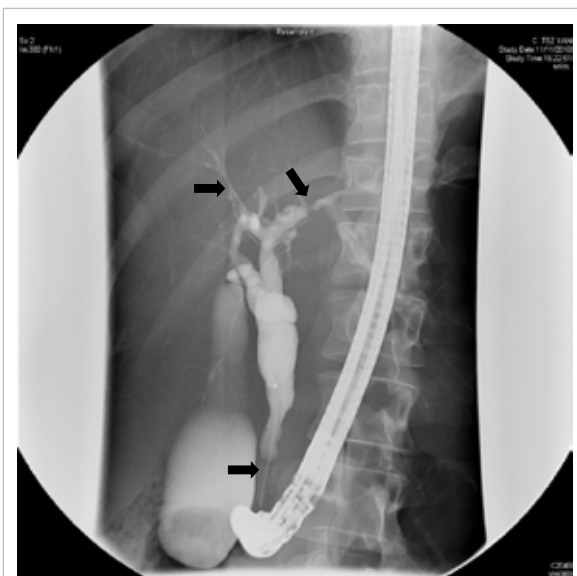


FIG 1. A 5-cm stricture at the lower end of the common bile duct with irregularity over intrahepatic ducts on both sides (arrows)

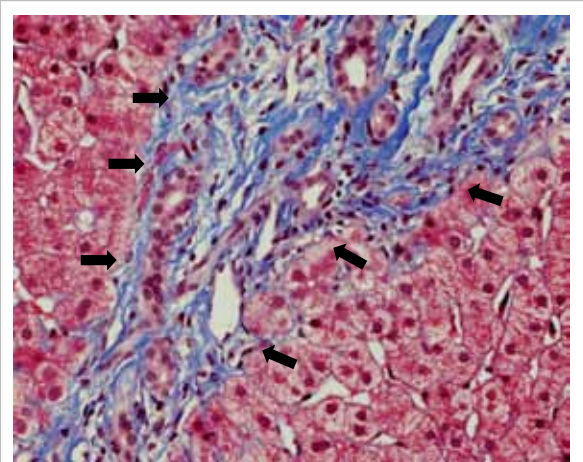


FIG 2. Intermediate power view showing portal fibrosis and ductal proliferation (arrows) [Masson's trichrome stain, original magnification x 200]

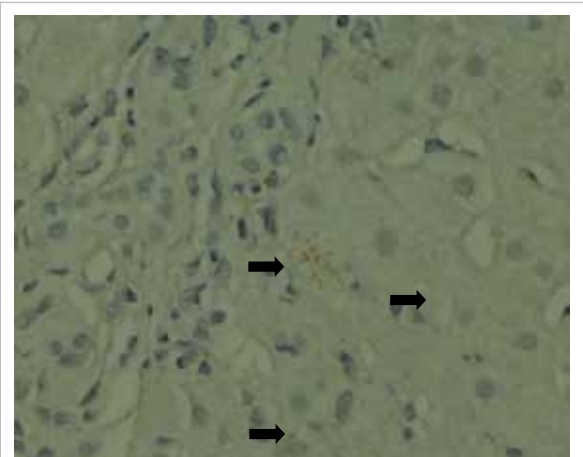


FIG 3. Small periportal copper deposits are evident (arrows) [orange-red granules, rhodanine stain; original magnification x 400]

after she ceased the recreational use of ketamine. However, her stricture remained unchanged in the follow-up ERCP and repeated biopsies over the CBD stricture only showed reactive changes.

The first report on the association of liver injury with ketamine dates back to 1980.<sup>1</sup> The exact cause of the ketamine-induced stricture is not known, but chronic use is associated with hepatocyte damage and fibrosis to the liver.<sup>2</sup> Ketamine intake also stimulates the N-methyl-D-aspartic acid receptor in the smooth muscle cells of the bile duct and chronic stimulation may induce inflammation and fibrosis finally resulting in strictures.<sup>3,4</sup> Affected patients are usually asymptomatic initially, and only manifest abnormal ductal enzyme level after 1 to 2 years of recreational ketamine use, indicating that chronicity and repeated use seem to be involved. Both intrahepatic and extrahepatic stricture might also develop and complicated with cholangitis, especially in the presence of gallstones. Definitive management entails cessation of ketamine intake, whereupon liver function improves, though the stricture may be permanent and warrant stenting to relieve any obstruction.<sup>4,5</sup> This case report points that ketamine abuse also causes liver and biliary damage, quite apart from urinary and neurological sequelae.

<sup>1</sup> **KL Lui \***, MMedSc, FHKCP

<sup>2</sup> **WK Lee**, FRCPath, FHKAM (Pathology)

<sup>1</sup> **Michael KK Li**, FRCP, FHKAM (Medicine)

<sup>1</sup> *Division of Gastroenterology and Hepatology, Department of Medicine and Geriatrics*

<sup>2</sup> *Department of Pathology*

*Tuen Mun Hospital, Tuen Mun, Hong Kong*

\* Corresponding author: klluitc@yahoo.com.hk

## References

1. Dundee JW, Fee JP, Moore J, Mclroy PD, Wilson DB. Changes in serum enzyme levels following ketamine infusions. *Anaesthesia* 1980;35:12-6.
2. Wai MS, Chan WM, Zhang AQ, Wu Y, Yew DT. Long-term ketamine and ketamine plus alcohol treatments produced damages in liver and kidney. *Hum Exp Toxicol* 2012;31:877-86.
3. Jankovic SM, Jankovic SV, Stojadinovic D, Jakovljevic M, Milovanovic D. Effect of exogenous glutamate and N-Methyl-Daspartic acid on spontaneous activity of isolated human ureter. *Int J Urol* 2007;14:833-7.
4. Lo RS, Krishnamoorthy R, Freeman JG, Austin AS. Cholestasis and biliary dilatation associated with chronic ketamine abuse: a case series. *Singapore Med J*;52:e52-5.
5. Seto WK, Ng M, Chan P, et al. Ketamine-induced cholangiopathy: a case report. *Am J Gastroenterol*;106:1004-5.