

Laparoscopic removal of an eroding Mirena coil through the sigmoid colon

Uterine perforation is the most serious complication associated with intrauterine devices (IUDs).¹ Removal of intra-abdominal foreign bodies (FBs) and eroding coils using a minimal access approach (MAA) offers the benefits of good exposure, minimal hospital stay, few wound complications, and high patient satisfaction. However, the procedure is not without risks.² The most recent progress in the application of MAA to remove peritoneal FBs entails transluminal migration of the scope through the bowel lumen.³ Herein, we report on a patient who underwent laparoscopic retrieval of a Mirena coil migrating through the uterine cavity.

A 37-year-old mother of two children by normal vaginal delivery underwent Mirena coil insertion in October 2007. Abdominal ultrasonography (US) confirmed normal position of the coil. One year later, she developed vaginal bleeding and lower abdominal

pain. X-rays and US examinations were inconclusive. Accordingly, expulsion of the coil was assumed. Because her symptoms were not responding to conservative measures, she underwent a diagnostic gynaecological laparoscopy, which showed that the shank of the coil was in the wall of the sigmoid colon. At re-laparoscopy (with preoperative bowel preparation), the coil was found to be partially eroding the wall of the sigmoid colon without perforating the mucosa. The coil was successfully extracted through one of the 5-mm ports. Three interrupted vicryl stitches were used to close the site of erosion (Fig). The postoperative course was uneventful and the patient was discharged on the second postoperative day. Subsequent follow-up was unremarkable.

Perforation of the uterus by an IUD is a serious complication, which is reported to occur following 1/350 to 1/2500 insertions.⁴ Early recognition is

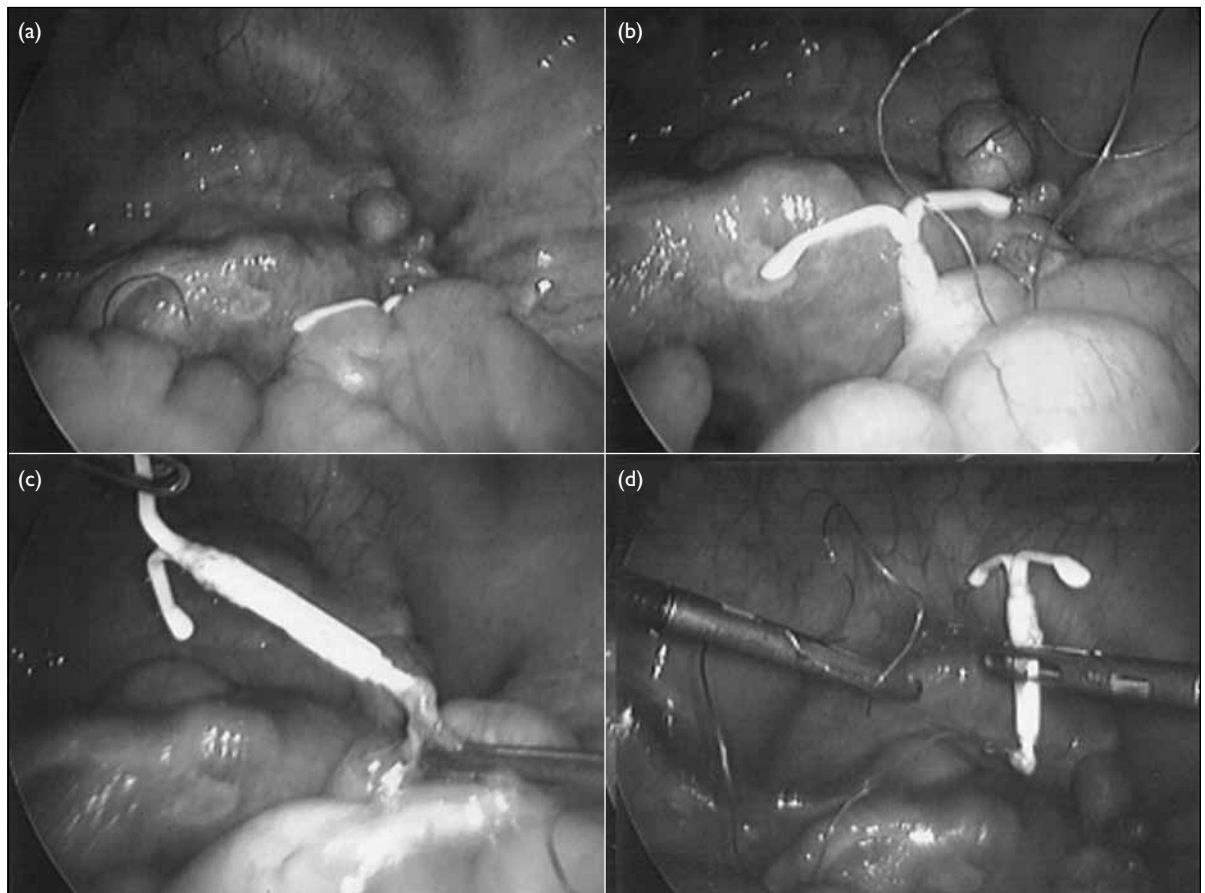


FIG. The coil eroding through the sigmoid colon and its removal

(a) The coil is barely seen in the initial laparoscopic view, (b) a close view shows the coil is embedded in the sigmoid colon wall, (c) extraction was done using two laparoscopic graspers, and (d) complete removal

important so as to prevent serious erosions through the nearby viscera. The symptoms, infection, damage to the abdominal viscera or prevention of erosion through nearby vital organs, and patient requests are the commonest indications for removing FBs. Localising FBs usually depends on plain X-rays, US, magnetic resonance imaging, computed tomography, and laparoscopy.

Removal techniques range from very simple to challenging procedures, depending on the surgeon's experience, the size and site of the FB, how long it had been present, as well as instrumentation and theatre facilities. Migration or erosion of an IUD could lead to serious morbidity, but the course is unpredictable. Erosion through the large or small bowel and the urinary bladder has been reported,⁵ for

which colonoscopy could be the method of choice to remove it through the wall of the large bowel.

This case is an example of the feasibility, safety, and effectiveness of laparoscopy to manage a patient with a symptomatic migrating Mirena coil.

A Hussain¹, FRCS (Eng), FRCS

Email:azahrahussain@yahoo.com

K Omar², FRCOG

S El-Hasani¹, FRCS (Eng), FRCS

¹General Surgery Department, and ²Obstetric and Gynaecology Department, Princess Royal University Hospital, Farnborough Common, Orpington, Kent, BR6 8ND, United Kingdom

(The authors have contributed equally to this article.)

References

1. Heinberg EM, McCoy TW, Pasic R. The perforated intrauterine device: endoscopic retrieval. *JLS* 2008;12:97-100.
2. Chapron C, Querleu D, Bruhat M, et al. Surgical complications of diagnostic and operative gynaecological laparoscopy: a series of 29966 cases. *Hum Reprod* 1998;13:867-72. [crossref](#)
3. Wu C, Prachand VN. Reverse notes: a hybrid technique of laparoscopic and endoscopic retrieval of an ingested foreign body. *JLS* 2008;12:395-8.
4. The Society of American Gastrointestinal and Endoscopic Surgeons. Guidelines for diagnostic laparoscopy. Available from: <http://www.sages.org/publications/guidelines/guidelines-for-diagnostic-laparoscopy/>. Accessed 23 Jul 2013.
5. Ceccato V, Boileau A, Roblin M, Tariel D, Bon D, Estrade V. Migration of an intrauterine device into the bladder [in French]. *Prog Urol* 2007;17:256-9. [crossref](#)