

# Uncommon cause of severe pneumonia: co-infection of influenza B and *Streptococcus*

KW Lam 林錦華  
KC Sin 冼佳卓  
SY Au 區碩賢  
SK Yung 翁世光

Influenza and pneumococcus co-infection can cause severe morbidity and mortality. Usually, this entails influenza A, while infection by influenza B is rarely serious. The literature describes influenza A epidemics leading to prolific loss of lives, notably the 1918 epidemic was blamed for the deaths of 40 to 50 million people. In this report, four patients were infected by influenza B during the influenza epidemic of 2011/12 in Hong Kong. All of them were previously healthy and had no chronic diseases; they were admitted to the hospital due to influenza-like symptoms. They rapidly deteriorated with multi-organ failure, and were subsequently diagnosed to be infected with influenza B and streptococci that gave rise to severe pneumonia. Three of them were infected with *Streptococcus pneumoniae* and one with *Streptococcus pyogenes*. All of them had leukopenia, septic shock, and acute kidney injury; two of whom died despite aggressive antibiotic treatment and organ support in the intensive care unit. According to the literature, this is the second case report of severe invasive pneumococcal pneumonia secondary to influenza B infection.

## Introduction

Influenza and pneumococcus are two of the most important infectious agents afflicting mankind. Co-infection of these two pathogens poses a particularly serious threat to humans. During the influenza pandemic in 1918, an estimated 40 to 50 million people died as a result and many of the deaths were attributed to co-infection. There are three types of influenza viruses, A, B, and C, of which type C viruses cause only sporadic cases in humans. By contrast, influenza A and B give rise to epidemics; the more devastating epidemics with loss of lives are commonly related to influenza A.<sup>1</sup> If influenza A and streptococcal infection co-exist, the mortality is particularly high, whereas with influenza B the infection is usually less severe. To the best of our knowledge, there was only one report of co-infection of influenza and pneumococcus causing severe infection in three young adults known to have had no pre-morbid condition.<sup>2</sup>

Herein, we report on four young adults infected by a combination of influenza B virus and streptococcus, who all experienced fulminant courses with multi-organ failure. It is the first report in Hong Kong of severe bacterial chest infection with septic shock secondary to influenza B infection in previously healthy adults.

## Case reports

### Case 1

A 34-year-old previously healthy man was admitted to the hospital because of a severe chest infection in February 2012. He had experienced chills, vomiting, diarrhoea, and severe cough in the 5 days before admission. After admission to the emergency department, his condition deteriorated rapidly with the onset of severe respiratory failure. He was intubated and transferred to the intensive care unit (ICU) for further management.

The initial chest X-ray showed consolidation near the right heart border and left middle zone, which rapidly progressed to bilateral haziness. The complete blood count revealed a normal haemoglobin level (125 g/L), severe leukopenia ( $0.5 \times 10^9/L$ ), and thrombocytopenia ( $29 \times 10^9/L$ ). His C-reactive protein level was 219 (reference level, <5) mg/L. He developed acute kidney injury with a serum creatinine level raised to 230 (reference range, 47-82)  $\mu\text{mol/L}$ . His liver function test results were normal on admission. Nasopharyngeal aspirate submitted to reverse transcription-polymerase chain reaction was negative for influenza A virus RNA, but positive for influenza B virus RNA. Urinary streptococcal antigen and legionella antigen were negative. Blood culture grew *Streptococcus pyogenes* which was sensitive to penicillin.

The patient developed septic shock with multi-organ failure, and was treated with

Key words  
Influenza B virus; Intensive care; Shock,  
septic; *Streptococcus*

Hong Kong Med J 2013;19:545-8  
DOI : 10.12809/hkmj133835

Intensive Care Unit, Queen Elizabeth  
Hospital, Jordan, Hong Kong  
KW Lam, MB, BS, FHKAM (Medicine)  
KC Sin, MB, BS  
SY Au, MB, BS  
SK Yung, MB, BS

Correspondence to: Dr KW Lam  
Email: lamkw1@ha.org.hk

## 嚴重肺炎的罕見病因：乙型流感併發鏈球菌感染

同時感染流感和肺炎球菌會有高發病率和死亡率，起因通常牽涉甲型流感，而乙型流感病毒的感染很少會引致嚴重的情况。文獻記載甲型流感疫情導致多人死亡，特別是在1918年的疫情造成四千至五千萬人死亡。本文報告在香港2011至2012年流感肆虐期間四個乙型流感的病例。四名病人受感染前的健康狀況良好，沒有慢性疾病。他們均因流感症狀被送往醫院，且病情迅速惡化，出現多器官功能衰竭，隨後被確診感染乙型流感及鏈球菌而引致嚴重肺炎。其中三人感染肺炎鏈球菌，另一人則感染化膿性鏈球菌。他們都有白細胞減少症、感染性休克及急性腎損傷。雖然在深切治療部施以積極的抗生素治療和器官功能支持，最終兩人死亡。根據文獻，這是感染乙型流感繼發嚴重入侵性肺炎球菌性肺炎的第二個病例報告。

vasopressors to maintain his blood pressure and continuous renal support for acute kidney injury. It was difficult to maintain his oxygenation, so he received venovenous extracorporeal membrane oxygenation for 5 days.

Initially he was treated with meropenem, azithromycin, oseltamivir, and vancomycin, and later received high-dose penicillin (when the blood culture result became available). He then developed ventilator-associated pneumonia due to *Acinetobacter* and was treated with colistin. A tracheostomy was performed 19 days after admission to the ICU, where he remained for 30 days before being discharged to the general ward.

### Case 2

A 37-year-old previously well man was admitted to the hospital because of severe pneumonia in March 2012. He had had cough, sputum, and sore throat for 4 days before admission. After admission to the emergency department, his condition rapidly deteriorated and he developed severe respiratory failure, for which he was transferred to the ICU and intubated.

The chest X-ray showed consolidation over right lower lobe, left lingual lobe, and left lower lobe. His complete blood count showed a normal haemoglobin level (153 g/L), normal platelet count ( $191 \times 10^9$  /L), and severe leukopenia ( $2.4 \times 10^9$  /L). He also developed acute kidney injury and with a serum creatinine level of 177  $\mu$ mol/L. His liver function test results were unremarkable. The C-reactive protein level was 143 mg/L. Blood culture grew *Streptococcus pneumoniae* serotype 3. The serum influenza A titre was not raised but the serum influenza B titre increased more than 4-fold (1:20 to 1:320) in 1 week. He was treated with high-dose penicillin, oseltamivir and

ceftriaxone, but later developed ventilator-associated pneumonia due to *Pseudomonas aeruginosa* that was treated with intravenous ceftazidime. He also developed acute kidney injury and started renal replacement therapy. A tracheostomy was performed 2 weeks after intubation. He stayed in the ICU for 40 days before being discharged to the general ward.

### Case 3

A 41-year-old previously well man was admitted to the hospital for a severe chest infection, having had breathlessness, cough and sputum for 3 days in March 2012. The initial chest X-ray showed right perihilar haziness and right lower lobe consolidation. The complete blood picture showed a normal haemoglobin level (150 g/L), neutropenia ( $0.5 \times 10^9$  /L) and thrombocytopenia ( $95 \times 10^9$  /L). He also developed acute kidney injury with a creatinine level of 335  $\mu$ mol/L, but routine liver function test results were unremarkable (bilirubin 10  $\mu$ mol/L, alkaline phosphatase 32 IU/L, and alanine aminotransferase 12 IU/L; respective reference ranges were 5-27  $\mu$ mol/L, 53-141 IU/L, and 8-36 IU/L). Nasopharyngeal swab for influenza B by immunofluorescence was positive and for influenza A it was negative. Blood culture grew *S pneumoniae* of serotype 3. The patient's condition deteriorated rapidly with the onset of severe shock and respiratory failure. He was intubated and transferred to ICU where he received piperacillin/tazobactam, oseltamivir, and azithromycin.

He developed profound shock with severe metabolic acidosis and disseminated intravascular coagulopathy. Despite treatment with high-dose inotropes and intravenous immunoglobulin, he succumbed on the day of admission to the ICU.

### Case 4

A 60-year-old man was admitted to the hospital for community-acquired pneumonia, having had breathlessness with cough and sputum for 2 days in January 2012. He had visited Mainland China 20 days earlier. Physical examination yielded crepitations at both lung bases.

A complete blood picture showed a normal haemoglobin level (151 g/L), leukopenia ( $0.4 \times 10^9$  /L), and thrombocytopenia ( $82 \times 10^9$  /L). He also had acute kidney injury (creatinine, 110  $\mu$ mol/L) but liver function test results were unremarkable. The chest X-ray showed consolidation over middle and lower zones of both lungs. The C-reactive protein level was 324 mg/L. Blood and sputum cultures grew *S pneumoniae* serotype 3; the tracheal aspirate for viral culture was positive for influenza B.

He developed severe respiratory failure on the

TABLE. Clinical details and other characteristics of the four patients\*

	Patient 1	Patient 2	Patient 3	Patient 4
<b>Characteristics</b>				
Onset of symptoms before admission (days)	4	3	3	7
Days of hospitalisation	40	50	2	4
Admission to ICU on day	1	1	2	1
Days of ICU stay	28	40	1	4
Age (years)	37	34	41	60
Septic shock	Yes	Yes	Yes	Yes
Acute kidney injury	Yes	Yes	Yes	Yes
<b>Microbiology</b>				
Initially isolated bacteria	<i>Streptococcus pneumoniae</i> serotype 3	<i>Streptococcus pyogenes</i>	<i>Streptococcus pneumoniae</i> serotype 3	<i>Streptococcus pneumoniae</i> serotype 3
Influenza A IF <sup>†</sup>	-ve	-ve	-ve	-ve
Influenza B IF <sup>†</sup>	-ve	-ve	+ve	-ve
Influenza A RT-PCR	-ve	-ve	-ve	NA
Influenza B RT-PCR	-ve	+ve	+ve	NA
4-Fold rise of influenza B titre	+ve	NA	NA	NA
Viral culture	NA	NA	NA	Influenza B
<b>Laboratory findings</b>				
Leukocyte count (x 10 <sup>9</sup> /L)	2.4	0.5	0.5	0.4
CRP (mg/L)	274	219	NA	324
Creatinine level (µmol/L)	177	230	335	110
Death on day	NA	NA	2	4
Advanced ventilatory support	NA	VV-ECMO	Nil	NA

\* ICU denotes intensive care unit, IF immunofluorescence, RT-PCR reverse transcription–polymerase chain reaction, CRP C-reactive protein, NA not applicable, VV-ECMO venovenous extracorporeal membrane oxygenation, +ve positive, and -ve negative

† The IF kit was Light Diagnostics DFA Kit for respiratory syncytial virus, flu A, B, parainfluenza 1, 2, 3, and adenovirus

day of admission and was intubated, mechanically ventilated, and admitted to the ICU for further management. He was treated with cefotaxime, azithromycin, penicillin, rifampicin, fluconazole, and vancomycin. He also received renal replacement therapy for acute kidney injury, but died 3 days after admission.

## Discussion

There are three types of influenza viruses, A, B, and C. Influenza A is more common and can cause major epidemics with loss of many lives, whereas influenza B infection is usually milder. According to statistics from the Centre for Health Protection, the incidence of influenza A was about 2 to 3 fold that of influenza B.<sup>3</sup>

Influenza is often complicated by severe chest infection, if there is co-infection by bacteria that commonly colonise the human upper respiratory tract. The usual causative infecting agent is *S pneumoniae*.<sup>4</sup> It can lead to significant morbidity

and mortality; there being 9 to 18 such cases per 1000 adults with invasive pneumonia.<sup>5</sup>

Influenza B with co-infections is rarely fatal. To the best of our knowledge, only one such case report of severe co-infection with influenza B and bacteria exists in the literature. Three women who were previously healthy had septic shock due to co-infection; one of whom died. All three patients were relatively young (39, 27, and 61 years).<sup>2</sup>

Pathophysiologically, such severe co-infection is due to several mechanisms. Thus, in animal models the influenza virus can damage respiratory tract epithelium and facilitate bacterial infection.<sup>6,7</sup> The virus can also alter and/or impair ciliary function of the epithelium.<sup>8</sup> In addition, it can change host immunity and inflammatory responses by impairing bacterial clearance or via the inflammatory cascade.<sup>9,10</sup>

The virulence of the pneumococcus is mainly due to the polysaccharide capsule, which provides protection from phagocytosis.<sup>11</sup> Pneumococci are classified into serotypes according to the structure

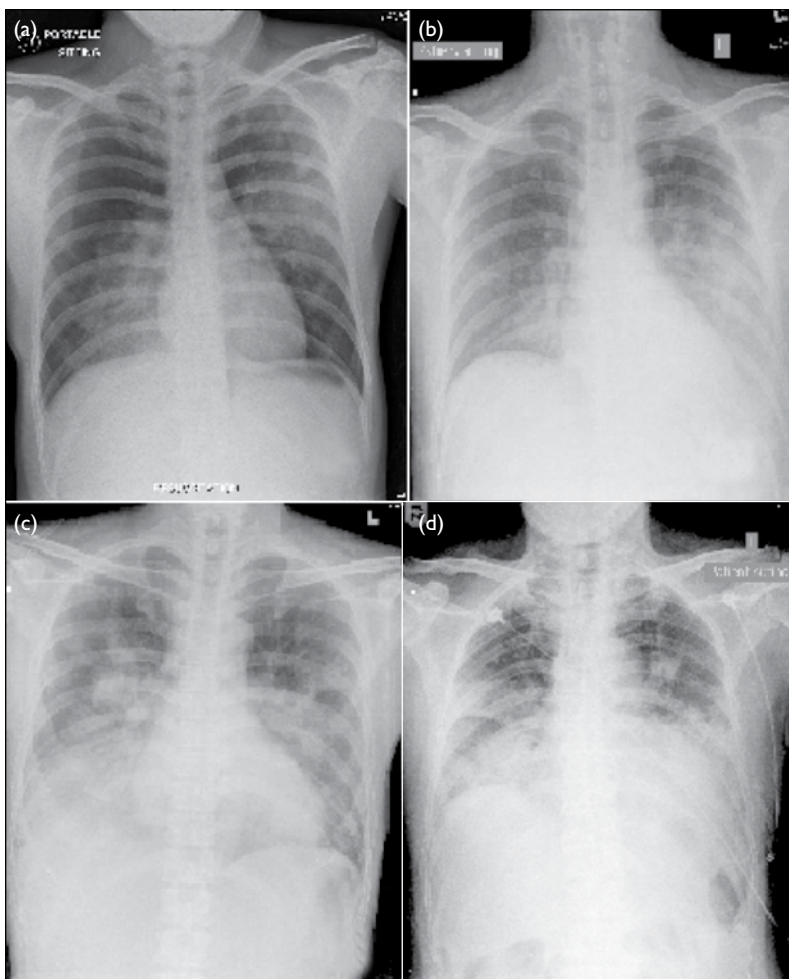


FIG. Chest X-rays on admission; all show bilateral pulmonary infiltrates (a) Patient 1, (b) patient 2, (c) patient 3, and (d) patient 4

of the capsule. Hitherto, 90 different serotypes have been described. In our report, three of the patients harboured pneumococci, all of which were of serotype 3, which is the prevalent serotype in Hong Kong. It accounts for 12.3 to 19.8% pneumococcal infections in the age-group of 18 to 64 years, and 14.2 to 20.6% of such infections in the age-group of >65 years. Serotype 3 is covered by the pneumococcal conjugate vaccine 13, which has been available in the market since 2010.<sup>12</sup>

Our cohort of four patients developed severe streptococcal infection secondary to influenza B infection, whose characteristics and clinical course are described in the Table. Also, their admission chest X-ray films revealed bilateral involvement from the onset (Fig). Worldwide, the more severe co-infection is usually caused by influenza A strain H3N2. Influenza B co-infections cause a milder disease but rarely lead to death.<sup>13</sup> Our patients were infected by influenza B, which may represent a new strain that warrants further investigation.

## Acknowledgements

The authors are grateful to Dr KY Lai, Dr KW Au Yeung, and Dr Anne Leung of Queen Elizabeth Hospital, as well as Dr KI Law of United Christian Hospital for their support and advisory help. Special thanks are due to Dr Christopher Lai of Microbiology Department of Queen Elizabeth Hospital for providing information of laboratory investigation.

## References

- McCullers JA. Insights into the interaction between influenza virus and pneumococcus. *Clin Microbiol Rev* 2006;19:571-82. [crossref](#)
- Aebi T, Weisser M, Bucher E, Hirsch HH, Marsch S, Siegemund M. Co-infection of influenza B and Streptococci causing severe pneumonia and septic shock in healthy women. *BMC Infect Dis* 2010;10:308. [crossref](#)
- Centre for Health Protection, Department of Health. Monthly summary tables of influenza virus isolation 2012. Available from: <http://www.chp.gov.hk/en/data/1/26/44/292/639.html>. Accessed Mar 2013.
- Michelow IC, Olsen K, Lozano J, et al. Epidemiology and clinical characteristics of community-acquired pneumonia in hospitalized children. *Pediatrics* 2004;113:701-7. [crossref](#)
- Mandell LA, Wunderink RG, Anzueto A, et al. Infectious Diseases Society of America/American Thoracic Society consensus guidelines on the management of community-acquired pneumonia in adults. *Clin Infect Dis* 2007;44(Suppl 2):S27-72. [crossref](#)
- McCullers JA, Regh JE. Lethal synergism between influenza virus and *Streptococcus pneumoniae*: characterization of a mouse model and the role of platelet-activating factor receptor. *J Infect Dis* 2002;186:341-50. [crossref](#)
- Plotkowski MC, Puchelle E, Beck G, Jacquot J, Hannoun C. Adherence of type I *Streptococcus pneumoniae* to tracheal epithelium of mice infected with influenza A/PR8 virus. *Am Rev Respir Dis* 1986;134:1040-4.
- Park K, Bakaletz LO, Coticchia JM, Lim DJ. Effect of influenza A virus on ciliary activity and dye transport function in the chinchilla eustachian tube. *Ann Otol Rhinol Laryngol* 1993;102:551-8.
- Echchannaoui H, Frei K, Schnell C, Leib SL, Zimmerli W, Landmann R. Toll-like receptor 2-deficient mice are highly susceptible to *Streptococcus pneumoniae* meningitis because of reduced bacterial clearing and enhanced inflammation. *J Infect Dis* 2002;186:798-806. [crossref](#)
- Dallaire F, Ouellet N, Bergeron Y, et al. Microbiological and inflammatory factors associated with the development of pneumococcal pneumonia. *J Infect Dis* 2001;184:292-300. [crossref](#)
- Luján M, Gallego M, Belmonte Y, et al. Influence of pneumococcal serotype groups on outcome in adults with bacteremic pneumonia. *Eur Respir J* 2010;36:1073-9. [crossref](#)
- Ho PL, Chui SS, Ang I, Lau YL. Serotypes and antimicrobial susceptibilities of invasive *Streptococcus pneumoniae* before and after introduction of 7-valent pneumococcal conjugate vaccine, Hong Kong, 1995-2009. *Vaccine* 2011;29:3270-5. [crossref](#)
- Thompson WW, Shay DK, Weintraub E, et al. Mortality associated with influenza and respiratory syncytial virus in the United States. *JAMA* 2003;289:179-86. [crossref](#)