

Mounier-Kuhn syndrome: an unusual underlying cause for chronic coughs and recurrent pneumonias

DOI: 10.12809/hkmj133760

Case

A 50-year-old female non-smoker presented to the Respiratory Clinic for chronic cough and recurrent pneumonias in January 2011. Auscultation revealed a clear chest, and a chest X-ray (CXR) showed a prominent trachea with an irregular outline (Fig 1). The lung fields also demonstrated bilateral reticulonodular changes, suspicious of infective changes.

Computed tomography (CT) of the thorax demonstrated an enlarged trachea, measuring 3.5 cm in sagittal dimension, with bizarre eccentric configurations and diverticula (Fig 2). Main bronchi were ectatic. Findings suggested type 2 Mounier-Kuhn syndrome. Bronchiectasis with centrilobular nodules in a tree-in-bud pattern were also noted in the right middle and lower lobes and lingular segment (Fig 3), suggestive of active endobronchial sepsis.

Bronchoscopy showed tracheobronchomegaly with diverticula, confirming the diagnosis of Mounier-Kuhn syndrome.

Kuhn syndrome. Bronchioalveolar lavage yielded *Mycobacterium chelonae*. The patient began anti-tuberculous treatment and her symptoms gradually improved.

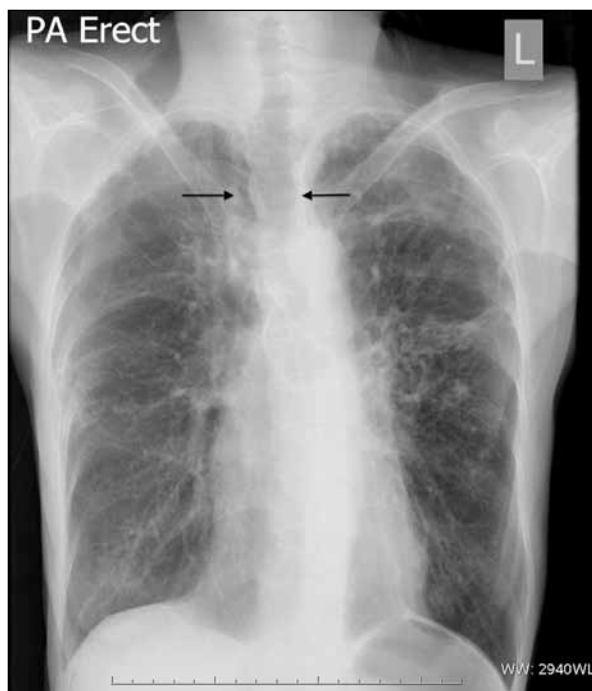

FIG 1. A chest radiograph shows a prominent trachea, with an irregular outline (arrows). Bilaterally, the lung field yields increased reticulonodular changes, suspicious of infective changes

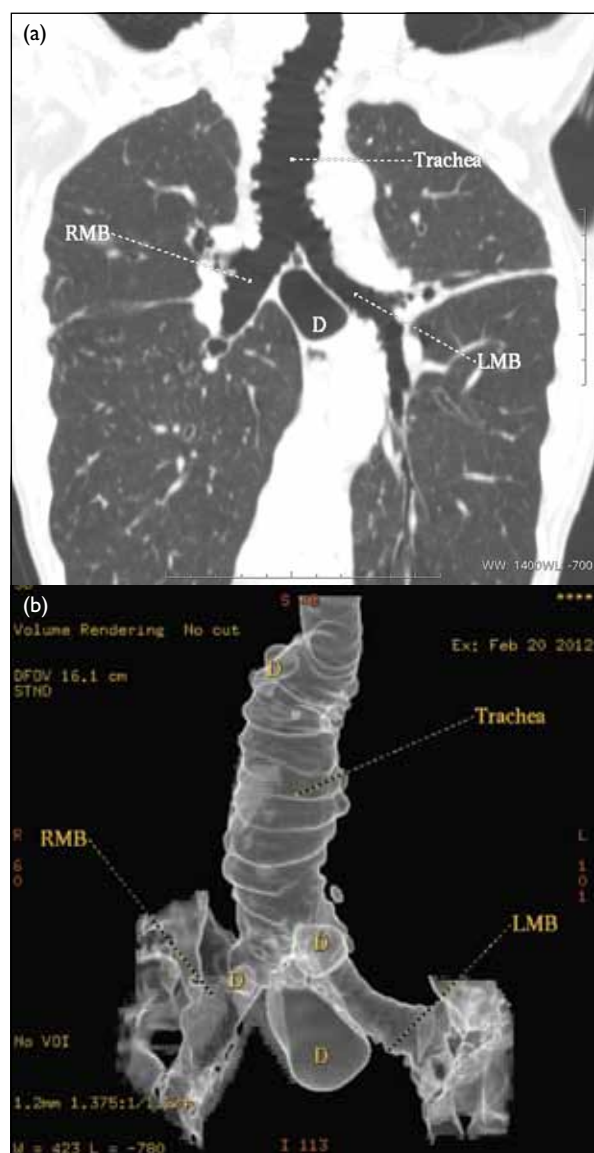


FIG 2. (a) Coronal reformatted computed tomography and (b) air surface 3-dimensional volume-rendering reformatted computed tomography of the thorax demonstrating an enlarged trachea, with bizarre eccentric configurations and a diverticulum. Bilaterally, the main bronchi are also ectatic. These findings are in keeping with type 2 Mounier-Kuhn syndrome. RMB denotes right main bronchus, LMB left main bronchus, and D diverticulum

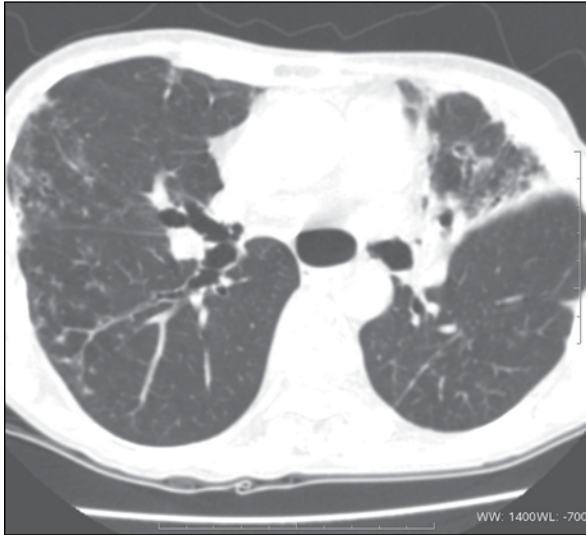

FIG 3. Computed tomography of the thorax reveals bronchiectasis, with centrilobular nodules in a tree-in-bud pattern at the right middle and lower lobes and the lingular segment, suggesting active endobronchial sepsis

Discussion

Mounier-Kuhn syndrome was first reported in 1932, and consists of marked tracheobronchomegaly in association with pneumonias. Any dimension of the trachea, right or left main bronchus exceeding 3.0 cm, 2.4 cm, or 2.3 cm, respectively suggests the diagnosis.¹

The syndrome has been classified into three subtypes.² In type 1, there is symmetrical enlargement of trachea and major bronchi. Type 2 manifests more obvious airway enlargement, bizarre eccentric configurations, and diverticulae. In type 3, the diverticulae or sacculations extend to the distal bronchi. The main problem associated with this disease is ineffective coughing as a consequence

of tracheobronchomegaly and impairment of mucociliary activity, leading to recurrent pneumonias.³

Radiologically, protrusion of redundant musculomembranous tissue between the cartilaginous rings results in an irregularly corrugated or scalloped appearance of the airway. Such an appearance has been described as diverticulosis of the trachea or bronchi. The resulting inefficient cough mechanism leads to retention of mucus causing recurrent pneumonias, emphysema, bronchiectasis, and lung parenchymal scarring.⁴

The differential diagnosis of Mounier-Kuhn syndrome includes disorders giving rise to fibrosis (sarcoidosis, interstitial pneumonias, cystic fibrosis). Marfan syndrome, Ehlers-Danlos syndrome, Kenny-Caffey syndrome, ataxia-telangiectasia, connective tissue diseases, Brachmann-de Lange syndrome, Bruton-type agammaglobulinemia, ankylosing spondylitis, cutis laxa, and light chain deposition disease are also associated with secondary tracheobronchomegaly.⁵

The diagnosis is missed in most patients with this syndrome; the case we report being one illustrative example. Despite long-term follow-up by physicians, Mounier-Kuhn syndrome had not been diagnosed until CT was performed. Since the abnormality can be easily overlooked on CXRs, CT should be considered for patients with unexplained chronic cough and/or recurrent pneumonias.

Janice JK Ip, MB, BS, FRCR

Email: jk.janice.ip@gmail.com

Peter KT Hui, MB, BS, FHKAM (Radiology)

Sonia HY Lam, MB, BS, FHKAM (Radiology)

Wendy WM Lam, MB, BS, FHKAM (Radiology)

MT Chau, MB, BS, FHKAM (Radiology)

Department of Radiology, Queen Mary Hospital, Pokfulam, Hong Kong

References

1. Shin MS, Jackson RM, Ho KJ. Tracheobronchomegaly (Mounier-Kuhn syndrome): CT diagnosis. *AJR Am J Roentgenol* 1988;150:777-9. [cross ref](#)
2. Himalstein MR, Gallagher JC. Tracheobronchiomegaly. *Ann Otol Rhinol Laryngol* 1973;82:223-7.
3. Celik B, Bilgin S, Yuksel C. Mounier-Kuhn syndrome: a rare cause of bronchial dilation. *Tex Heart Inst J* 2011;38:194-6.
4. Schwartz M, Rossoff L. Tracheobronchomegaly. *Chest* 1994;106:1589-90. [cross ref](#)
5. Kachhawa S, Meena M, Jindal G, Jain B. Case report: Mounier-Kuhn syndrome. *Indian J Radiol Imaging* 2008;18:316-8. [cross ref](#)