

Mad honey poisoning mimicking acute myocardial infarction

Sammy PL Chen 陳栢林
YH Lam 林英豪
Vember CH Ng 黃俊豪
FL Lau 劉飛龍
YC Sze 施婉珍
WT Chan 陳穎德
Tony WL Mak 麥永禮

We report a case of acute poisoning in a 48-year-old man who presented with chest pain, abdominal pain, dizziness, sweatiness, blurred vision, and severe hypotension after ingestion of honey. His electrocardiogram showed sinus bradycardia and transient ST elevation. He made a good recovery after treatment with atropine and close monitoring. Grayanotoxin was detected in his urine and the honey he ingested, which confirmed a diagnosis of mad honey poisoning. This is a condition prevalent in the Black Sea region around Turkey but rarely seen locally. Although mad honey poisoning is life-threatening, early use of atropine is life-saving. Such poisoning may present with ST elevation in the electrocardiogram and symptoms mimicking acute myocardial infarction. It is therefore essential for clinicians to recognise this unusual form of poisoning and avoid the disastrous use of thrombolytic therapy.

Introduction

Mad honey poisoning has a renowned history since ancient Greece. It is prevalent in several parts of the world, especially the Black Sea region of Turkey and less frequently elsewhere (North America, Korea, Nepal).¹⁻⁶ However, it is scarcely heard of in our locality. Its toxidrome is well-described and includes hypotension, bradycardia, respiratory depression, and impaired consciousness.^{1,7} The toxicity is caused by grayanotoxin, which is a diterpene present in the nectar of some members of the Ericaceae family.⁸ Herein, we describe the first local case of grayanotoxin poisoning related to the use of mad honey.

Case report

A 48-year-old man, with unremarkable past health, was admitted to the Accident and Emergency Department in a regional hospital with severe dizziness after ingestion of about 30 mL of honey in June 2012. The honey was provided by his friend who lived in close proximity to the Himalayas. The patient claimed to have consumed the honey for health purpose. He had been advised to take 3 to 5 mL at a time and had consumed it at the suggested dosage without any discomfort on three prior occasions. In the latest episode, he had consumed 30 mL. Whereupon, after about 1 hour he started experiencing severe dizziness, chest discomfort, sweating, coffee-ground vomiting, and blurred vision. He denied intake of other herbs or western medications.

On presentation in the emergency department, his blood pressure was 74/36 mm Hg, and his electrocardiogram (ECG) showed severe sinus bradycardia (heart rate, 37 beats/min) and diffuse ST elevation (Fig a). He was fully conscious and had satisfactory oxygen saturation on room air. Based on his symptoms and ECG, a provisional diagnosis of acute myocardial infarction was made by the emergency physician and cardiologist. He was given atropine 0.6 mg intravenously, fluid challenge, and aspirin 300 mg by mouth. Thrombolytic therapy was withheld because of his coffee-ground vomitus that indicated possible gastro-intestinal bleeding. In addition, in the resuscitation room there was no further chest discomfort. A few minutes after the injection of atropine, his heart rate normalised and there was resolution of the ECG abnormality (Figs b and c). He was then transferred to the Cardiac Care Unit for monitoring. Further investigations, including serial cardiac troponins, electrolytes, as well as renal and liver function test results, were all normal. Echocardiography revealed normal cardiac function and no structural abnormalities.

Acute poisoning as a cause of his clinical features was suspected. His serum cholinesterase level was 8383 U/L (reference range, 5320-12900 U/L), making organophosphate or carbamate poisoning unlikely. A urine specimen was collected on the day following his admission, and residual honey samples were sent for toxicology studies. Using a liquid chromatography–tandem mass spectrometry system (Applied Biosystems, Foster City [CA], US), grayanotoxin III was identified in the urine and grayanotoxin I, II,

Key words

Diterpenes; Dizziness; Honey/poisoning;
Hypotension; Toxins, biological

Hong Kong Med J 2013;19:354-6
DOI : 10.12809/hkmj133936

Toxicology Reference Laboratory,
Princess Margaret Hospital, Laichikok,
Hong Kong

SPL Chen, MRCP, FHKAM (Pathology)

YH Lam, MPhil

WT Chan, MRCP

TWL Mak, FRCPath, FHKAM (Pathology)

Hong Kong Poison Information Centre,
United Christian Hospital, Kwun Tong,
Hong Kong

VCH Ng, FHKCEM, FHKAM (Emergency Medicine)

FL Lau, FHKCEM, FHKAM (Emergency Medicine)

Department of Medicine, North District

Hospital, Sheung Shui, Hong Kong

YC Sze, MRCP, FHKAM (Medicine)

Correspondence to: Dr Tony WL Mak
Email: makwl@ha.org.hk

and III in the honey. The diagnosis of grayanotoxin poisoning related to mad honey consumption was therefore established. No other toxic plant alkaloids or drugs were found in these samples. The patient recovered fully and was discharged 2 days later.

Discussion

This is the first local case report of poisoning related to consumption of mad honey—honey containing grayanotoxins. Such poisoning is typically clustered in the Black Sea region of Turkey, where bees produce honey from the *Rhododendron* species like *R. ponticum* and *R. luteum*, and less commonly in parts of North America, Japan, Korea, New Zealand, and Nepal.^{1-4,9,10} Grayanotoxin—also known as andromedotoxin, rhodotoxin, or acetylandromedol—can also be found in other plants of the family of Ericaceae, like *Kalmia*, *Pieris*, and *Agarista* genera. Such poisoning can also occur after ingesting decoctions of such plants.¹¹ Our unit has also reported a local instance of grayanotoxin poisoning in a 57-day-old infant ingesting a bottle of milk prepared with a decoction of *Rhododendron simsii*.¹²

With more than 25 grayanotoxin isoforms identified, three (grayanotoxin I, II, and III) are of particular toxicological relevance, of which I and III are considered the principal toxic isomers,¹³ whilst grayanotoxin II appears to be less toxic. At the cellular level, toxic effect of grayanotoxin is mediated through its action on the voltage-gated sodium channel. Based on previous animal studies, grayanotoxin binds to the open sodium channel. Such binding modifies the channel's configuration to prevent its inactivation. Thus, the sodium channel remains depolarised and fails to repolarise. Overall, the diminished action potential appears to cause sinus node dysfunction.¹⁴ Besides, associated stimulation of afferent vagal nerve fibres causes tonic inhibition of the vasomotor centre, leading to reduced sympathetic output and vagal inhibition of sinus node function. In the central nervous system, neurons maintained at a state of depolarisation can result in a convulsion.¹⁷

The typical features of a toxidrome include hypotension, sinus bradycardia, nausea, vomiting, sweatiness, blurred vision, dizziness, and impaired consciousness. In severe cases, syncope, convulsions, life-threatening complete heart block, asystole, and respiratory failure may ensue.⁹ In a large pooled analysis of 69 patients by Gunduz et al,¹³ over 95% of all patients encounter hypotension and sinus bradycardia, and such typical features were also manifested by our case. However, these symptoms are not specific. Moreover, as in our case, grayanotoxin poisoning may also present with clinical features and ECG changes mimicking acute myocardial infarction.

疑似急性心肌梗塞的狂蜜病中毒

本文報告一名48歲男子急性中毒的情況。他服食蜂蜜後出現胸痛、腹痛、頭暈、出汗、視力模糊和嚴重低血壓。病人心電圖顯示竇性心搏過緩和短暫ST段抬高，接受過阿托品（atropine）治療並經密切監察後，病人恢復良好。及後發現他的尿液和所攝取的蜂蜜內均含有檜木毒素（grayanotoxin），證實是狂蜜病中毒。這種病在土耳其附近黑海周圍的地區很流行，本地卻很罕見。雖然狂蜜病中毒有機會危及生命，但早期使用阿托品能醫治此病。由於此類中毒可能出現心電圖ST段抬高，而其症狀可以與急性心肌梗塞相似，因此臨床醫生須認識這種不尋常的中毒形式，以免一旦使用溶栓治療而帶來不良後果。

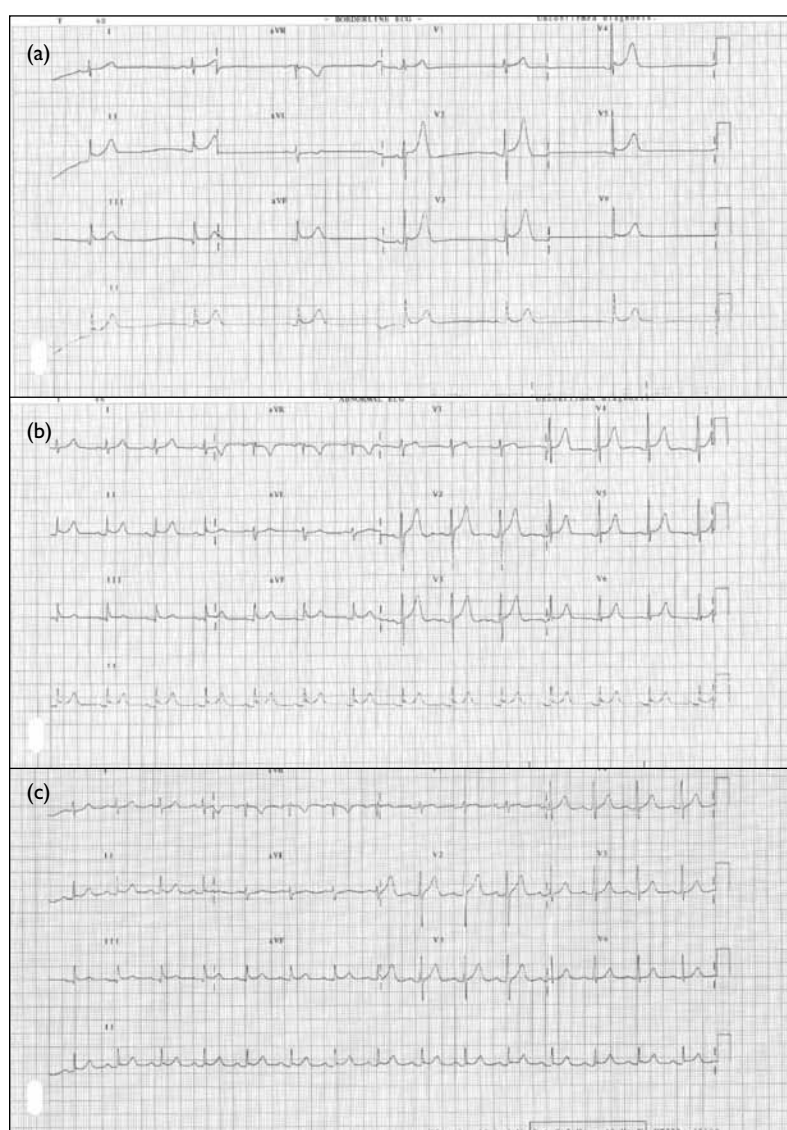


FIG. Serial electrocardiograms on admission and after therapy demonstrate (a) severe sinus bradycardia (heart rate, 37 beats/min) and mild ST-segment elevation over anterior leads; (b) resolution of bradycardia (heart rate, 80 beats/min) about 8 minutes later (after injection of atropine with fluid challenge); and (c) complete absence of ST-segment elevation about 30 minutes later

Fortuitously, our patient did not receive thrombolytic therapy due to the presence of coffee-ground vomitus. Apart from a primary cardiac event, other differential diagnoses include pesticide poisoning (organophosphate, carbamate) and pharmaceutical use of cholinergic agents (eg physostigmine, neostigmine, suxamethonium), which all have to be excluded.¹⁵ A normal cholinesterase level, together with a negative drug history and the absence of common drugs or other toxic plant alkaloids revealed by toxicology screening, also help exclude these alternative diagnoses.¹⁵

The toxic effects usually last no more than 24 hours, as grayanotoxins are rapidly metabolised and excreted.^{1,8} The latent period to symptoms is short, usually within 20 minutes to 3 hours post-ingestion,^{7,13} and symptom severity is dose-related.^{1,8}

For most case reports and series in the literature, the diagnosis was based solely on clinical features and exclusion of other possible causes (eg underlying heart disease, concomitant pesticide poisoning) without biochemical confirmation.^{2-4,10,16} With a toxicological analysis targeting the specific toxins and plant alkaloids, we can confirm the clinical suspicion and exclude other herb-related poisoning like aconite.¹⁷ Concerning acute management, intravenous atropine and fluid replacement can restore normal sinus rhythm and blood pressure, as illustrated by serial ECGs in this and previous case reports. Provided treatment is prompt, nowadays, fatalities are seldom encountered.

To conclude, clinicians should be aware of mad honey poisoning, and particularly its atypical myocardial infarction-like presentations.

References

- Gunduz A, Turedi S, Uzun H, Topbas M. Mad honey poisoning. *Am J Emerg Med* 2006;24:595-8. [crossref](#)
- Yilmaz O, Eser M, Sahiner A, Altintop L, Yesildag O. Hypotension, bradycardia and syncope caused by honey poisoning. *Resuscitation* 2006;68:405-8. [crossref](#)
- Dubey L, Maskey A, Regmi S. Bradycardia and severe hypotension caused by wild honey poisoning. *Hellenic J Cardiol* 2009;50:426-8.
- Jeong SM, Lee SH, Lim JS, et al. A case of systemic toxicity that occurred in an adult who intentionally ingested *rhododendron sclippenbashii* [in Korean]. *J Korean Soc Clin Toxicol* 2009;7:180-2.
- Kim C, Kim DS, Lee HW, Ahn YM, Uhm JH. A case of grayanotoxin intoxication presenting with mental changes and vomiting [in Korean]. *Korean J Pediatr Gastroenterol Nutr* 2008;11:223-5.
- Shrestha P, Vaidya R, Sherpa K. Mad honey poisoning: a rare case report of seven cases. *Nepal Med Coll J* 2009;11:212-3.
- Jansen SA, Kleerekooper I, Hofman ZL, Kappen IF, Stary-Weinzinger A, van der Heyden MA. Grayanotoxin poisoning: 'mad honey disease' and beyond. *Cardiovasc Toxicol* 2012;12:208-15. [crossref](#)
- Koca I, Koca AF. Poisoning by mad honey: a brief review. *Food Chem Toxicol* 2007;45:1315-8. [crossref](#)
- Gunduz A, Durmus I, Turedi S, Nuhoglu I, Ozturk S. Mad honey poisoning-related asystole. *Emerg Med J* 2007;24:592-3. [crossref](#)
- Ozhan H, Akdemir R, Yazici M, Gündüz H, Duran S, Uyan C. Cardiac emergencies caused by honey ingestion: a single centre experience. *Emerg Med J* 2004;21:742-4. [crossref](#)
- Kim AJ, Kim JS, Shin DW, Baek KJ, Han SB, Lee YJ. Grayanotoxin intoxication: 3 case reports [in Korean]. *J Korean Soc Emerg Med* 2000;11:372-7.
- Poon WT, Ho CH, Yip KL, et al. Grayanotoxin poisoning from *Rhododendron simsii* in an infant. *Hong Kong Med J* 2008;14:405-7.
- Gunduz A, Turedi S, Russell RM, Ayaz FA. Clinical review of grayanotoxin/mad honey poisoning past and present. *Clin Toxicol (Phila)* 2008;46:437-42. [crossref](#)
- Seyama I, Yamaoka K, Yakehiro M, Yoshioka Y, Morihara K. Is the site of action of grayanotoxin the sodium channel gating of squid axon? *Jpn J Physiol* 1985;35:401-10. [crossref](#)
- Gunduz A, Kalkan A, Turedi S, et al. Pseudocholinesterase levels are not decreased in grayanotoxin (mad honey) poisoning in most patients. *J Emerg Med* 2012;43:1008-13. [crossref](#)
- Yildirim N, Aydin M, Cam F, Celik O. Clinical presentation of non-ST-segment elevation myocardial infarction in the course of intoxication with mad honey. *Am J Emerg Med* 2008;26:108.e1-2.
- Chen SP, Ng SW, Poon WT, et al. Aconite poisoning over 5 years: a case series in Hong Kong and lessons towards herbal safety. *Drug Saf* 2012;35:575-87. [crossref](#)