

Subinguinal microsurgical varicocelectomy for male factor subfertility: ten-year experience

L Leung 梁凌
KL Ho 何崑崙
PC Tam 談寶雛
MK Yiu 姚銘廣

Objective To investigate the impact of subinguinal microsurgical varicocelectomy on semen parameters and pregnancy outcomes in couples with male factor subfertility.

Design Case series.

Setting Male Infertility Clinic in an academic institution in Hong Kong.

Patients The clinical records of 42 consecutive subfertile male patients who had subinguinal microsurgical varicocelectomy (from January 2000 to December 2009) were retrospectively reviewed. All the patients had a known history of subfertility and abnormalities in one or more semen parameters. Female subfertility factors were not addressed. Only grade 2 or higher clinically palpable varicoceles were operated on.

Main outcome measures Preoperative and postoperative semen analyses based on the World Health Organization criteria; the outcome measures included changes in semen parameters and whether a pregnancy ensued.

Results The mean age of patients and their spouses were 38 and 33 years, respectively. The mean duration of infertility was 4 years; 37 patients had primary infertility and five had secondary infertility. The mean (\pm standard deviation) sperm concentration improved from 12 ± 19 million/mL to 23 ± 29 million/mL following varicocelectomy ($P < 0.001$), the mean sperm motility improved from $26\% \pm 16\%$ to $32\% \pm 18\%$ ($P < 0.001$), and the mean normal morphology increased from $5\% \pm 7\%$ to $6\% \pm 6\%$ ($P < 0.001$). Postoperatively, 23 (55%) of the patients achieved pregnancy, 11 (26%) being spontaneous, 1 (2%) by intrauterine insemination, and 11 (26%) by in-vitro fertilisation. Among 20 patients with severe preoperative oligospermia (< 5 million/mL), statistically significant improvements occurred in postoperative mean sperm concentration, motility and morphology (all $P < 0.001$), and five (25%) of them achieved a spontaneous pregnancy. There was one intra-operative injury to the testicular artery with immediate repair and no testicular atrophy. Five (12%) of the patients had recurrences. No preoperative factors appeared predictive of a pregnancy ensuing.

Conclusions In couples with male infertility due to varicoceles, subinguinal microsurgical varicocelectomy was shown to improve sperm concentrations, motility and morphology, and the likelihood of a pregnancy. Spontaneous pregnancy was achieved in 25% of the couples in which the man had severe oligospermia.



A video of subinguinal microsurgical varicocelectomy is available at www.hkmj.org.

Key words

Azoospermia; Infertility, male; Microsurgery; Oligospermia; Varicocele

Hong Kong Med J 2013;19:334-40
DOI: 10.12809/hkmj133884

Department of Surgery, The University of Hong Kong, Queen Mary Hospital, Pokfulam, Hong Kong
L Leung, MB, BS, MRCS
KL Ho, FRCS (Urology) (Edin), FHKAM (Surgery)
PC Tam, FRCS (Urology) (Edin), FHKAM (Surgery)
MK Yiu, FRCS (Edin), FHKAM (Surgery)

Correspondence to: Dr KL Ho
Email: hkl218@hku.hk

New knowledge added by this study

- Subinguinal microsurgical varicocelectomy improves semen parameters and the likelihood of a pregnancy in subfertile couples.
- Spontaneous pregnancy can be achieved even in patients with severe preoperative oligospermia.
- Although the operation is technically demanding, the complication rate is low.

Implications for clinical practice or policy

- Such important local data can be used to counsel couples with varicocele-related subfertility.

Introduction

Varicocele is characterised by abnormal tortuosity and venous dilatation of the pampiniform plexus within the spermatic cord. It occurs in about 15% of all men and has been implicated as a causative factor in about a third of all couples with infertility.^{1,2} Many theories concerning the pathophysiological mechanism of this effect on fertility have been proposed. They include disordered testicular thermoregulation,^{3,4} hypoxia resulting from blood stagnation in the spermatic veins,⁵ reflux of adrenal metabolites,⁶ dilution of intratesticular substrates,⁷ and elevated levels of sperm-derived reactive oxygen species.⁸

The effect of varicocelectomy on male fertility is controversial; contemporary series have shown that after surgery there were significant improvements in semen quality in 50 to 70% of patients and spontaneous pregnancy was achieved in 30 to 40% of couples.⁹⁻¹⁷ The objective of our study was to investigate the effect of subinguinal microsurgical varicocelectomy on semen parameters and pregnancy outcomes in subfertile couples. All patients underwent subinguinal microsurgical varicocelectomy, which had been reported by Al-Said et al¹⁸ to have advantages (less recurrences and less hydrocele formation). Thus, we set out to provide local data for better counselling of infertile couples in Hong Kong as well as to address difficulties in predicting semen properties and pregnancy outcomes.

Methods

We retrospectively reviewed 42 consecutive patients who had subinguinal microsurgical varicocelectomy performed in our institution from January 2000 to December 2009. Infertility evaluation included obtaining a detailed history and performing a thorough physical examination. All varicoceles were evaluated and graded based on the Dubin grading system (grades I-III).¹⁹ Each patient had at least two semen samples analysed before surgery.

All the samples were analysed by the same laboratory according to the World Health Organization criteria.²⁰ The inclusion criteria for surgery were: exclusion of female infertility factors, grade 2 or higher varicocele, a known history of subfertility, and abnormalities in one to all aspects of semen parameters. Subinguinal microsurgical varicocelectomy was performed under general anaesthesia according to the technique described by Goldstein et al²¹ using a subinguinal 3-cm incision. The spermatic cord was slinged and dissected under 5-to-8-time microscopic magnification. The spermatic fascia was incised. The testicular artery and vas were safeguarded. All internal spermatic veins were

低位鼠蹊部的顯微精索靜脈結扎術醫治低生育力的男性：十年經驗分享

目的 探討低位鼠蹊部的顯微精索靜脈結扎術對於低生育力的男性在精液參數及妊娠結果的影響。

設計 病例系列。

安排 香港一所學術機構的男性不育診所。

患者 回顧從2000年1月至2009年12月期間進行低位鼠蹊部的顯微精索靜脈結扎術的42名低生育力男性的臨床資料。所有患者的生育能力較低，以及有一項或多於一項異常的精液參數。本研究未有考慮女性生育能力低的因素，並只為有二級或以上的精索靜脈曲張患者進行手術。

主要結果測量 根據世界衛生組織的標準作術前和術後的精液分析；測量指數包括精液參數的變化和是否受孕。

結果 患者及其配偶的平均年齡分別為38和33歲。不育的平均年期為4年。37人為原發性不育，另5人為繼發性不育。術後，平均（±標準差）精子數量由 $12 \times 10^6 / \text{mL} \pm 19 \times 10^6 / \text{mL}$ 增至 $23 \times 10^6 / \text{mL} \pm 29 \times 10^6 / \text{mL}$ ($P < 0.001$)，精子活動能力由 $26\% \pm 16\%$ 增至 $32\% \pm 18\%$ ($P < 0.001$)，而正常的精子形態則由 $5\% \pm 7\%$ 增至 $6\% \pm 6\%$ ($P < 0.001$)。最終，23人（55%）成功受孕，其中11人（26%）屬自發性、1人（2%）透過宮內授精、其餘11人（26%）通過體外受精。術前出現嚴重少精子症（即精子數量少於 $5 \times 10^6 / \text{mL}$ ）的20名患者中，其精子數量、活動能力和形態均明顯有改善 ($P < 0.001$)，其中5人（25%）成功自然受孕。一名患者在手術期間睪丸動脈有損傷，已立即施以修補，並無睪丸萎縮。5人（12%）有復發。研究結果發現並無任何術前因素可預測妊娠結果。

結論 因精索靜脈曲張引致不育的男性，低位鼠蹊部的顯微精索靜脈結扎術可提高精子數量、活動能力和形態，從而改善妊娠結果。出現嚴重少精子症的男性當中，有25%夫婦接受手術後可自然受孕。

ligated. Testicular lymphatics and the vasal vein were preserved. The testis was delivered and the external spermatic perforators were ligated. Gubernaculum veins were transfixed. The testis was re-positioned into the scrotum before wound closure. Outcome measures included changes in semen parameters and pregnancy in the partner. After varicocelectomy, each patient's semen samples were examined at a minimum of 3 months after the operation and at subsequent follow-up visits to our out-patient clinic. Physical examination was performed to detect any postoperative complications. For patients who defaulted follow-up, information on whether a pregnancy had ensued was obtained by phone interviews.

Statistical analysis was performed using the Statistical Package for the Social Sciences (Windows version 16.0; SPSS Inc, Chicago [IL], US). Peri-operative semen parameters were compared using

the Wilcoxon signed rank test. Univariate analysis was performed for potential predictors of pregnancy. One-way analysis of variance was performed for continuous variables and Fisher's exact test was performed for categorical variables.

Results

All 42 men in our series underwent left varicocelectomy. Their mean (\pm standard deviation [SD]) age was 38 ± 6 (range, 29-58) years. The mean

TABLE I. Patient demographics and clinical findings at presentation (n=42)

Patient demographics	Mean \pm standard deviation (range), or No. (%)		
Age at surgery (years)			
Men	38 \pm 6 (29-58)		
Women	33 \pm 4 (24-40)		
Testicular volume (mL)	16 (10-25)		
Laterality of varicocele			
Left	42 (100)		
Preoperative grade of varicocele			
Grade 2	17 (40)		
Grade 3	25 (60)		
Infertility			
Primary	37 (88)		
Secondary	5 (12)		
Duration of infertility (years)	4 \pm 2 (1-9)		
Previous infection			
Mumps	8 (19)		
Epididymo-orchitis	5 (12)		
Previous inguinal/scrotal operation	2 (5)		
Semen analysis (n=37)	Preoperative	Postoperative	P value
Sperm concentration (million/mL)	12 \pm 19	23 \pm 29	<0.001
Motility (%)	26 \pm 16	32 \pm 18	<0.001
Normal morphology (%)	5 \pm 7	6 \pm 6	<0.001
Duration of follow-up (months) [n=40]	12 (1-40)		
Pregnancy outcome (n=23)			
Spontaneous pregnancy	11 (48)		
Intrauterine insemination	1 (4)		
In-vitro fertilisation	11 (48)		
Time to pregnancy (months)	16 \pm 13 (1-38)		
Spontaneous pregnancy	15 \pm 13		
In-vitro fertilisation	15 \pm 12		
Duration of operation (mins)	159 \pm 50		
Complications	11		
Clavien classification			
Grade I			
Scrotal haematoma	1		
Wound infection	1		
Hydrocele	1		
Acute retention of urine	2		
Recurrence			
Grade 1	2		
Grade 2	3		
Grade IIIb			
Testicular artery injury	1		

age of their spouses was 33 ± 4 (range, 24-40) years. Preoperatively, 17 (40%) of the varicoceles were grade 2 and 25 (60%) were grade 3. The mean testicular volume was 16 (range, 10-25) mL (Table 1).

In all, 88% of these men presented with primary infertility and 12% had secondary infertility. The mean duration of infertility was 4 ± 2 (range, 1-9) years. Notably, 19% had a history of mumps, 12% had a history of epididymo-orchitis, and 5% had a history of inguinal or scrotal operation.

The preoperative mean sperm concentration was 12 ± 19 (range, 0-85) million/mL, the mean motility was $26\% \pm 16\%$ (range, 0-60%), and the mean percentage with normal morphology was $5\% \pm 7\%$ (range, 0-36%).

In all, 37 patients provided at least one postoperative semen sample 3 months after surgery. The mean sperm concentration improved from 12 ± 19 million/mL to 23 ± 29 million/mL following varicocelectomy ($P < 0.001$). The mean postoperative sperm motility increased significantly compared with pre-varicocelectomy values ($32 \pm 18\%$ vs $26 \pm 16\%$; $P < 0.001$), and the mean normal morphology percentage increased from $5 \pm 7\%$ to $6 \pm 6\%$ ($P < 0.001$).

Follow-up assessments were obtained in 40 (95%) of the patients after a mean of 12 (range, 1-40) months; two patients defaulted follow-up. Of the 42 couples, 23 (55%) achieved pregnancy, assuming that the two couples with defaulting men did not do so. Among the couples achieving pregnancy, 48% (11 of 23) achieved a spontaneous pregnancy, whereas 4% (1 of 23) and 48% (11 of 23) did so following intrauterine insemination and in-vitro fertilisation, respectively. The mean time to pregnancy (starting from the day of varicocelectomy) was 16 ± 13 (range, 1-38) months. The mean time to spontaneous pregnancy and pregnancy following in-vitro fertilisation were 15 ± 13 months and 15 ± 12 months, respectively. One patient achieved pregnancy by intrauterine insemination 38 months after surgery. The percentages of spontaneous pregnancies and all pregnancy events in relation to the time after the operation are shown in Kaplan-Meier curves (Figs 1 and 2).

The mean duration of operation was 159 ± 50 minutes. Surgery on one patient was complicated by intra-operative testicular artery injury, which was repaired immediately; no testicular atrophy was observed on follow-up. Five (12%) of the patients endured clinical recurrences (two had grade 1 and three had grade 2 recurrences). Other complications included a scrotal haematoma ($n=1$), wound infection ($n=1$), hydrocele ($n=1$), and acute retention of urine ($n=2$).

Subgroup analysis of semen specimens from 20 patients with severe oligospermia (defined as a sperm concentration < 5 million/mL) was performed (Table

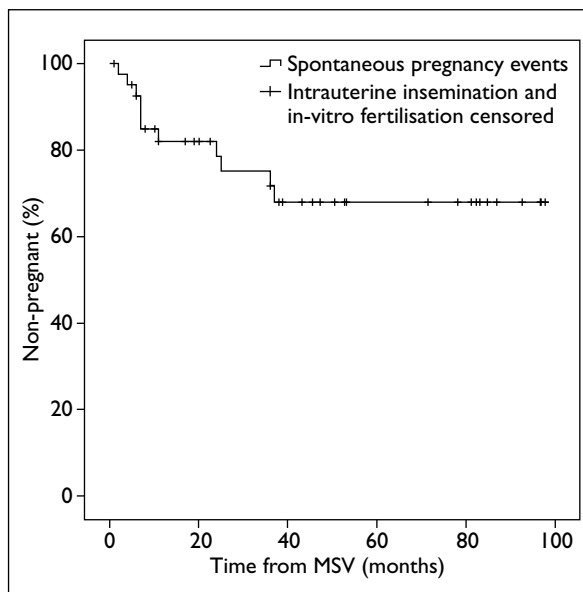


FIG 1. The percentage of spontaneous pregnancies in relation to time after microsurgical subinguinal varicocelectomy (MSV)

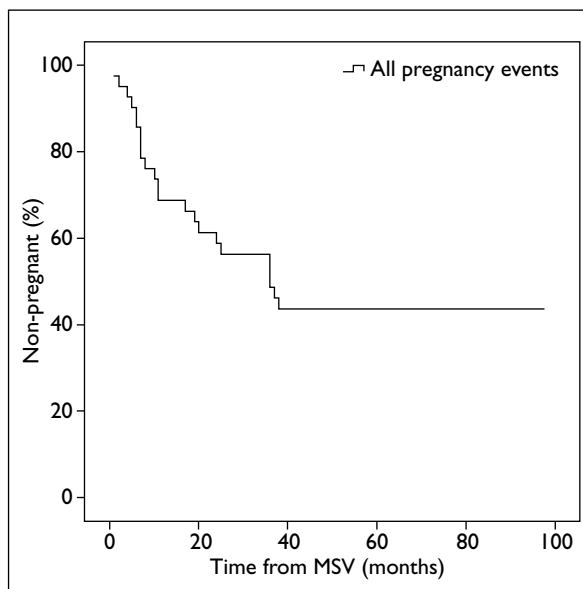


FIG 2. The percentage of all pregnancy events in relation to the time after microsurgical subinguinal varicocelectomy (MSV)

2). Statistically significant improvements occurred in mean sperm concentration, sperm motility, and sperm morphology (all $P < 0.001$). Moreover, 12 (60%) of the 20 couples achieved pregnancy, five of which were spontaneous, one following intrauterine insemination, and six after in-vitro fertilisation. In four patients who had preoperative azoospermia, postoperatively there was a return of sperm in ejaculates of two patients (the concentrations being 2-4 million/mL). There were 22 patients who had preoperative sperm counts of 5 million/mL or more, of whom 11 achieved pregnancy after surgery; six were spontaneous pregnancies and five after in-

TABLE 2. Subgroup analysis

Analysis	Mean \pm standard deviation (range), or No. (%)		
	Preoperative	Postoperative	P value
Severe oligospermia group (sperm concentration <5 million/mL) [n=20]			
Sperm concentration (million/mL)	2 \pm 1	6 \pm 7	<0.001
Motility (%)	22 \pm 19	29 \pm 21	<0.001
Normal morphology (%)	4 \pm 6	5 \pm 6	<0.001
Pregnancy outcome (n=12)			
Spontaneous pregnancy		5 (42%)	
Intrauterine insemination		1 (8%)	
In-vitro fertilisation		6 (50%)	
Azoospermia group (n=4)			
Postoperative return of sperm to ejaculate		2	
Remained azoospermia		2	
Pregnancy outcome (n=3)			
Intrauterine insemination		1 (33%)	
In-vitro fertilisation		2 (67%)	
Group with sperm concentration of \geq 5 million/mL (n=22)			
Sperm concentration (million/mL)	23 \pm 23	37 \pm 33	0.01
Motility (%)	30 \pm 11	36 \pm 14	0.08
Normal morphology (%)	6 \pm 8	6 \pm 6	0.76
Pregnancy outcome (n=11)			
Spontaneous pregnancy		6 (55%)	
In-vitro fertilisation		5 (45%)	

vitro fertilisation (Table 2). We found no statistically significant predictors of pregnancy (Table 3).

Discussion

Varicocele is the commonest surgically reversible cause of male infertility, though there is ongoing controversy over the benefits of varicocelectomy in this era of assisted reproduction.

Early series showed improvements in semen parameters and pregnancy rates after varicocelectomy. Schlesinger et al²² suggested that there is an improvement in semen quality in about 70% of men, and spontaneous pregnancy rates range from 30 to 60%. In the study by Marmar and Kim,²³ in which 186 patients underwent varicocelectomy, the 1-year pregnancy rate was 36%, compared with 16% for 19 medically treated men with varicoceles. However, there was a significant discrepancy in the sample size of the two groups. In the study by Madgar et al,¹⁶ 25 varicocelectomy patients achieved a 1-year pregnancy rate of 60%, whereas the rate was 10% for 20 men who were treated conservatively. In this study too, small sample size was a major limitation.

No published randomised controlled trials have sufficient sample sizes with appropriately selected patients. In a Cochrane review of eight randomised

TABLE 3. Putative predictors of pregnancy outcome

Factors evaluated	P value*
Age at surgery	
Men	0.11
Women	0.17
No. of years of subfertility	0.26
Testis volume on operated side	0.24
Follicle-stimulating hormone	0.70
Luteinising hormone	0.33
Testosterone	0.41
Preoperative best semen concentration	0.45
Preoperative best semen motility	0.29
Preoperative best semen WHO [†] morphology	0.91
Grade of operated side (1-3)	0.52
Type of infertility (primary/secondary)	0.89
Smoking status	0.40

* One-way ANOVA for continuous variables and Fisher's exact test for categorical variables were performed

† WHO denotes World Health Organization

controlled trials by Evers and Collins in 2004,²⁴ the reviewers concluded that varicocele repair for unexplained infertility could not be recommended.

However, their review appeared flawed because three studies that they included evaluated men with subclinical varicoceles and two included men with normal semen. The Cochrane review in 2006 by Ficarra et al²⁵ excluded the five randomised controlled trials that enrolled men with subclinical varicoceles or normal semen analysis, and reported a statistically significant increase in pregnancy rates in treated patients compared with control patients (36% vs 20%). However, their review entailed heterogeneous patients and methodologically poor statistical analysis. Their conclusion was that there was insufficient evidence to issue guidelines on varicocele treatment in subfertile couples.

Because of this controversy, two more meta-analyses have been conducted in recent years. Agarwal et al²⁶ included a total of 17 observational studies and randomised controlled trials, 10 varicocelectomy studies entailed microsurgery and seven involved high ligation. They demonstrated that after microsurgical varicocelectomy, sperm concentration increased by around 10 to 12 million/mL, motility increased by 10 to 12%, and morphology improved by 3%. However, they gave no data on numbers becoming pregnant. Marmar et al²⁷ included five studies with two randomised controlled trials and three observational studies. They selected infertile men with palpable varicoceles and abnormal sperm parameters. The odds of spontaneous pregnancy after varicocelectomy as opposed to conservative management were about 2.6 to 2.9. Their study suggested that in selected patients, varicocelectomy had beneficial effects on fertility.

Our case series consisted of patients that fulfilled all four criteria for varicocele treatment according to recommendations of the American Society for Reproductive Medicine.²⁸ The study

demonstrated that after varicocelectomy, there was a statistically significant improvement in mean sperm concentration (from 12 million/mL to 23 million/mL), motility (from 26 to 32%), and normal morphology (from 5 to 6%). In our study, 26% (11/42) of the couples achieved a spontaneous pregnancy. Even in patients with severe oligospermia, 25% of the couples achieved spontaneous pregnancy. As in other published series, our series did not identify any predictors of pregnancy.

Varicocelectomy has been shown to be advantageous compared to assisted reproduction, in terms of its cost-effectiveness. Schlegel²⁹ reported that in-vitro fertilisation or intra-cytoplasmic sperm injection was 3 times as costly as varicocele ligation. Penson et al³⁰ demonstrated that intrauterine insemination costs US\$50 000 more than varicocele repair per additional live birth. They concluded that immediate in-vitro fertilisation is never a cost-effective approach.

One limitation of our study was the small sample size of 42 patients. Secondly, five (12%) of the patients defaulted postoperative seminal analysis, and an additional 5% (2 patients) defaulted follow-up. We were unable to reach them because they had changed their phone numbers or moved.

Although subinguinal microsurgical varicocelectomy is a technically demanding procedure, our experience showed that it can improve semen parameters in subfertile male patients, whilst achieving a reasonable expectation of pregnancy with a relatively low complication rate. Our series provides important local data for the counselling of couples with varicocele-related subfertility, when they choose between varicocelectomy and assisted reproduction.

References

- Clarke BG. Incidence of varicocele in normal men and among men of different ages. *JAMA* 1966;198:1121-2. [crossref](#)
- Greenberg SH, Lipschultz LI, Wein AJ. Experience with 425 subfertile male patients. *J Urol* 1978;119:507-10.
- Zorgniotti AW, Macleod J. Studies in temperature, human semen quality, and varicocele. *Fertil Steril* 1973;24:854-63.
- Sofikitis N, Takahashi C, Nakamura I, Hirakawa S, Miyagawa I. Surgical repair of secondary right varicocele in rats with primary left varicocele: effects on fertility, testicular temperature, spermatogenesis, and sperm maturation. *Arch Androl* 1992;28:43-52. [crossref](#)
- Shafik A, Bedeir GA. Venous tension patterns in cord veins. I. In normal and varicocele individuals. *J Urol* 1980;123:383-5.
- Comhaire F, Vermeulen A. Varicocele sterility: cortisol and catecholamines. *Fertil Steril* 1974;25:88-95.
- Rajfer J, Turner TT, Rivera F, Howards SS, Sikka SC. Inhibition of testicular testosterone biosynthesis following experimental varicocele in rats. *Biol Reprod* 1987;36:933-7. [crossref](#)
- Hendin BN, Kolettis PN, Sharma RK, Thomas AJ Jr, Agarwal A. Varicocele is associated with elevated spermatozoa reactive oxygen species production and diminished seminal plasma antioxidant capacity. *J Urol* 1999;161:1831-4. [crossref](#)
- Stewart BH. Varicocele in infertility: incidence and results of surgical therapy. *J Urol* 1974;112:222-3.
- Cockett AT, Urry RL, Dougherty KA. The varicocele and semen characteristics. *J Urol* 1979;121:435-6.
- Nilsson S, Edvinsson A, Nilsson B. Improvement of semen and pregnancy rate after ligation and division of internal spermatic vein: fact or fiction? *Br J Urol* 1979;51:591-6. [crossref](#)

12. Newton R, Schindeld JS, Schiff I. The effect of varicocelectomy on sperm count, motility and conception rate. *Fertil Steril* 1980;34:250-4.
13. Vermeulen A, Vandeghe M. Improved fertility after varicocele correction: fact or fiction? *Fertil Steril* 1984;42:249-56.
14. Ragoth JC, Unger C, DaRunga D, et al. Long-term results of varicocelectomy. *Urol Int* 1992;48:327-31.
15. Breznik R, Vlajsavljević V, Borko E. Treatment of varicocele and male fertility. *Arch Androl* 1993;30:157-60. [crossref](#)
16. Madgar I, Weissenberg R, Lunenfeld B, Karasik A, Goldwasser B. Controlled trial of high spermatic vein ligation for varicocele in infertile men. *Fertil Steril* 1995;63:120-4.
17. Nieschlag E, Hertle L, Fischdick A, Abshagen K, Behre HM. Update on treatment of varicocele: counseling as effective as occlusion of the vena spermatica. *Hum Reprod* 1998;13:2147-50. [crossref](#)
18. Al-Said S, Al-Naimi A, Al-Ansari A, et al. Varicocelectomy for male infertility: a comparative study of open, laparoscopic and microsurgical approaches. *J Urol* 2008;180:266-70. [crossref](#)
19. Dubin L, Amelar RD. Varicocelectomy: 986 cases in a twelve-year study. *Urology* 1977;10:446-9. [crossref](#)
20. WHO. Laboratory manual for the examination of human semen and sperm—cervical mucus interaction. Cambridge: Cambridge University Press; 1992.
21. Goldstein M, Gilbert BR, Dicker AP, Dwosh J, Gnecco C. Microsurgical inguinal varicocelectomy with delivery of the testis: an artery and lymphatic sparing technique. *J Urol* 1992;148:1808-11.
22. Schlesinger MH, Wilets IF, Nagler HM. Treatment outcome after varicocelectomy. A critical analysis. *Urol Clin North Am* 1994;21:517-29.
23. Marmar JL, Kim Y. Subinguinal microsurgical varicocelectomy: a technical critique and statistical analysis of semen and pregnancy data. *J Urol* 1994;152:1127-32.
24. Evers JL, Collins JA. Surgery or embolisation for varicocele in subfertile men. *Cochrane Database Syst Rev* 2004;CD000479.
25. Ficarra V, Cerruto MA, Ligouri G, et al. Treatment of varicocele in subfertile men: The Cochrane Review—a contrary opinion. *Eur Urol* 2006;49:258-63. [crossref](#)
26. Agarwal A, Deepinder F, Cocuzza M, et al. Efficacy of varicocelectomy in improving semen parameters: new meta-analytical approach. *Urology* 2007;70:532-8. [crossref](#)
27. Marmar JL, Agarwal A, Prabakaran S, et al. Reassessing the value of varicocelectomy as a treatment for male subfertility with a new meta-analysis. *Fertil Steril* 2007;88:639-48. [crossref](#)
28. The Practice Committee of the American Society for Reproductive Medicine. Report on varicocele and infertility. Available from: <http://www.asrm.org>. Accessed 26 Jul 2012.
29. Schlegel PN. Is assisted reproduction the optimal treatment for varicocele-associated male infertility? A cost-effectiveness analysis. *Urology* 1997;49:83-90. [crossref](#)
30. Penson DF, Paltiel AD, Krumholz HM, Palter S. The cost-effectiveness of treatment for varicocele related infertility. *J Urol* 2002;168:2490-4. [crossref](#)