

A young woman with mucocutaneous pigmentation and intestinal polyps

DOI: 10.12809/
hkmj133753

A 26-year-old woman was regularly followed up in a gastro-intestinal out-patient clinic. Since early childhood, she was noted to have hyperpigmented lesions over the perioral region (Fig 1a) and fingers (Fig 1b), and a history of small intestinal intussusception due to polyps that was treated by surgery when she was 12 years old. Endoscopic assessment revealed multiple gastric polyps (Fig 1c) and a colonic hamartoma (Fig 1d). The family history was otherwise unremarkable for gastro-intestinal disease or malignancy.

Questions

1. What is the diagnosis?
2. Is genetic testing available for this disease?
3. How should the patient's problem be managed?

Answers

1. Peutz-Jeghers syndrome (PJS).

This rare autosomal dominant polyposis syndrome has a point prevalence of 1 in 50 000 to 200 000 live-births, characterised by multiple gastro-intestinal hamartomatous polyps, mucocutaneous pigmentation, and an increased cancer risk. It is caused by germline mutation of the serine-threonine kinase 11 (*STK11*) gene.¹ About half of the patients are simplex cases due to de-novo mutations and have no

family history.

The clinical manifestations are age-dependent. In infancy, more than 95% of the patients have mucocutaneous pigmented lesions over the perioral, perianal and/or digital regions that may fade after puberty. In childhood, polyp-related symptoms like gastro-intestinal bleeding, anaemia, abdominal pain due to intussusception, obstruction, or infarction become predominant.

The histology of Peutz-Jeghers (PJ) polyps is distinctive, there being a polypoid, hyperplastic mucosa, and bands of arborising smooth muscle. The clinical diagnosis of PJS can be made when patients meet one of the following criteria²:

- (1) Two or more histologically confirmed PJ polyps;
- (2) Any number of PJ polyps with a positive family history of PJS in close relative(s);
- (3) Characteristic mucocutaneous pigmentation with a positive family history of PJS in close relative(s); or
- (4) Any number of PJ polyps with characteristic mucocutaneous pigmentation.

2. In an appropriate clinical setting, testing for the *STK11* gene can be undertaken. By sequencing and gene dosage analysis (like the multiplex ligation-dependent probe amplification method), pathogenic mutations can be identified in almost all clinically diagnosed PJS patients with a positive family history and 90% of those without a family history. Apart from confirming the diagnosis, it is useful for pre-symptomatic testing of other at-risk family members, as well as to enable prevention by means of obtaining a prenatal or preimplantation genetic diagnosis. Therefore, genetic testing should be considered for all PJS patients (Fig 2).

3. The relative cancer risk for PJS patients is 9 to 18 times higher than in the general population,³ and particularly for luminal gastro-intestinal cancers and for breast cancers. The risk is even higher in persons age over 50 years. Therefore regular gastro-intestinal screening and tumour surveillance is essential for all PJS patients, not only for early detection of tumour, but also to prevent polyp-related complications. The recommendations on surveillance based on the best current evidence are summarised in the Table.²

Endoscopic polypectomy should be performed for polyps larger than 1 cm. Large small intestinal polyps can be removed by balloon enteroscopy or sometimes surgery. Although no pharmacological treatment or prophylaxis is recommended for PJS,

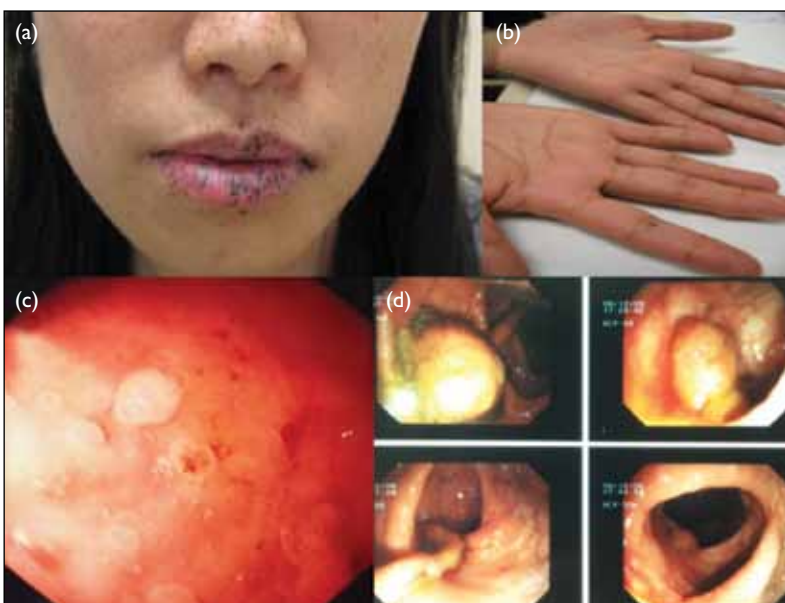

FIG 1. Clinical presentation of the patient

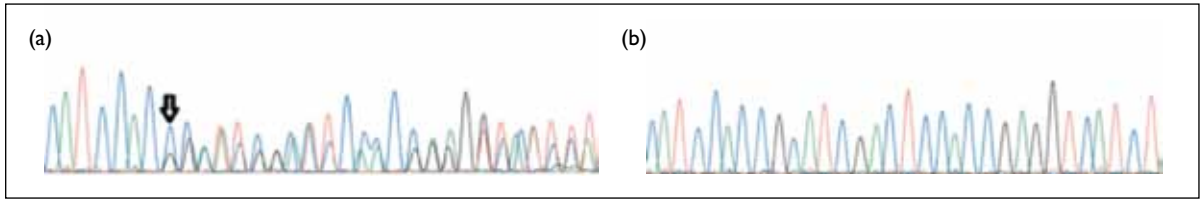


FIG 2. DNA sequence chromatographs of the patient
 (a) Heterozygous c.82delC mutation in exon 1 of *STK11* gene was detected. (b) Wide-type sequence for comparison

TABLE. Recommendations for surveillance and follow-up for patients with Peutz-Jeghers syndrome²

System	Examination*	Results
General	Annual physical examination; annual blood test (include complete blood count and liver function test)	-
Gastro-intestinal	Baseline OGD/colonoscopy at the age of 8 years	Polyps detected: repeat 3 yearly till 50 years old No polyps detected: repeat at the age of 18 years, then 3 yearly till 50 years old
	VCE every 3 yearly from the age of 8 years	-
	Colonoscopy every 1-2 yearly after 50 years old	-
Reproductive	For males: annual testicular examination from birth till 12 years old	Ultrasound testis if abnormality detected
	For females: cervical smear with liquid-based cytology every 3 years after the age of 25 years	-
Breast (female)	Monthly examinations from the age of 18 years	-
	Annual breast MRI from 25 to 50 years old; annual mammography thereafter	-

* OGD denotes oesophagogastroduodenoscopy, VCE video capsule endoscopy, and MRI magnetic resonance imaging

therapeutic agents that inhibit the mTOR and COX2 pathways are potential drugs that might modulate and slow down the development of PJ polyps, and are currently under study in experimental trials. The pigmented skin lesion has no malignant potential as it is a melanin deposit. For cosmetic purposes, intense pulsed light and laser therapy may be useful for selected patients.

Finally, as PJS is a hereditary polyposis syndrome, genetic evaluation and counselling for patients and at-risk family members by a clinical geneticist is indicated.

HM Luk, FHKAM (Paediatrics)
 Email: luksite@gmail.com
Ivan FM Lo, FHKAM (Paediatrics)
 Clinical Genetic Service, Department of Health, Hong Kong
Kelvin MC Yu, FHKAM (Medicine)
 Department of Medicine
 Tuen Mun Hospital, Tuen Mun, Hong Kong
Tony MF Tong, MSc
Stephen TS Lam, FHKAM (Paediatrics)
 Clinical Genetic Service, Department of Health, Hong Kong

References

1. Jenne DE, Reimann H, Nezu J, et al. Peutz-Jeghers syndrome is caused by mutations in a novel serine threonine kinase. *Nat Genet* 1998;18:38-43. [cross ref](#)
2. Beggs AD, Latchford AR, Vasen HF, et al. Peutz-Jeghers syndrome: a systematic review and recommendations for management. *Gut* 2010;59:975-86 [cross ref](#).
3. van Lier MG, Westerman AM, Wagner A, et al. High cancer risk and increased mortality in patients with Peutz-Jeghers syndrome. *Gut* 2011;60:141-7. [cross ref](#)