

Sonographic characteristics of hepatic schistosomiasis: a rare cause of diffuse liver parenchymal disease

DOI: 10.12809/hkmj133600

Case history

A 68-year-old man with a history of hypertension and ischaemic heart disease was admitted for congestive heart failure in May 2011. The patient had pancytopenia and underwent an abdominal ultrasound to look for splenomegaly. Ultrasound showed that the liver echotexture was diffusely heterogeneous. The walls of portal venules were hyperechoic and thickened, suggestive of periportal fibrosis (Fig 1). Multiple thickened echogenic septae were noted outlining polygonal areas of relatively normal-appearing liver parenchyma giving a mosaic appearance (Fig 2). Imaging features were characteristic of hepatic schistosomiasis. The spleen was not enlarged. The kidneys showed age-related parenchymal changes only. Regrettably, the patient defaulted follow-up and therefore he did not undergo confirmatory serological testing or treatment.

Discussion

Hepatic schistosomiasis is an uncommon condition in developed countries, but remains the commonest cause of hepatic fibrosis worldwide. It was first

described by Theodor Bilharz in 1851, and is therefore also known as bilharziasis.¹ This condition is a parasitic infestation caused by the blood fluke *Schistosoma haematobium*, a freshwater snail being a necessary intermediate host. Humans are infected when larval forms released by such snails penetrate skin during contact with infected water, and develop into adult schistosomes in the body. The adult worms live in blood vessels (mostly veins), where the females release eggs, some of which are passed out in faeces or urine to continue the parasitic life cycle. Schistosomiasis is considered an endemic disease that is more commonly encountered in agricultural workers and persons exposed to infested water during recreational activities.

Typical sonographic appearances include hepatomegaly with an irregular contour and a mosaic/tortoise-shell pattern of liver echotexture, characterised by multiple thickened echogenic septa outlining polygonal areas of normal-appearing liver parenchyma.² Periportal fibrosis is another feature and manifests as thickened walls of portal venules also known as 'clay-pipestem fibrosis'. Ultrasonography reveals as an anechoic portal vein surrounded by an echogenic mantle of fibrous tissue. Findings consistent with complications (portal hypertension and cirrhosis) may also be present. Similar imaging

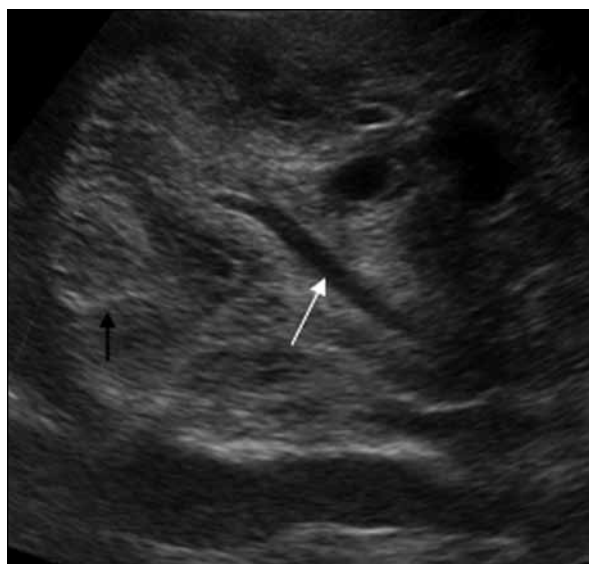

FIG 1. Grey-scale trasabdominal ultrasound (transverse scan) showing mosaic pattern/tortoise-shell pattern of hepatic schistosomiasis. Note the multiple thickened echogenic septa (black arrow) outlining polygonal areas of relatively normal-appearing liver parenchyma, and the portal vein (white arrow) surrounded by echogenic periportal fibrosis

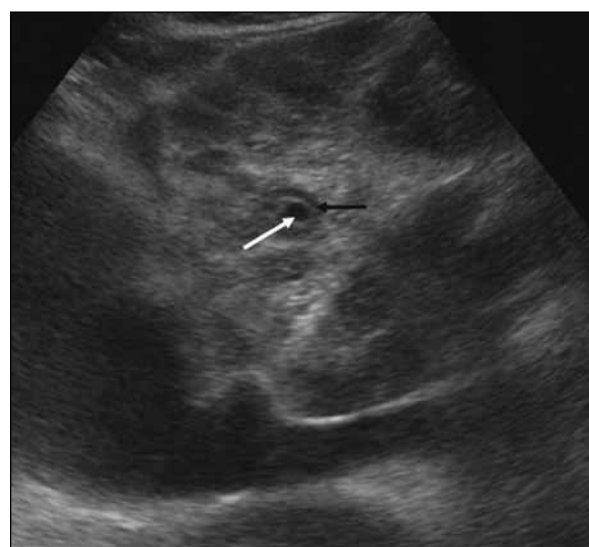


FIG 2. Grey-scale trasabdominal ultrasound (longitudinal scan) revealing 'clay-pipestem fibrosis'. Note the anechoic portal vein (white arrow) surrounded by an echogenic mantle of fibrous tissue (black arrow)

features were detected in our case. Certainly, other causes of cirrhosis also need to be excluded. Surface nodularities and regenerating nodules are typically absent in the liver schistosomiasis, which mainly leads to liver shrinkage, whereas periportal and perivascular thickening and fibrosis is said to be more common than in other causes of cirrhosis.

Assessment of the urinary tract is also important in suspected cases, which may be complicated by bladder and ureteric wall calcification, a contracted bladder and hydroureteronephrosis. In conclusion, as noted in this case, hepatic schistosomiasis is a rare

diffuse liver parenchymal disease with characteristic ultrasound findings, namely a mosaic pattern of liver echotexture and periportal fibrosis.

Simon Wong, MB, BS

Bhawan K Paunipagar, MD

Darshana D Rasalkar, FRCR

Email: drdarshanab@gmail.com

Department of Imaging and Interventional Radiology

The Chinese University of Hong Kong

Prince of Wales Hospital

Shatin, Hong Kong

References

1. Tan SY, Ahana A. Theodor Bilharz (1825-1862): discoverer of schistosomiasis. *Singapore Med J* 2007;48:184-5.
2. Ahuja AT, Griffith JF, Wong KT, et al. Diagnostic imaging: ultrasound. Salt Lake City: Amirsys; 2007: Section1.1-16.