

# Degos' syndrome complicated by bowel perforation: focus on radiological findings

Jessie TH Yeung 楊芷珩  
Johnny KF Ma 馬嘉輝  
Alfred WT Yung 翁維德

We describe a 50-year-old man who first presented with multiple skin lesions which were characteristic of Degos' syndrome. The patient developed multiple episodes of abdominal pain. Some episodes resolved with conservative management, for others he underwent urgent operations for bowel perforations. The patient subsequently underwent extensive small bowel resection, but further systemic deterioration ensued and he died. The imaging findings of Degos' syndrome and the implications of pneumatosis intestinalis and pneumoperitoneum are discussed.

## Introduction

Degos' syndrome is a rare disorder which can have benign cutaneous or fatal systemic forms. This is a report on a patient with Degos' syndrome, whose fatal outcome was related to bowel perforation. To the best of our knowledge, there have been very few reports on the radiological findings of this rare disease. In our patient, subtle findings indicative of the perforation site, pneumoperitoneum, and pneumatosis intestinalis were demonstrated and are discussed in this report.

## Case report

A 50-year-old man first presented to a dermatologist with multiple skin lesions in 2008. Skin biopsy showed arterial thromboses with ischaemic changes. Degos' syndrome (malignant atrophic papulosis) was diagnosed. Since other causes of arterial thrombosis can also produce this biopsy result, further investigations were carried out to look for conditions such as systemic lupus erythematosus. His blood was negative for anti-nuclear antibodies, anti-neutrophil cytoplasmic antibodies, anti-cardiolipin immunoglobulin G, and lupus anticoagulant were negative; his clotting profile (including serum protein C and S levels) was normal.

The patient experienced recurrent abdominal pains with fever, which resulted in multiple hospital admissions over 2 years after he first presented. Some episodes resolved with conservative management (entailing antibiotics), for others he received operative management.

Computed tomography (CT) performed during his first admission for abdominal pain showed small pockets of pneumoperitoneum adjacent to ileal loops (Fig 1) and tiny intramural gas pockets within the ileal wall, which were suspicious of pneumatosis intestinalis. Mild small bowel dilation was noted. Proximal branches of the mesenteric vasculature were patent. The patient's symptoms tended to resolve after taking antibiotics. Aspirin, clopidogrel, and prednisolone were added to his treatment regimen.

During patient's second admission for abdominal pain (over the left lower quadrant), urgent CT revealed a small bowel perforation, for which laparoscopic repair was performed.

Computed tomography performed during an admission for abdominal pain 3 months later again showed tiny pockets of pneumoperitoneum near small bowel loops and pneumatosis intestinalis in the ascending colon, and stranding and fluid were evident in the right paracolic gutter. However, at operation there was a clean peritoneum, a dense adhesion of small bowel to a previous midline wound, and mild small bowel wall thickening that looked healthy. The patient's pain was controlled using analgesics. During a subsequent admission for abdominal pain 3 months later, CT showed evidence of peritonitis with peritoneal enhancement, in addition to nodular thickening of the omentum (Fig 2), but there was no pneumoperitoneum. The patient was treated conservatively with antibiotics.

The patient was readmitted for abdominal pain 1 day after discharge, whereupon radiographs demonstrated pneumoperitoneum. Urgent laparotomy showed marked

### Key words

Intestinal perforation;  
Malignant atrophic papulosis;  
Pneumatosis cystoides intestinalis;  
Pneumoperitoneum; Skin diseases,  
vascular

*Hong Kong Med J* 2013;19:174-7

Department of Diagnostic Radiology,  
Princess Margaret Hospital, Laichikok,  
Hong Kong

JTH Yeung, MB, ChB, FRCR  
JKF Ma, FHKCR, FHKAM (Radiology)  
AWT Yung, FHKCR, FHKAM (Radiology)

Correspondence to: Dr Jessie Yeung  
Email: jezzyeung@gmail.com

adhesions over the whole abdomen, multiple 3- to 5-mm small bowel perforations walled off by adhesions, and patchy gangrenous and ischaemic changes along the small bowel. Small bowel resection for gangrene with anastomosis and repair of perforation sites were performed. Postoperatively, the patient was initially stable, but later deteriorated and underwent two more operations as multiple new small bowel perforations were noted as well as leakage from previously repaired perforations and a new sigmoid colon perforation. Further small bowel resection was carried out; only 30 cm of small bowel remained after the very last operation. The patient's general condition deteriorated and was associated with sepsis, including pneumonia. Palliative care was offered to make the patient comfortable, until he developed shock and died.

## Discussion

### Degos' syndrome

Kohlmeier described malignant atrophic papulosis in his article 'Multiple Hautnekrosen bei Thromboangiitis obliterans' in 1941; this same disease entity was described by Degos in 1942.<sup>1</sup> Degos' syndrome is an occlusive small-vessel vasculopathy which causes tissue infarct,<sup>1</sup> but its aetiology is unknown and it affects all ages.<sup>1</sup>

Degos' syndrome has a benign cutaneous form and a fatal systemic form.<sup>2</sup> Skin lesions may manifest as erythematous papules which heal to leave scars with white atrophic centres.<sup>1</sup> Light microscopy findings of skin lesions may demonstrate wedge-shaped zones of necrosis extending from the epidermis to the reticular dermis, thickened vessel walls, and thromboses.<sup>3</sup> Gastro-intestinal lesions may show identical histological findings, and complications such as bowel perforation and peritonitis are often fatal within 2 to 3 years.<sup>4</sup> Medical treatments such as antiplatelet drugs have been given, but there is no definite effective treatment.<sup>1,5</sup>

The gastro-intestinal tract is affected in 50% of patients with systemic Degos' syndrome.<sup>1</sup> Other systems such as the central nervous system and renal system can also be affected, as demonstrated by the cases described by McFarland et al and Schade et al.<sup>6,7</sup>

### Gastro-intestinal involvement in Degos' syndrome

Both the patients described by Kohlmeier and Degos in 1941 and 1942 died from bowel perforation.<sup>8</sup> Kim et al<sup>9</sup> described a case of Degos' syndrome with gastro-intestinal involvement in a 59-year-old woman, with a history of multiple skin lesions and small-bowel perforation treated by surgery. The patient developed generalised abdominal pain, and explorative laparotomy revealed multifocal ischaemic changes in the small bowel with perforations. Postoperatively, the

## Degos綜合症併發小腸穿孔：放射性結果的重點分析

本文報告一名50歲男性全身多處有丘疹，證實為Degos綜合症（惡性萎縮性丘疹病）的症狀。病人有多次腹痛，部分的腹痛以保守療法處理，其餘的則接受緊急小腸穿孔術。最終病人接受大幅度小腸切除的手術，但因有其他系統性惡化而最終不治。本文續討論有關Degos綜合症，以及腸氣囊腫病和腹腔積氣的放射性結果。

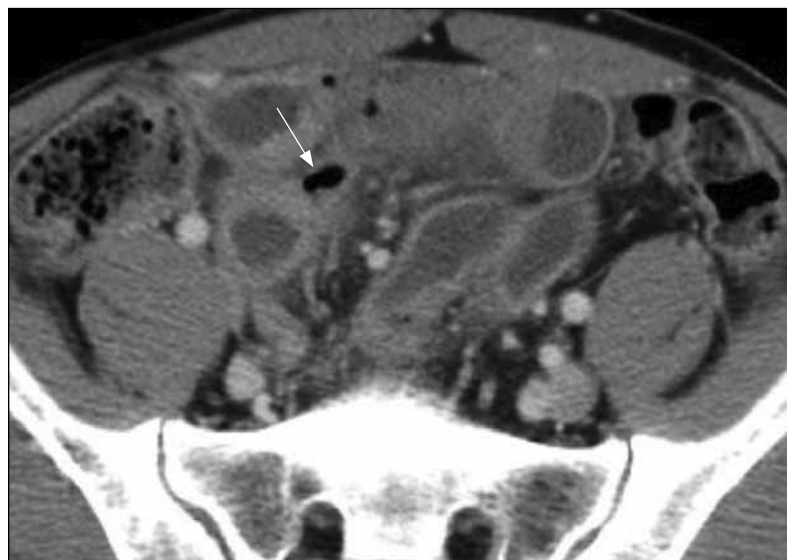


FIG 1. Computed tomography of the abdomen and pelvis with intravenous contrast, demonstrating a small extraluminal gas pocket adjacent to ileal loops (arrow)

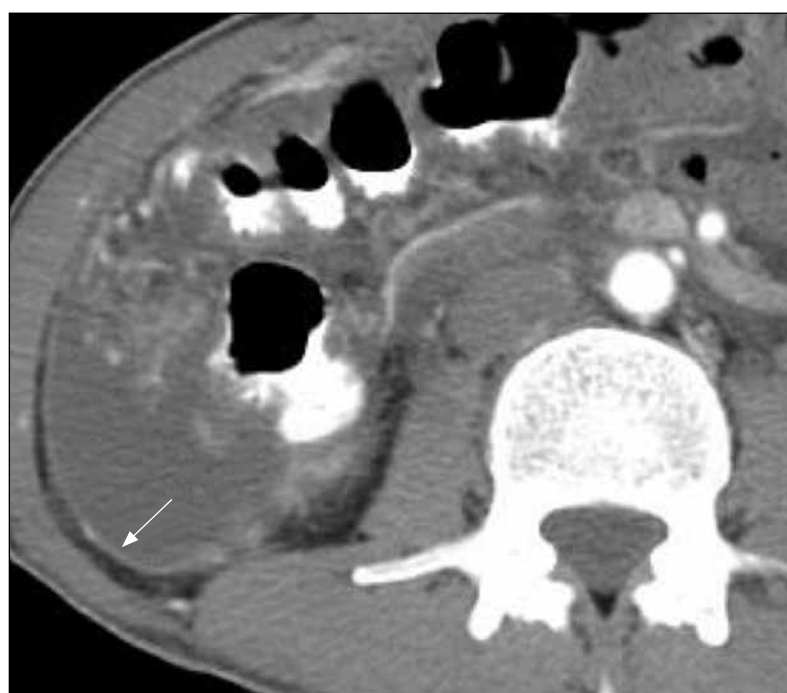


FIG 2. Computed tomography of the abdomen with oral and intravenous contrast showing peritoneal enhancement (arrow). There is associated ascites. Nodular thickening of the omentum is also seen adjacent to the ascending colon

patient suffered from recurrent small-bowel fistulas, peritonitis, and sepsis, before she died.<sup>9</sup>

A case of Degos' syndrome described by González Valverde et al<sup>10</sup> presented with acute abdominal pain due to intestinal perforation and multiple serosal maculae on the intestine; Degos' syndrome was not diagnosed until a few erythematous skin lesions were discovered. The CT findings in a 40-year-old woman with Degos' syndrome were described by Amaravadi et al.<sup>8</sup> They included extensive ascites, nodular thickening of the omentum, small bowel wall thickening, gross pneumoperitoneum with small bowel perforations, and intraluminal haemorrhage into a loop of infarcted jejunum.<sup>8</sup>

### Imaging findings in Degos' syndrome with intestinal involvement

The serial CT images of our patient demonstrated the sites of perforation, peritoneal enhancement and nodular omentum, of which the features are not specific for Degos' syndrome. The nodular omentum may resemble other conditions such as peritoneal carcinomatosis. A nodular omentum also reported by Amaravadi et al<sup>8</sup> in their report of a patient with Degos' syndrome. A nodular omentum may be related to inflammation and ischaemia.

In our patient, CT showed patent mesenteric vessels and absence of atherosclerosis, excluded that there was mesenteric artery and vein occlusion. Tiny pockets of pneumatosis intestinalis were noted in the ileum and ascending colon during the first and third admissions. The pneumatosis was a bubble-like configuration, but without associated portovenous gas. Our patient recovered without surgery after the first admission, and no definite sign of bowel ischaemia was found at surgery on another occasion.

Pneumatosis intestinalis was previously regarded as a sign of transmural necrosis, but it can also be due to different non-ischaemic causes such as chronic obstructive pulmonary disease, connective tissue diseases or infectious enterocolitis, none of which are necessarily associated with unfavourable outcomes.<sup>11,12</sup> Kernagis et al<sup>11</sup> suggested that isolated pneumatosis without portovenous gas and other signs of ischaemia is more likely to have partial mural ischaemia. Wiesner et al<sup>12</sup> concluded that bubble-like pneumatosis may be related to only partial mural bowel ischaemia. Nonetheless, Degos' syndrome is

a vasculopathy that can cause tissue necrosis, and bowel ischaemia cannot be excluded in the presence of pneumatosis. It is difficult to ascertain whether there was any bowel ischaemia in our patient, because no surgical specimen was sent for analysis.

The presence of tiny pockets of pneumoperitoneum noted during episodes of abdominal pain added to the diagnostic difficulty, because they may be the result of bowel perforation in 85 to 90% of cases.<sup>13,14</sup> The patient was at risk of bowel ischaemia, which can cause bowel perforation with pneumoperitoneum. These gas pockets might as well have arisen from ruptured pneumatosis, which were themselves of undetermined significance in our case. However, CT cannot distinguish pneumoperitoneum due to ruptured pneumatosis as opposed to bowel perforation. The patient recovered without surgery during the first admission, but at his second admission he was found to have bowel perforation. During his third admission, CT showed both pneumatosis and pneumoperitoneum. The operation 3 months earlier (during his second admission for bowel perforation) could not account for the pneumoperitoneum. The choice between emergency surgery and conservative management for this episode was a difficult decision for the attending clinician, as the patient was acutely symptomatic and had a history of bowel perforation. A clean peritoneum was found at surgery, there being no definite sign of perforation.

With advance in imaging and increasing sensitivity of CT, tiny gas pockets can be detected, which makes it difficult to determine how much pneumatosis and pneumoperitoneum warrant recourse to surgery. Further studies are needed to determine the significance of tiny pockets of pneumoperitoneum and pneumatosis intestinalis in patients with acute abdominal pain, in which the cause may not be evident. In such instances, the clinical course may be amenable to conservative management.

To conclude, CT findings are non-specific in Degos' syndrome. Nodular omentum, peritoneal enhancement, perforation site, pneumoperitoneum, and pneumatosis intestinalis may be demonstrated. Whether operation is indicated for the presence of tiny gas pockets due to pneumoperitoneum and pneumatosis intestinalis is doubtful. The significance of these tiny gas pockets needs to be determined by more studies.

### References

1. Scheinfeld NS. Degos disease. Medscape website: <http://emedicine.medscape.com/article/1087180-overview>. Accessed Dec 2010.
2. Scheinfeld N. Malignant atrophic papulosis. Clin Exp Dermatol 2007;32:483-7.
3. High WA, Aranda J, Patel SB, Cockerell CJ, Costner MI. Is Degos' disease a clinical and histological end point rather than a specific disease? J Am Acad Dermatol 2004;50:895-9.

4. Chave TA, Varma S, Patel GK, Knight AG. Malignant atrophic papulosis (Degos' disease): clinicopathological correlations. *J Eur Acad Dermatol Venereol* 2001;15:43-5.
5. Scheinfeld N. Pairing and comparing nine diseases with Degos Disease (Malignant Atrophic Papulosis): an attempt to illustrate our understanding and direct future inquiry. *Dermatol Online J* 2009;15:10.
6. McFarland HR, Wood WG, Drowns BV, Meneses AC. Papulosis atrophicans maligna (Köhlmeier-Degos disease): a disseminated occlusive vasculopathy. *Ann Neurol* 1978;3:388-92.
7. Schade FB, Monnens L, Hendriks JH, Rosenbusch G. Renovascular hypertension in a child with Degos-Köhlmeier disease. *Paediatr Radiol* 1987;17:260-1.
8. Amaravadi RR, Tran TM, Altman R, Scheirey CD. Small bowel infarcts in Degos disease. *Abdom Imaging* 2008;33:196-9.
9. Kim DW, Kang SB, Lee KH, Choe GY, Park SY, Nicholay M. Degos' disease (malignant atrophic papulosis) as a fatal cause of acute abdomen: report of a case. *Surg Today* 2008;38:866-70.
10. González Valverde FM, Menarguez Pina F, Ruiz JA, Gómez Ramos MJ, Mauri Barbera F, Luri Prieto P, et al. Presentation of Degos syndrome as acute small-bowel perforation. *Arch Surg* 2003;138:57-8.
11. Kernagis LY, Levine MS, Jacobs JE. Pneumatosis intestinalis in patients with ischemia: correlation of CT findings with viability of the bowel. *AJR Am J Roentgenol* 2003;180:733-6.
12. Wiesner W, Mortelé KJ, Glickman JN, Ji H, Ros PR. Pneumatosis intestinalis and portomesenteric venous gas in intestinal ischemia: correlation of CT findings with severity of ischemia and clinical outcome. *AJR Am J Roentgenol* 2001;177:1319-23.
13. Mularski RA, Sippel JM, Osborne ML. Pneumoperitoneum: a review of nonsurgical causes. *Crit Care Med* 2000;28:2638-44.
14. Ustek S, Boran M, Kismet K. Benign pneumoperitoneum after colonoscopy. *Case Report Med* 2010;2010:631036.

## Answers to CME Programme

### *Hong Kong Medical Journal* February 2013 issue

Hong Kong Med J 2013;19:20-6

#### **I. Endobronchial ultrasound-guided transbronchial needle aspiration in lung cancer: the first experience in Hong Kong**

- |   |         |          |          |          |          |
|---|---------|----------|----------|----------|----------|
| A | 1. True | 2. False | 3. False | 4. True  | 5. True  |
| B | 1. True | 2. False | 3. False | 4. False | 5. False |

Hong Kong Med J 2013;19:69-73

#### **II. Angioplasty and stenting for intracranial atherosclerotic stenosis: position statement of the Hong Kong Society of Interventional and Therapeutic Neuroradiology**

- |   |          |          |          |          |          |
|---|----------|----------|----------|----------|----------|
| A | 1. True  | 2. False | 3. False | 4. False | 5. False |
| B | 1. False | 2. True  | 3. False | 4. True  | 5. False |