

Malignancies in Chinese patients with neurofibromatosis type 1

Daniel KL Cheuk 卓家良
Alan KS Chiang 蔣國誠
SY Ha 夏修賢
Godfrey CF Chan 陳志峰

Objective To investigate the pattern of malignancies in Chinese patients with neurofibromatosis type 1.

Design Historical cohort study.

Setting Queen Mary Hospital and Duchess of Kent Children's Hospital in Hong Kong.

Patients Patients with neurofibromatosis type 1 seen between January 1995 and August 2011.

Results We identified 123 Chinese patients with neurofibromatosis type 1, diagnosed at a median age of 4.9 years (range, 0.1-16.1 years); 75 (61%) were males. They were followed up for a median of 9.7 years (range, 0.2-27.6 years). Most (80%) of the patients participated in our surveillance programme. Twelve patients developed malignancies at the ages of 0.8 to 41.6 years. These malignancies included: peripheral nerve sheath tumours (n=3), juvenile myelomonocytic leukaemia (n=2), optic nerve glioma (n=1), thalamic pilocytic astrocytoma (n=1), rhabdomyosarcoma (n=1), osteosarcoma (n=1), neuroblastoma (n=1), anaplastic large cell lymphoma (n=1), and breast carcinoma and subsequently carcinoma of the ampulla of Vater (n=1). Among them, three had their tumours (optic glioma, thalamic astrocytoma, sacral malignant peripheral nerve sheath tumour) initially detected by surveillance imaging. Four patients survived without disease progression, three are alive with active disease, the remaining five died (when aged 3 to 56 years) with progressive or relapsed malignancies. The latter patients died from a neuroblastoma, a juvenile myelomonocytic leukaemia, a malignant peripheral nerve sheath tumour, a lymphoma, and a second primary tumour (carcinoma of ampulla of Vater, at the age of 56 years). In neurofibromatosis type 1 patients with malignancy, overall 30-year survival was significantly shorter than in those without malignancy (35% vs 93%, $P<0.001$).

Conclusion Chinese patients with neurofibromatosis type 1 are susceptible to different malignancies which contribute to mortality. These findings are similar to reports from overseas. Outcomes were unfavourable, except in patients having low-grade gliomas. Surveillance imaging may help early detection of deep-seated malignancies but the benefits accruing from such monitoring warrants prospective evaluation.

Key words

Child; Hong Kong; Neoplasms;
Neurofibromatosis 1

Hong Kong Med J 2013;19:42-9

Department of Paediatrics and
Adolescent Medicine, The University
of Hong Kong, Queen Mary Hospital,
Pokfulam, Hong Kong
DKL Cheuk, MB, BS, MMedSc
AKS Chiang, MB, BS, PhD
SY Ha, MB, BS, FHKAM (Paediatrics)
GCF Chan, MB, BS, MD

Correspondence to: Dr DKL Cheuk
Email: cheukkl@hkucc.hku.hk

New knowledge added by this study

- This is the first cohort study on Chinese patients with neurofibromatosis type 1 (NF1) and malignancies.
- A diversity of malignancies at different ages was found.
- Malignancies accounted for most of the mortality in these patients; significantly reduced survival was also found in them.

Implications for clinical practice or policy

- Chinese patients with NF1 should be monitored for the development of malignancies.

Introduction

Neurofibromatosis type 1 (NF1), also known as von Recklinghausen's disease, is a genetic disorder due to mutations in the *NF1* gene which is located in chromosome 17q11.2.

About half of the cases are inherited in an autosomal dominant manner and the rest are caused by de-novo mutations.¹ The mutation affects approximately 1 in 3000 to 3500 individuals,^{2,3} with approximately equal gender distribution,^{4,6} has complete penetrance but variable expressivity. It is diagnosed when two of the following seven National Institutes of Health (NIH) criteria⁷ are present: (1) more than six café au lait macules exceeding a diameter of 0.5 cm (in prepubertal individuals) or 1.5 cm (in those who are post-pubertal); (2) axillary or inguinal freckles; (3) two or more neurofibromas or one plexiform neurofibroma; (4) two or more Lisch nodules in the iris; (5) an optic glioma; (6) sphenoid dysplasia or thinning of long bone cortex with or without pseudarthrosis; and (7) confirmed NF1 in a first-degree relative. Many of these manifestations may not be present at birth and hence only about half of the patients are diagnosed in infancy.⁸ Many NF1 patients suffer from a myriad of morbidities in addition to those stipulated in the diagnostic criteria. These include growth disturbances, developmental impairments and learning disabilities, seizures, scoliosis, osteoporosis, vasculopathy, hypertension, and various malignancies.⁹

The clinical manifestations of NF1 are caused by the loss of functional neurofibromin protein encoded by the *NF1* gene. Neurofibromin is a GTPase-activating protein that down-regulates the proto-oncogene p21,¹⁰ which activates a number of signalling pathways promoting cell growth and proliferation. Loss or hypofunction of neurofibromin favours uncontrolled cellular proliferation and oncogenesis. Thus, NF1 is considered a tumour suppressor gene, as loss or hypofunction of one copy in the germline predisposes individuals to develop malignancies. Brain tumours are the most common neoplasms in patients with NF1, and affect up to 15 to 20% of patients^{11,12}; optic pathway low-grade glioma constitutes the largest proportion.^{5,13-15} Although not considered malignancies in the pathological sense, these tumours can cause considerable morbidity or even mortality, and may warrant intensive treatment involving surgery, chemotherapy, or radiotherapy. Malignant peripheral nerve sheath tumour (MPNST) is one of the most common extracranial malignancies associated with NF1, and has been reported in about 5 to 15% of patients.^{13,16-18}

In our paediatric unit in the Hong Kong West Cluster of the Hospital Authority, we have followed NF1 patients over several decades. We have also accepted referrals from other doctors in Hong Kong, as well as Macau, mainland China, and Southeast Asia. A neurofibromatosis surveillance programme was set up in the Duchess of Kent Children's Hospital in 1997 to provide regular surveillance examinations and investigations to identify and manage comorbidities. We therefore set out to review the

一型神經纖維瘤的華籍患者的惡性病變

目的 研究一型神經纖維瘤的華籍患者中惡性病變的模式。

設計 歷史隊列研究。

安排 香港瑪麗醫院及根德公爵夫人兒童醫院。

患者 1995年1月至2011年8月期間患有一型神經纖維瘤的病人。

結果 共有123名一型神經纖維瘤的華籍患者，其中75人（61%）為男性；確診年齡中位數為4.9歲（介乎0.1至16.1歲）；追蹤期中位數為9.7年（介乎0.2至27.6年）。大部份患者（80%）參與醫院的監察計劃。12人在0.8至41.6歲的時候發現惡性病變。惡性病變包括外周神經鞘瘤（3例）、幼年單核細胞白血病（2例）、視神經膠質瘤（1例）、丘腦毛細胞型星形細胞瘤（1例）、橫紋肌肉瘤（1例）、骨肉瘤（1例）、神經母細胞瘤（1例）、間變性大細胞淋巴瘤（1例）、以及乳腺癌和及後的乏特氏壺腹腺癌（1例）。當中3例在監察計劃的成像過程中被發現（視神經膠質瘤、丘腦毛細胞型星形細胞瘤、骶骨惡性外周神經鞘瘤），4例病情並無惡化及仍然生存，3例病情惡化但仍生存。餘下的5例因病情惡化或復發而死亡，其惡性病變包括神經母細胞瘤、幼年單核細胞白血病、惡性外周神經鞘瘤及淋巴瘤（患者死亡年齡介乎3至56歲），另1例為二重癌（乏特氏壺腹腺癌，患者死亡年齡56歲）。與沒有惡性病變的患者比較，患有惡性病變的一型神經纖維瘤患者的30年生存率明顯較低（93%比35%； $P<0.001$ ）。

結論 一型神經纖維瘤的華籍患者較容易出現不同的惡性病變而引致死亡。這現象與其他國家的情況相似。除了患有低惡性度膠質瘤的病人外，所有患者的治療結果並不理想。醫院的監察計劃可能有助及早發現深部腫瘤，但類似的監察計劃是否真的可以為病人帶來好處仍需進一步長遠的評估。

pattern of malignancies in these patients, and their management and outcomes.

Methods

Study design and participants

This was a retrospective review of all Chinese patients with confirmed NF1 seen in the Hong Kong West Cluster (Queen Mary Hospital and Duchess of Kent Children's Hospital), a university-affiliated tertiary referral centre in Hong Kong, over the past 16 years (January 1995 to August 2011). Patients were identified by electronic search of the Clinical Data Analysis and Reporting System (CDARS) of the Hospital Authority, using the ICD10 diagnostic codes of 273.70 (neurofibromatosis) and 273.71 (neurofibromatosis type 1). We also searched the electronic clinical

TABLE 1. The neurofibromatosis type 1 surveillance programme*

Surveillance activities	Start time	Follow-up
History and clinical examination	At diagnosis	Every 6 to 12 months
MRI brain	5-6 Years old	If normal, repeated once every 2 years, and at 17 years; if abnormal, repeated more frequently as indicated
MRI orbit and spine	At diagnosis	Repeated when indicated
Ultrasound abdomen	At diagnosis	Yearly (proceeding to CT or MRI if abnormal)
Blood counts and smear	At diagnosis	Alternate year
Urine VMA and HVA	At diagnosis	Alternate year
Skeletal survey	At diagnosis	None
Visual assessment by optometrist	At diagnosis	Yearly
Hearing assessment by audiologist	At diagnosis	Yearly
Intellectual assessment by clinical psychologist	6 Years old	Repeated once 2 years later

* MRI denotes magnetic resonance imaging, VMA vanillylmandelic acid, HVA homovanillic acid, and CT computed tomography

database of the Paediatric Haematology/Oncology Division of Queen Mary Hospital, which has registered all children with haematological and oncological diseases since 1991.

Our department has started to manage and follow-up patients with NF1 well before 1995. However, the current electronic database in the Hospital Authority could only retrieve patients registered on or after 1995. In 1997, a more structured NF1 surveillance programme was initiated in the Duchess of Kent Children's Hospital to provide regular surveillance examinations and investigations to identify and manage co-morbidities. The components of the surveillance programme are shown in Table 1. Patients with NF1 were mainly seen at the Duchess of Kent Children's Hospital. Patients with complicated neurofibromas or suspected malignancies were also seen at the Haematology or Oncology Clinics in Queen Mary Hospital. In general, patients were referred to adult medical services after they reached adulthood (18 years old).

Patient data on demographic and clinical characteristics were extracted from the computerised Clinical Management System and the clinical database of the Haematology/Oncology Division of our department. Patients who fulfilled the NIH diagnostic criteria of NF1 were included, and those who had isolated features only (such as café au lait macules) were excluded. Patients who were not ethnic Chinese were also excluded. In this review, all malignant neoplasms and brain tumours (high- and low-grade) were included as 'malignancies'.

Statistical analyses

The cumulative frequency of malignancy in NF1 patients at different time points was estimated by the Kaplan-Meier method. Overall survival and event-free

survival of NF1 patients with malignancy were also estimated by the Kaplan-Meier method. The overall survival of NF1 patients with and without malignancy was compared by the log rank test. A two-tailed P value of <0.05 was considered statistically significant.

Results

We identified 123 Chinese patients with confirmed NF1. Of these, 57 were identified from both the CDARS of Hospital Authority and the database of the Paediatric Haematology/Oncology Division of Queen Mary Hospital, 63 only from the CDARS of the Hospital Authority, and 3 only from the database of the Paediatric Haematology/Oncology Division of Queen Mary Hospital. They were diagnosed at a median age of 4.9 years (range, 0.1-16.1 years); 75 (61%) were males. They were followed up for a median of 9.7 years (range, 0.2-27.6 years; including follow-up to adulthood). At the time of last follow-up near the time of the current study (August 2011), the median age of the 117 patients considered to be survivors was 16.2 years (range, 1.5-34.4 years), whereas six were known to have died. Among the former 117 patients, 18 lost to follow-up were regarded as alive (as at last follow-up). Most of the patients (80%) had participated in our NF1 surveillance programme for a median duration of 7.7 (range, 0.1-13.8) years, 12 of whom developed malignancies at a median age of 13.6 (range, 0.8-41.6) years. There was no significant difference in the proportions developing malignancy in males and females. The cumulative malignancy risk was estimated to be 12% at 20 years and 16% at 30 years (Fig 1).

Malignancies developed in patients with NF1 included: MPNST (n=3), neuroblastoma (n=1), rhabdomyosarcoma (n=1), osteosarcoma (n=1), optic nerve glioma (n=1), thalamic pilocytic astrocytoma

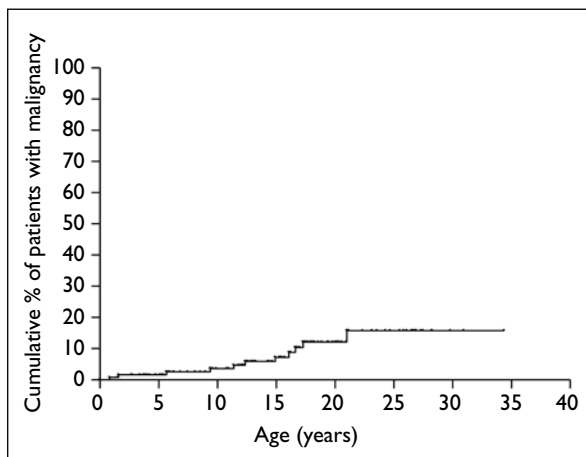


FIG 1. Cumulative malignancy risk in patients with neurofibromatosis type I over time

(n=1), juvenile myelomonocytic leukaemia (JMML) (n=2), anaplastic large cell lymphoma (ALCL) [n=1], and breast carcinoma and subsequently carcinoma of the ampulla of Vater (n=1). Patient characteristics, management, and outcomes are shown in Table 2.

In three of the patients, malignancies (optic glioma, thalamic astrocytoma, sacral MPNST) were initially detected by surveillance using magnetic resonance imaging (MRI). The patient with rhabdomyosarcoma was diagnosed at a young age before surveillance was started. The patient with osteosarcoma presented with symptoms before the next scheduled follow-up. The patient with lymphoma was diagnosed in adulthood after leaving our surveillance programme. The remaining six patients never underwent surveillance.

TABLE 2. Characteristics of neurofibromatosis type I patients with malignancies*

Patient No.	Type of malignancy	Sex	Age at diagnosis of malignancy (years)	Presentation	Joined surveillance programme	Malignancy picked up by surveillance or not	Treatment	Outcome
1	JMML	M	0.8	Fever for 3 days, hepatomegaly, splenomegaly, leukocytosis, monocytosis	No	No	Splenectomy, unrelated cord blood transplant	Relapsed at 4.9 years, on palliative care at last follow-up at 5.1 years
2	Neuroblastoma stage 4	M	1.58	Left supraclavicular lymphadenopathy, hepatomegaly	No	No	Chemotherapy, radiotherapy, autologous stem cell transplant	Relapsed at 2.5 years and died of progressive disease at 3.3 years
3	Presacral embryonal rhabdomyosarcoma	F	5.7	Left hip and buttock pain for 2 weeks	Yes	No	Surgical resection, chemotherapy, radiotherapy	Alive without disease at 12.1 years
4	JMML	M	9.4	Skin rash and fever	No	No	Matched sibling bone marrow transplant	Relapsed at 9.9 years and died of progressive disease at 10.7 years
5	Sacral MPNST	F	11.4	Tumour detected by surveillance MRI	Yes	Yes	Surgical resection	Relapsed at 11.7 years and defaulted follow-up
6	Optic nerve glioma	M	12.4	Tumour detected by surveillance MRI	Yes	Yes	No treatment	Alive with non-progressive disease at 21.4 years
7	Thalamic pilocytic astrocytoma	F	14.9	Tumour detected by surveillance MRI	Yes	Yes	Partial surgical resection	Alive with non-progressive disease at 18.2 years
8	Cervical MPNST	M	16.1	Left cervical mass	No	No	Surgical resection, radiotherapy	Relapsed at 16.6 years, on palliative care at last follow-up at 17.4 years
9	Metastatic pelvic MPNST	F	16.6	Bilateral lower limb pain and numbness	No	No	Chemotherapy, radiotherapy	Died of progressive disease at 16.9 years
10	Telangiectatic osteosarcoma of distal femur	M	17.3	Right knee pain for 2 months	Yes	No	Surgical resection with reconstruction, chemotherapy	Alive without disease at 21.3 years
11	Anaplastic large cell lymphoma	M	21.0	Bilateral cervical lymph node enlargement for 1 month	Yes	No	Chemotherapy	Relapsed at 23.0 years and died at 23.2 years
12	Carcinoma of breast	F	41.6	Left breast lump	No	No	Mastectomy, radiotherapy, chemotherapy	Complete remission, subsequent carcinoma of Ampulla of Vater at 54.5 years, relapsed and died at 56.2 years

* JMML denotes juvenile myelomonocytic leukaemia, MPNST malignant peripheral nerve sheath tumour, and MRI magnetic resonance imaging

Two of the 12 patients with malignancies (rhabdomyosarcoma and osteosarcoma) achieved long-term remission after multi-modality therapy that included surgery, and multi-agent chemotherapy with or without radiotherapy. The patient with an optic glioma received no treatment as he was asymptomatic, but he was actively monitored. The patient with a thalamic pilocytic astrocytoma had it partially resected and had non-progressive disease thereafter. The patient with a sacral MPNST underwent surgical resection only, and refused further adjuvant therapy. The tumour recurred for which he sought alternative treatment and defaulted follow-up. The patient with a cervical MPNST had disease relapse after surgical resection and radiotherapy. He had extensive disease and received palliative care. The patient with a metastatic MPNST had progressive disease despite chemotherapy and radiotherapy, and died 3 months after the diagnosis at the age of 16.9 years. One patient with JMML underwent a splenectomy followed by unrelated donor haematopoietic stem cell transplantation (HSCT). His disease recurred and he is currently receiving palliative care. The other patient with JMML relapsed 3 months after a matched sibling bone marrow transplant and died of progressive disease at the age of 10.7 years. The patient with stage-4 neuroblastoma achieved remission after chemotherapy, radiotherapy and autologous peripheral blood stem cell transplantation, but relapsed 3 months later and died of progressive disease aged 3.3 years. The patient with ALCL achieved remission after chemotherapy but died with relapsed lymphoma 2 years later at the age of 23 years. The patient with breast cancer entered remission following surgery, radiotherapy and chemotherapy but developed carcinoma of ampulla of Vater about 13 years later. After resection, her carcinoma recurred with multiple metastases and she died at the age of 56 years. The 5-year overall survival and event-free survival in our NF1 patients with malignancies were 62% and 38%, respectively (Fig 2).

One patient with NF1 but without malignancy died at the age of 25 years, because of severe scoliosis causing severe restrictive lung disease and pneumonia. The overall 30-year survival of NF1 patients with or without malignancies differed significantly (35% vs 93%, $P<0.001$) [Fig 3].

Discussion

To the best of our knowledge, this is the largest study on the spectrum of malignancies in Chinese patients with NF1, which is one of the cancer-predisposing genetic disorders. In epidemiological studies in Sweden and Denmark, the risk of malignancy in NF1 was estimated to be about 4 times that of the general population.^{5,16} The frequency of malignancy

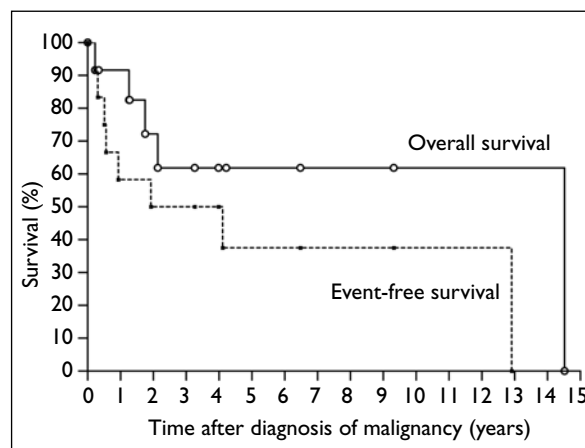


FIG 2. Survival of patients with neurofibromatosis type I with malignancy

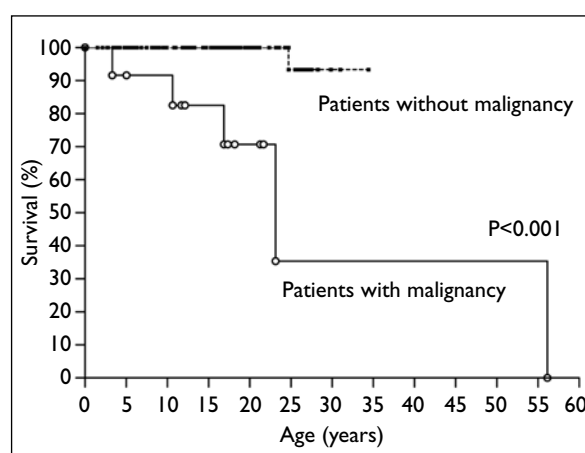


FIG 3. Overall survival of patients with and without neurofibromatosis type I

in NF1 in the UK was reported to be 7% by the age of 20 years and 20% by the age of 50 years, which is in excess of that in the general population.⁴ We could not reliably estimate the frequency of malignancy in Chinese patients with NF1, owing to their geographical mobility, bias due to selective referral of malignant cases, and incomplete follow-up into older adulthood.

The distribution of different types of malignancies in patients with NF1 is somewhat different among different populations. In Sweden and Denmark, carcinoma is the most common, followed by sarcoma¹⁶ or brain tumours.⁵ In the UK by contrast, the most common were connective tissue tumours, followed by brain tumours. The majority of the malignant connective tissue tumours were derived from neural-associated tissues (neurofibrosarcoma, malignant neurilemmoma, spindle cell sarcoma of peripheral nerves, and MPNST), and brain tumours that mainly consisted of optic pathway gliomas.⁴ A smaller cohort in Pittsburgh demonstrated a similar pattern of malignancies, with brain tumours being the most common, followed by sarcoma of neural

origin.¹⁹ This pattern of malignancies was similar to what we found in our NF1 patients, and included a variety of many different malignancies. Females with NF1 were reported to be at higher risk of breast cancer than in the general population, particularly among those aged 40 to 50 years⁴ (like our patient). Multiple primary tumours were also quite common, and were reported in about 8% of NF1 patients with malignancy in the UK.⁴ Our cohort also showed a similar frequency of second primary tumours, one of 12 of whom had more than one primary tumour. Some studies reported that females had a higher risk of malignancy than males,⁴ but we did not replicate this observation, which may have been due to our relatively small sample size limiting the statistical power to detect a difference.

In general, the treatment of malignancies in NF1 patients is similar to that in patients without NF1. The prognosis is variable and depends mainly on the histological type and treatment response. Patients with brain tumours tend to have better outcomes compared to their counterparts without NF1.²⁰ Optic pathway gliomas in patients with NF1 tend to occur within the first 5 years of life and are also less likely to cause visual impairment than their sporadic counterparts.²¹ In NF1 patients, these tumours are usually stable for many years or only progress slowly^{22,23}; some may even regress without specific treatment.^{24,25} In our study, both the patients with low-grade gliomas also demonstrated a non-progressive course. When treatment is required due to progressive symptoms or complications (such as hydrocephalus) in this era, chemotherapy with or without surgical resection is usually the treatment of choice.²² Radiotherapy is not recommended owing to the heightened risk of second malignancies in these genetically susceptible subjects.^{22,26}

By contrast, NF1 patients with MPNST have significantly poorer 5-year survival (0-21% only), compared to 42 to 54% for sporadic MPNST.^{17,18} Sporadic MPNST mainly manifests in the elderly at a median age of 62 years.¹⁷ In patients with NF1, this tumour presents at a median age of 26 years.¹⁷ Because of the young age of onset and poor associated survival, the life expectancy of such NF1 patients is significantly shorter; an average reduction of about 15 years has been reported.^{27,28} Whether this also applies to Chinese patients needs resolving by further follow-up of our patients. The high frequency coupled with the poor prognosis of MPNST and other malignancies in NF1 sufferers confers a poor outlook in these patients. This was also illustrated in the present study, in that patients who developed malignancies had significantly worse overall survival, which was consistent with other studies,^{27,28} showing that malignancies were the major cause.

Whilst JMML is relatively infrequent in

patients with NF1, it co-exists in about 11% of all cases.²⁹ Allogeneic HSCT is the treatment of choice and should be performed early if a suitable human leukocyte antigen-matched donor is available.³⁰ In NF1 patients, the prognosis of JMML does not differ from most other cases with different causes of RAS signalling pathway dysregulation,^{30,31} and may be better than in those harbouring PTPN11 mutations.³¹ Both patients with JMML in our cohort also underwent allogeneic HSCT but their disease recurred and their outcomes were dismal.

Whether malignancy surveillance in patients with NF1 is beneficial remains controversial. In our NF1 surveillance programme, we perform biannual blood counts and urine vanillylmandelic acid and homovanillic acid, and annual abdominal ultrasonography and optometrist assessments to monitor for leukaemia, neuroblastomas, other intra-abdominal tumours, and optic pathway gliomas. To screen for abnormalities, we also performed MRIs of the brain (twice) and of the orbit and spine (once). One study reported the usefulness of repeat MRIs,³² while others disagreed.³³ In the current study, three of the 12 malignancies were discovered by surveillance imaging. In two patients, they developed earlier than the start of surveillance and in another the malignancy developed in adulthood after he left our surveillance programme. Five patients developed malignancies in the era before we started surveillance. Interestingly, one developed a malignancy that presented between surveillance visits. These observations suggested that to detect malignancies earlier in patients with NF1, we have to start monitoring earlier, continuously, more frequently, and throughout most of adulthood. Whether such surveillance is effective in improving prognosis or cost-effective is questionable, especially if regular MRI has to be incorporated. Screening for optic pathway glioma by MRI may be a more reasonable option, as this tumour occurs in early childhood and screening can cease after the child is 6 years old. Moreover, in these patients the prevalence of such gliomas is high and effective treatment is available to prevent/limit visual impairment. Both patients with an optic pathway glioma in our cohort were detected by MRI, which enabled early treatment. Besides optic pathway gliomas, NF1 patients continue to have other co-morbidities, including but not limited to malignancies in adulthood. Thus, a multidisciplinary comprehensive health monitoring programme to identify and manage potential problems is also recommended in adulthood.³⁴ Physical examination for scoliosis, hypertension, and the screening of vision and hearing should be undertaken at regular follow-ups. In the primary care setting, physicians should be alert to common presentations of different malignancies in NF1 patients of different ages. Young children with JMML may present with anaemia, bleeding, and recurrent infections. They are also at

high risk of developing optic pathway gliomas with visual symptoms or features of raised intracranial pressure. Young adult patients who have pain or increased growth in a plexiform neurofibroma could have a MPNST. Middle-aged NF1 patients may develop a wide range of carcinomas and sarcomas in different organs at a relatively younger age than the general population. Patients should be educated on early reporting of warning symptoms of malignancy, and counselled about advances in treatment. Physicians caring for NF1 patients can also provide valuable social and emotional support.

The current study has several limitations. Compared to reported national studies in other countries, the relatively small sample size in ours was an important limitation affecting statistical power. However, this was already the largest study on malignancies in Chinese patients with NF1. Secondly,

referral bias may have been present, as our unit was a tertiary referral centre. Thus, the data may not be representative of the whole territory. However, since we do not have a registry on malignancies in NF1 patients, these data are the best that are currently available.

Conclusion

Patients with NF1 are susceptible to a variety of malignancies which contribute to most of their mortalities and reduce life expectancy. The outcomes of these patients with malignancies were unfavourable, except in persons having low-grade gliomas. Surveillance imaging may be beneficial for optic pathway gliomas and help early detection of deep-seated malignancies, but requires further prospective evaluation of its cost-effectiveness.

References

1. North K. Neurofibromatosis type 1: review of the first 200 patients in an Australian clinic. *J Child Neurol* 1993;8:395-402.
2. Lammert M, Friedman JM, Kluwe L, Mautner VF. Prevalence of neurofibromatosis 1 in German children at elementary school enrollment. *Arch Dermatol* 2005;141:71-4.
3. Samuelsson B, Axelsson R. Neurofibromatosis. A clinical and genetic study of 96 cases in Gothenburg, Sweden. *Acta Derm Venereol Suppl (Stockh)* 1981;95:67-71.
4. Walker L, Thompson D, Easton D, et al. A prospective study of neurofibromatosis type 1 cancer incidence in the UK. *Br J Cancer* 2006;95:233-8.
5. Sørensen SA, Mulvihill JJ, Nielsen A. Long-term follow-up of von Recklinghausen neurofibromatosis. Survival and malignant neoplasms. *N Engl J Med* 1986;314:1010-5.
6. Airewele GE, Sigurdson AJ, Wiley KJ, et al. Neoplasms in neurofibromatosis 1 are related to gender but not to family history of cancer. *Genet Epidemiol* 2001;20:75-86.
7. Gutmann DH, Aylsworth A, Carey JC, et al. The diagnostic evaluation and multidisciplinary management of neurofibromatosis 1 and neurofibromatosis 2. *JAMA* 1997;278:51-7.
8. DeBella K, Szudek J, Friedman JM. Use of the national institutes of health criteria for diagnosis of neurofibromatosis 1 in children. *Pediatrics* 2000;105:608-14.
9. Tonsgard JH. Clinical manifestations and management of neurofibromatosis type 1. *Semin Pediatr Neurol* 2006;13:2-7.
10. Martin GA, Viskochil D, Bollag G, et al. The GAP-related domain of the neurofibromatosis type 1 gene product interacts with ras p21. *Cell* 1990;63:843-9.
11. Listernick R, Charrow J, Greenwald M, Mets M. Natural history of optic pathway tumors in children with neurofibromatosis type 1: a longitudinal study. *J Pediatr* 1994;125:63-6.
12. Listernick R, Charrow J, Greenwald MJ, Esterly NB. Optic gliomas in children with neurofibromatosis type 1. *J Pediatr* 1989;114:788-92.
13. McCaughan JM, Harris DI, Donnai D, et al. A clinical study of type 1 neurofibromatosis in north west England. *J Med Genet* 1999;36:197-203.
14. Lewis RA, Gerson LP, Axelsson KA, Riccardi VM, Whitford RP. von Recklinghausen neurofibromatosis. II. Incidence of optic gliomata. *Ophthalmology* 1984;91:929-35.
15. Rosenfeld A, Listernick R, Charrow J, Goldman S. Neurofibromatosis type 1 and high-grade tumors of the central nervous system. *Childs Nerv Syst* 2010;26:663-7.
16. Zöller ME, Rembeck B, Odén A, Samuelsson M, Angervall L. Malignant and benign tumors in patients with neurofibromatosis type 1 in a defined Swedish population. *Cancer* 1997;79:2125-31.
17. Evans DG, Baser ME, McCaughan J, Sharif S, Howard E, Moran A. Malignant peripheral nerve sheath tumours in neurofibromatosis 1. *J Med Genet* 2002;39:311-4.
18. McCaughan JA, Holloway SM, Davidson R, Lam WW. Further evidence of the increased risk for malignant peripheral nerve sheath tumour from a Scottish cohort of patients with neurofibromatosis type 1. *J Med Genet* 2007;44:463-6.
19. Blatt J, Jaffe R, Deutsch M, Adkins JC. Neurofibromatosis and childhood tumors. *Cancer* 1986;57:1225-9.
20. Jett K, Friedman JM. Clinical and genetic aspects of neurofibromatosis 1. *Genet Med* 2010;12:1-11.
21. Singhal S, Birch JM, Kerr B, Lashford L, Evans DG. Neurofibromatosis type 1 and sporadic optic gliomas. *Arch Dis Child* 2002;87:65-70.
22. Listernick R, Ferner RE, Liu GT, Gutmann DH. Optic pathway gliomas in neurofibromatosis-1: controversies and recommendations. *Ann Neurol* 2007;61:189-98.
23. Shamji MF, Benoit BG. Syndromic and sporadic pediatric optic pathway gliomas: review of clinical and histopathological differences and treatment implications. *Neurosurg Focus* 2007;23:E3.
24. Gottschalk S, Tavakolian R, Buske A, Tinschert S, Lehmann R. Spontaneous remission of chiasmatic/hypothalamic masses in neurofibromatosis type 1: report of two cases. *Neuroradiology* 1999;41:199-201.

25. Parsa CF, Hoyt CS, Lesser RL, et al. Spontaneous regression of optic gliomas: thirteen cases documented by serial neuroimaging. *Arch Ophthalmol* 2001;119:516-29.
26. Kleinerman RA. Radiation-sensitive genetically susceptible pediatric sub-populations. *Pediatr Radiol* 2009;39 Suppl 1:S27-31.
27. Zöller M, Rembeck B, Akesson HO, Angervall L. Life expectancy, mortality and prognostic factors in neurofibromatosis type 1. A twelve-year follow-up of an epidemiological study in Göteborg, Sweden. *Acta Derm Venereol* 1995;75:136-40.
28. Rasmussen SA, Yang Q, Friedman JM. Mortality in neurofibromatosis 1: an analysis using U.S. death certificates. *Am J Hum Genet* 2001;68:1110-8.
29. Niemeyer CM, Arico M, Basso G, et al. Chronic myelomonocytic leukemia in childhood: a retrospective analysis of 110 cases. European Working Group on Myelodysplastic Syndromes in Childhood (EWOG-MDS). *Blood* 1997;89:3534-43.
30. Loh ML. Recent advances in the pathogenesis and treatment of juvenile myelomonocytic leukaemia. *Br J Haematol* 2011;152:677-87.
31. Yoshida N, Yagasaki H, Xu Y, et al. Correlation of clinical features with the mutational status of GM-CSF signaling pathway-related genes in juvenile myelomonocytic leukemia. *Pediatr Res* 2009;65:334-40.
32. Blazo MA, Lewis RA, Chintagumpala MM, Frazier M, McCluggage C, Plon SE. Outcomes of systematic screening for optic pathway tumors in children with Neurofibromatosis Type 1. *Am J Med Genet A* 2004;127A:224-9.
33. Listernick R, Charrow J. Knowledge without truth: screening for complications of neurofibromatosis type 1 in childhood. *Am J Med Genet A* 2004;127A:221-3.
34. Ferner RE, Huson SM, Thomas N, et al. Guidelines for the diagnosis and management of individuals with neurofibromatosis 1. *J Med Genet* 2007;44:81-8.

Answers to CME Programme

Hong Kong Medical Journal December 2012 issue

Hong Kong Med J 2012;18:466–74

I. Incidence, mortality, and survival trends of ovarian cancer in Hong Kong, 1997 to 2006: a population-based study

- | | | | | | |
|---|---------|----------|---------|----------|----------|
| A | 1. True | 2. False | 3. True | 4. False | 5. True |
| B | 1. True | 2. True | 3. True | 4. False | 5. False |

Hong Kong Med J 2012;18:482–7

II. Pitfalls in diagnosing septic arthritis in Hong Kong children: ten years' experience

- | | | | | | |
|---|----------|----------|----------|----------|---------|
| A | 1. False | 2. True | 3. False | 4. True | 5. True |
| B | 1. True | 2. False | 3. True | 4. False | 5. True |