

# Clinicopathological study of renal biopsies after liver transplantation

Gavin SW Chan 陳雙煒  
MF Lam 林萬斐  
Lorraine Kwan 關佩玄  
SH Fung 馮成海  
SC Chan 陳詩正  
KW Chan 陳國華

**Objective** To perform a clinicopathological study of patients having renal biopsies after liver transplantation.

**Design** Case series.

**Setting** Queen Mary Hospital, Hong Kong.

**Patients** All post-liver transplantation patients who had a renal biopsy in the period from January 2000 to December 2010.

**Results** Eleven renal biopsies were retrieved for review from 10 patients with liver transplantation. The male-to-female ratio was 9:1 (age range, 47-63 years). The median liver transplant-to-renal biopsy interval was 1590 (range, 102-3699) days. The predominant histological changes were interstitial fibrosis and tubular atrophy. Diabetic nephropathy (n=6) and immunoglobulin A nephropathy (n=4) were the commonest glomerulopathies. Only one patient had chronic calcineurin inhibitor nephrotoxicity. With a mean follow-up of 53 months, three patients died 2 to 53 months post-renal biopsy. All surviving patients had chronic renal impairment. Five patients developed end-stage renal failure and four had significant persistent proteinuria.

**Conclusion** Renal pathology was variable after liver transplantation; most biopsies showed complex renal lesions, whilst calcineurin inhibitor nephrotoxicity was rare. The recognition of kidney histology attributable to metabolic derangements after liver transplantation is potentially important in the interpretation of renal biopsy specimens and patient management. The renal outlook of this group of patients is guarded.

## New knowledge added by this study

- The cause of renal impairment and proteinuria after liver transplantation (LT) in Hong Kong is multifactorial and complex.
- Metabolic derangements may account for many of the renal lesions after LT.

## Implications for clinical practice or policy

- The outlook of post-LT patients investigated by renal biopsy is associated with significant morbidity and mortality.
- Recognition of kidney histology attributable to metabolic derangement after LT has important implications for patient management.

## Key word

Liver transplantation

*Hong Kong Med J* 2013;19:27-32

Queen Mary Hospital, The University of Hong Kong, Hong Kong:  
Department of Pathology  
GSW Chan, FHKAM (Pathology)  
KW Chan, FHKAM (Pathology)  
Department of Medicine  
MF Lam, FHKAM (Medicine)  
L Kwan, MB, BS  
Department of Surgery  
SC Chan, PhD, FHKAM (Surgery)  
Department of Pathology, Pamela Youde Nethersole Eastern Hospital, Hong Kong  
SH Fung, FHKAM (Pathology)

Correspondence to: Dr GSW Chan  
Email: gavinchansw@yahoo.com

## Introduction

Renal impairment is a common problem after liver transplantation (LT). The cumulative incidence of chronic renal failure after LT is 13.9% and 18.1% over 3 and 5 years, respectively.<sup>1</sup> Studies evaluating renal pathology after LT are sparse and sample sizes are small.<sup>2-4</sup> Post-LT renal impairment is traditionally attributed to calcineurin inhibitor (CNI), a backbone of immunosuppression regimen.<sup>1,3,5-7</sup> This view was recently challenged by Kim et al,<sup>8</sup> who concluded that chronic renal impairment can rarely be ascribed to such toxicity. Many investigators have concluded that the cause of renal impairment may be multifactorial, complex, and interrelated.<sup>2,8-10</sup> Herein, we performed the first local clinicopathological analysis of liver transplant recipients who underwent renal biopsy. All the patients were recruited from Queen Mary Hospital, The University of Hong Kong, which is the only local centre for LT in Hong Kong.

## Methods

Between January 2000 and December 2010, 740 patients received LT (male-to-female

## 肝移植後腎活檢的臨床病理學

- 目的** 研究肝移植後腎活檢的臨床病理學。
- 設計** 病例系列。
- 安排** 香港瑪麗醫院。
- 患者** 2000年1月至2010年12月期間所有接受肝移植術後進行腎活檢的病人。
- 結果** 有10名病人在研究期間接受肝移植並進行共11次腎活檢。病人年齡介乎47至63歲，男女比例為9:1。從肝移植到腎活檢的時間差距中位數為1590天（介乎102至3699天）。主要的病理變化為腎間質纖維化及腎小管萎縮。最常見的腎小球腎炎是糖尿病腎病（6例）及免疫球蛋白A型腎病（4例）。只有1個慢性鈣調磷酸酶抑制劑腎毒性的病例。在53個月的追蹤期內，有3名病人在腎活檢後的2至53個月內死亡。所有病人均有慢性腎功能不全。5名病人有終末期腎功能衰竭，另4名病人有顯著的持續性蛋白尿。
- 結論** 肝移植後腎活檢的病理學結果有很大差異。大部份活檢結果都顯示有複雜的腎病變，而慢性鈣調磷酸酶抑制劑腎毒性的病例卻很少見。肝移植後，代謝紊亂對於解釋腎穿刺活檢結果和病人管理有潛在價值，亦必須密切留意這些病人的腎功能。

ratio=2.5:1; age range, 1.5 months to 72 years; median age, 48 years). Renal biopsy was considered if there was proteinuria of >1 g per day and/or significant renal impairment (>20% persistent increase in serum creatinine from baseline level on at least two occasions). Exclusion criteria were known reasons for renal impairment (CNI, diabetes mellitus, infections), response to modification of immunosuppressives

(lowering CNI dosage, change from a CNI to a non-CNI agent), improvement of renal function after withdrawal of nephrotoxic agents, serious co-morbidity, and no informed consent. During the same period, a total of 3398 percutaneous renal biopsies were accessed in the Department of Pathology, Queen Mary Hospital, The University of Hong Kong, of which 12 were from 10 LT patients. One renal allograft biopsy (from patient 4, who had a combined kidney and pancreas transplantation 65 months after LT) was excluded from this series. The archival materials were jointly reviewed by two renal pathologists (co-authors). Patient characteristics, biopsy indications, clinical course, and outcomes were retrieved from the medical records.

### Renal biopsy

All the renal biopsy specimens were routinely divided into three portions: the main portion being fixed in 10% formalin for paraffin embedding, a small portion was fixed in glutaraldehyde for transmission electron microscopy, and the rest snap frozen for immunofluorescence studies. The paraffin-embedded tissue was serially sectioned as 3-µm thick slices and stained with haematoxylin and eosin, periodic acid-Schiff, methenamine silver and Masson's trichrome. Direct immunofluorescence studies were carried out on the snap-frozen specimens, using FITC-conjugated antisera for immunoglobulin (Ig) A, IgG, IgM, C3, C1q and, when indicated, kappa and lambda light chains. Ultrastructural examination was performed on the glutaraldehyde fixed tissue to look for the presence of electron dense deposits, and assess the morphology of epithelial cells and any abnormalities of the glomerular basement membrane (GBM).

TABLE I. Demographic, clinical, and pathological features of the 10 patients who had renal biopsies after liver transplantation\*

Patient No.	Sex/age (years) at renal biopsy	Pre-LT HT	Pre-LT DM	Pre-LT dyslipidaemia	Indication of LT	Post-LT immunosuppression	Post-LT HT	Post-LT DM	Post-LT dyslipidaemia
1	M/62	N	Y	N	HCV cirrhosis; unresectable HCC	Steroid/MMF/cyclosporin A	Y	Y	Y
2	M/50	N	N	N	HBV cirrhosis	MMF	Y	Y	Y
3	M/55	N	N	N	HBV cirrhosis	Steroid	Y	Y	N
4	M/48	N	Y	N	HBV cirrhosis	Steroid/tacrolimus	Y	Y	N
5a	M/55	N	Y	N	HBV cirrhosis	Sirolimus/MMF	N	Y	Y
5b	M/63								
6	M/47	N	N	Y	HBV cirrhosis and HCV	Cyclosporin A/MMF	N	Y	N
7	M/56	N	N	N	HCV cirrhosis	Steroid/MMF	Y	N	N
8	M/54	N	N	N	HBV cirrhosis and HCC	MMF	N	N	N
9	F/59	Y	Y	N	HBV cirrhosis	Tacrolimus	Y	N	Y
10	M/59	N	N	N	HBV cirrhosis	Steroid/FK506	Y	Y	N

\* DM denotes diabetes mellitus, HBV hepatitis B virus, HCC hepatocellular carcinoma, HCV hepatitis C virus, HT hypertension, LT liver transplantation, MMF mycophenolate mofetil, Y yes, and N no

## Results

### Patient characteristics and outcomes

A total of 11 renal biopsies from 10 patients were retrieved; two were from patient 5 and performed 90 months apart. Metabolic/clinical derangements (hypertension, diabetes mellitus, or dyslipidaemia) were present pre-transplantation in five patients, and developed post-LT in nine. Table 1 summarises the demographic, clinical, and pathological features of these patients. Their median age was 55 (range, 47-63) years, and all but one were male. The indications for LT were chronic hepatitis B virus (HBV)-associated cirrhosis (n=8). Hepatitis C virus infection was noted in three patients, and superimposed hepatocellular carcinoma in two. No evidence of rejection was documented in any of these patients.

The median time elapsing between LT and renal biopsy was 1590 (range, 102-3699) days. The commonest indication for renal biopsy was significant proteinuria (>1 g/24 hour) found in eight patients (in 7 it was in the nephrotic range). Renal impairment

was noted in nine patients, seven of whom had both significant proteinuria and renal impairment when biopsied (Table 2).

After renal biopsy, immunosuppressive therapy was modified in five of the patients. Such modifications included withdrawal of steroid (patient 1), change of cyclosporin A to sirolimus and prednisolone (patient 6), switching from tacrolimus to sirolimus (patient 9), and addition of cyclophosphamide (patients 8 and 10). The mean follow-up period was 53 (range, 2-119) months post-renal biopsy; three patients succumbed at 2, 48, and 53 months after their renal biopsy. The cause of death included gastro-intestinal bleeding and post-transplant cerebral lymphoproliferative disorder. One patient died outside Hong Kong from an unknown cause. End-stage renal failure (ESRF) developed in five patients, two of whom underwent renal transplantation, including one who had a combined kidney and pancreas transplant. All of the surviving patients without renal transplantation had chronic renal impairment and proteinuria (>1 g/day).

TABLE 2. Pathological features and follow-up data of the 10 patients who had renal biopsies after liver transplantation\*

Patient No.	Indication of renal biopsy	Duration after LT (days)	Pathology	Follow-up
1	Renal impairment: Cr 173 µmol/L Proteinuria 3.31 g/d	716	DMN; CNI toxicity; arteriolar hyalinosis; moderate IF/TA	ESRF requiring haemodialysis 1 year later. Renal transplantation at 39 months after biopsy. Now normal renal function
2	Renal impairment: Cr 157 µmol/L Proteinuria 1.92 g/d	2062	DMN; arteriolar hyalinosis; moderate IF/TA	Alive with renal impairment: Cr 204 µmol/L Proteinuria 2.92 g/d
3	Renal impairment : Cr 190 µmol/L 24-Hour proteinuria 7.17 g/L	1590	DMN; arteriolar hyalinosis; moderate IF/TA	ESRF on haemodialysis
4	Progressive renal impairment: Cr 282 µmol/L Proteinuria 14.9 g/d	2496	DMN; arteriolar hyalinosis; severe IF/TA	ESRF with combined renal and pancreatic transplantation done 13 months later. Now normal renal function
5a	Nephrotic syndrome: Proteinuria 14 g/d	121	IgA nephropathy	-
5b	Chronic renal failure: Cr up to 1000 µmol/L	2851	DMN; arteriolar hyalinosis; severe IF/TA	ESRF on haemodialysis
6	Renal impairment: Cr 168 µmol/L Proteinuria 6.85 g/d	3699	IgA nephropathy; DMN; arteriolar hyalinosis; moderate IF/TA	Chronic renal impairment: Cr 230 µmol/L Proteinuria 7.47 g/d
7	Proteinuria 4.41 g/d	3072	IgA nephropathy; hypertensive nephrosclerosis; arteriolar hyalinosis; moderate IF/TA	Chronic renal impairment: Cr 207 µmol/L Developed EBV-associated post-transplant lymphoproliferative disorder in brain and subsequently died 53 months after renal biopsy
8	Acute renal impairment: Cr 150→492 µmol/L Proteinuria 2.4 g/d	176	IgA nephropathy with 50% crescents; mild IF/TA	Died in mainland China 2 months later; cause unknown
9	Renal impairment: Cr 117 µmol/L	102	Hypertensive nephrosclerosis; arteriolar hyalinosis; moderate IF/TA	Progressive renal impairment: Cr 300 µmol/L Proteinuria of 1.31 g/d
10	Renal impairment: Cr 200→300 µmol/L	866	MPGN; arteriolar hyalinosis; severe IF/TA	ESRF and died of gastro-intestinal bleeding 48 months later

\* CNI denotes calcineurin inhibitor, Cr creatinine, DMN diabetic nephropathy, EBV Epstein Barr virus, ESRF end-stage renal failure, IF/TA interstitial fibrosis/tubular atrophy, IgA immunoglobulin A, LT liver transplantation, and MPGN membranoproliferative glomerulonephritis

### Renal histopathology

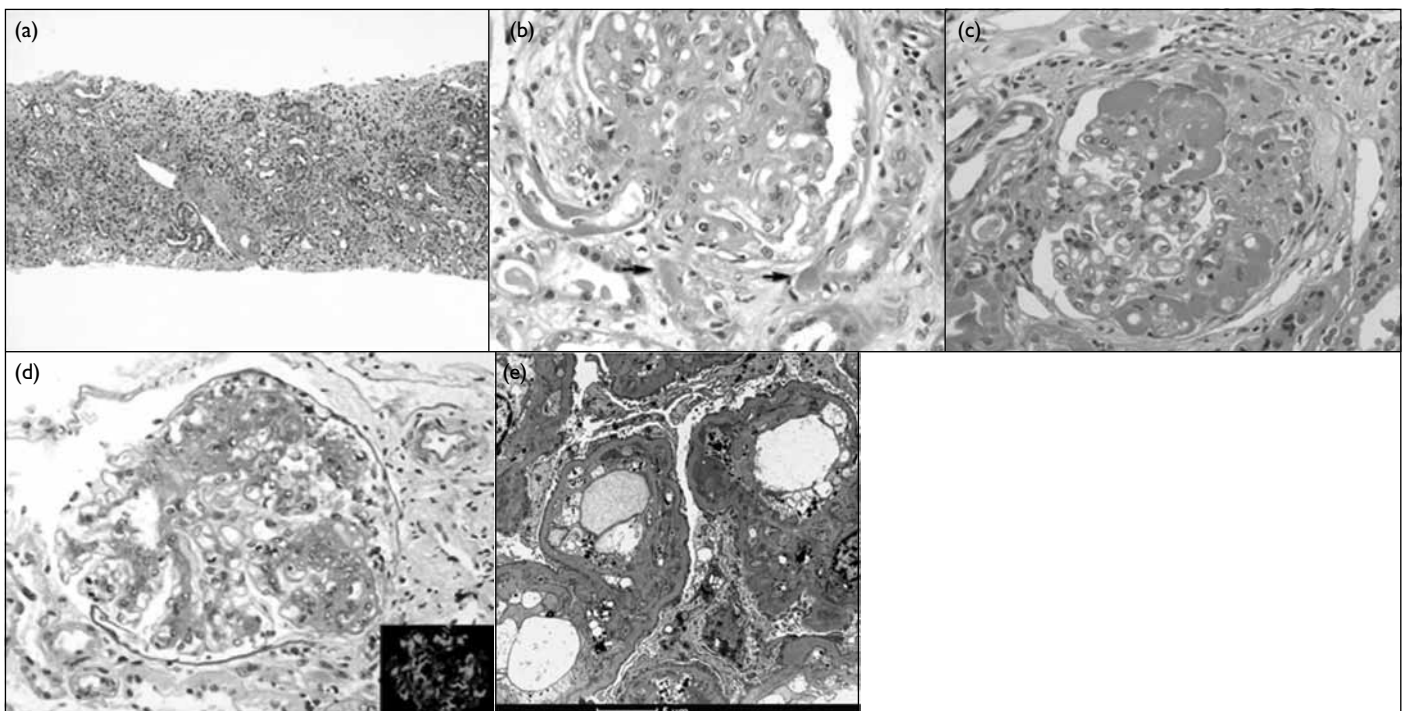
Moderate-to-marked degree of interstitial fibrosis and tubular atrophy were common, being present in nine biopsies. Arteriolar hyalinosis was also noted in the renal biopsies of nine patients, all of whom had diabetes mellitus and/or hypertension after LT (Fig 1a). One patient had nodular hyalinosis involving the media and adventitia of renal arterioles, associated with myocyte vacuolation and degeneration, in which the features were consistent with chronic CNI vasculopathy (Fig 1b).

Regarding the glomerular lesions, six renal biopsies showed diabetic glomerulosclerosis; Figure 1c shows its characteristic features. The glomerulus showed increase in mesangial matrix. Characteristic exudative lesions with large intracapillary hyaline deposits ('fibrin caps'), which sometimes contain lipid, were found. Ultrastructural study revealed diffusely thickened basement membranes and increase in mesangial matrix.

Immune complex (IC) nephritis was evident in five biopsies, namely IgA nephropathy (n=4) and membranoproliferative glomerulonephritis (MPGN; n=1). Figure 1d illustrates the characteristic features of IgA nephropathy, there being a variable degree of

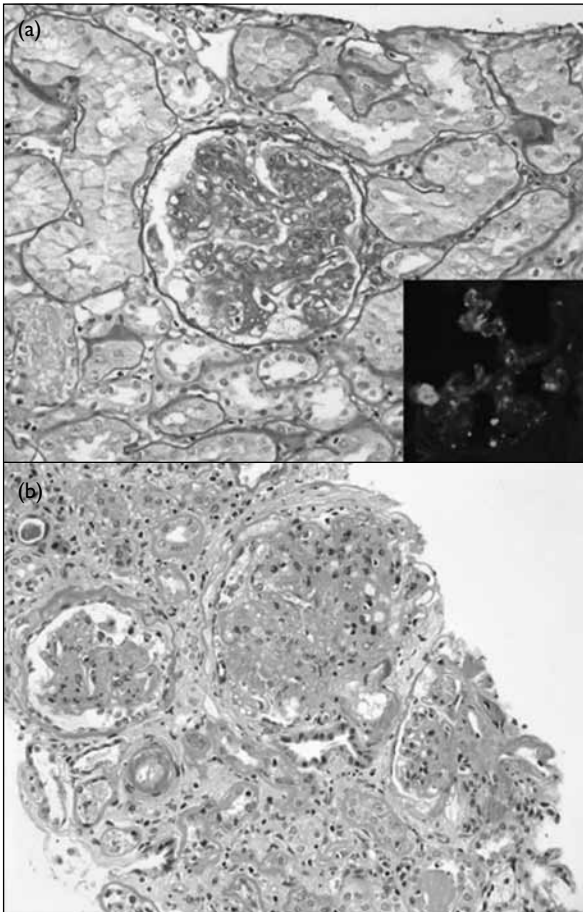
expansion of the mesangial matrix and increase in mesangial cellularity. Immunofluorescence studies showed heavy deposits of IgA in the mesangium, and ultrastructural study confirmed the presence of electron dense IC deposits in the mesangium and paramesangium. The biopsy of patient 8 revealed cellular crescents affecting 50% of the glomeruli. In two patients, IgA nephropathy co-existed with diabetic glomerulopathy and hypertensive nephrosclerosis. The biopsy of the patient with MPGN showed typical mesangial interpositioning, duplication of the GBM producing double contours, and subendothelial IC electron dense deposits (Fig 1e).

Patient 5 had LT for liver cirrhosis due to chronic HBV infection, and presented with nephrotic syndrome and heavy proteinuria (14 g/day) 4 months later. Renal biopsy showed IgA nephropathy with no significant interstitial fibrosis or tubular atrophy (Fig 2a). On ultrastructural study, there were IC-type electron dense deposits in the mesangium. The GBM was not thickened, therefore diabetic glomerulopathy was considered absent. His renal function slowly deteriorated with creeping up of the serum creatinine level. A repeat renal biopsy 90 months later revealed diabetic glomerulopathy (Fig 2b), with no evidence



**FIG 1. Renal histopathology after liver transplantation**

(a) Significant interstitial fibrosis, tubular atrophy, arterial hyalinosis, and intimal fibrous thickening are common lesions (H&E; original magnification, x 40; patient 10). (b) Calcineurin inhibitor nephrotoxicity—the arterioles show marked hyalinosis. Hyaline deposits in the media with nodular appearance (arrows), associated with vacuolar degeneration in myocytes, are highly characteristic (PAS; original magnification, x 400; patient 1). (c) Diabetic glomerulopathy—the glomerulus shows hyalinosis (exudative) lesions which contain lipid (H&E; original magnification, x 200; patient 2). (d) Immunoglobulin A (IgA) nephropathy—a glomerulus shows expansion of mesangial matrix and increase in mesangial cellularity (PAS; original magnification, x 200; patient 7). Immunofluorescence study shows strong granular IgA deposits in the mesangium (inset; original magnification, x 200, patient 7). (e) Mesangioproliferative glomerulonephritis—electron photomicrograph shows mesangial interpositioning and subendothelial electron dense deposits (original magnification, x 2950; patient 10)



**FIG 2. Patient 5**  
 (a) First renal biopsy shows immunoglobulin A (IgA) nephropathy. Mesangial proliferation is apparent in the glomerulus (PAS; original magnification, x 100). Immunofluorescence study shows mesangial granular IgA deposits (inset; original magnification, x 200). (b) Renal biopsy repeated 90 months later shows diabetic nephropathy. Arteriolar hyalinosis was prominent, involving both afferent and efferent arterioles of the glomerulus on the right (PAS; original magnification, x 100)

of IC deposition in immunofluorescence and ultrastructural studies. The patient developed ESRF after 3 months and started haemodialysis.

## Discussion

The present study involved 11 renal biopsies from 740 liver transplant patients, giving a rate of 1.5%, which was similar to that in other series.<sup>4,11</sup> Interstitial fibrosis and tubular atrophy were consistently present. Not surprisingly, before LT all of our patients suffered from cirrhosis that was predominantly due to chronic HBV infection. Around 90% of the renal biopsies in patients with cirrhosis show chronic tubulointerstitial injury,<sup>12</sup> and such lesions persist after LT. It is difficult to discriminate newly acquired post-transplant changes from the wide range of changes described as common before LT. For patient 1, the diabetic changes evident within 2 years of LT might have

existed pre-transplant, but appeared to be aggravated after the transplant. Thereafter, he had progressive disease and developed ESRF. Both IC-mediated and non-IC-mediated renal injuries were apparent in the patients. Evidently, IC glomerulonephritis takes the form of IgA nephropathy and MPGN, and both are known to be associated with chronic liver disease. The non-immunological lesions included arteriolar hyalinosis, diabetic glomerulopathy, and hypertensive nephrosclerosis. Most of our renal biopsies had more than one pathological lesion, a finding also reported by other investigators.<sup>4,8-10</sup>

While many previous studies showed the complex, multifactorial nature of renal injuries after LT,<sup>2,4,8-10</sup> the underlying causes were not explored. Although our study was limited by the small number of patients, in view of the spectrum of renal lesions encountered we believe at least some of them may have been related to metabolic derangement after LT. Development of post-transplant metabolic syndrome (PTMS)—which includes impaired glucose tolerance, hypertension, dyslipidaemia, and obesity—has become a growing concern.<sup>13-15</sup> It was beyond the scope of this study to evaluate metabolism before and after LT, though PTMS is reported to occur in 43 to 58% of post-transplant patients and is probably related to the effects of immunosuppressive drugs.<sup>13-15</sup> The return to normal daily life, free food intake, and normalisation of the hypermetabolic state of advanced liver disease are confounding factors.<sup>13</sup> The syndrome is believed to increase the risk of cardiovascular disease,<sup>13-15</sup> and may account for conditions such as arteriolar hyalinosis, diabetic nephropathy and hypertensive nephrosclerosis, which are frequently observed in the biopsies. As five patients already had metabolic derangement before LT, we believe that aspects of the renal injuries might have been sustained earlier. In recent years, achieving tolerance to the withdrawal of immunosuppression has been a major goal after LT.<sup>16,17</sup> An awareness of PTMS should alert our transplant surgeons and nephrologists on the feasibility of weaning patients from immunosuppression. A larger sample size and multivariate analysis may clarify the role of PTMS in such renal pathology.

Notably, patient 5 who had IgA nephropathy after LT had a repeat renal biopsy 90 months later. This revealed diabetic nephropathy as the cause of his ESRF. Thus, renal lesions due to metabolic derangements can supervene on established IC glomerulonephritis as a late cause of renal impairment, and should not be ignored/underestimated. This case illustrates the pathological heterogeneity and temporal dynamics of renal lesions in LT recipients, and reinforces the need for constant surveillance.

Contrary to the classical concept that in LT patients CNI is the probable cause of renal



failure,<sup>1,3,5-7,11</sup> such nephrotoxicity (nodular hyalinosis involving the vessel wall) is a rare feature in biopsies. This finding concurs with a recent large study by Kim et al,<sup>8</sup> who found that only 16% of patients had evidence of CNI toxicity in their 81 post-LT renal biopsies. Routine monitoring of serum drug levels and modification of immunosuppressive therapy before renal biopsy could help select patient subgroups with a lower risk of CNI toxicity. Sampling error was also a possibility, quite apart from the somewhat vague diagnostic criteria of 'chronic CNI nephropathy'. Striped interstitial fibrosis, arteriolar hyalinosis and glomerular sclerosis—once regarded as pathological hallmarks of chronic CNI nephrotoxicity—are being challenged and regarded as non-specific.<sup>18</sup> In view of the frequent presence of interstitial fibrosis, arteriolar hyalinosis and glomerular sclerosis in post-LT patients, we and Kim et al<sup>8</sup> only regard nodular hyalinosis of arteries as definitively indicative of CNI nephrotoxicity.

The outlook of LT patients who need to be investigated by renal biopsy is not good. After a mean follow-up of 53 months post-renal biopsy, all the patients had chronic renal impairment, and five developed ESRF and three died. Such data were comparable to those from western series. In a cohort of 26 LT recipients with a mean follow-up of 6 years post-renal biopsy, 12 patients were on dialysis and all but one suffered from chronic renal failure.<sup>9</sup> In a

similar study of renal biopsies on 81 LT recipients,<sup>8</sup> five died and 11 were on renal replacement treatment after a median follow-up of 20 months. Thus, the outlook of LT patients having kidney biopsies was worse than that of post-LT patients with chronic renal failure (~18%)<sup>1</sup> and ESRF (<4%).<sup>2</sup> The survival of these LT patients also compared unfavourably in terms of overall long-term drop-out (death and loss to follow-up) rates of all Hong Kong LT recipients (131/890, 15%).

## Conclusion

We report the long-term clinicopathological findings of 10 patients having 11 renal biopsies after LT. The renal pathological features in the kidneys were very often heterogeneous. The most common renal lesions included interstitial fibrosis/tubular atrophy, arteriolar hyalinosis, diabetic glomerulopathy, and IgA nephropathy. On follow-up, there was a significant risk of chronic renal failure and mortality. Pathologists and nephrologists should attend to the renal lesions related to metabolic derangement when evaluating renal biopsies in LT patients.

## Acknowledgement

The authors would like to thank Ms Banny KY Lam, Department of Surgery, Queen Mary Hospital, for her data collection in this study.

## References

- Ojo AO, Held PJ, Port FK, et al. Chronic renal failure after transplantation of a nonrenal organ. *N Engl J Med* 2003;349:931-40.
- Lynn M, Abreo K, Zibari G, McDonald J. End-stage renal disease in liver transplants. *Clin Transplant* 2001;15 Suppl 6:66S-69S.
- Neau-Cransac M, Morel D, Bernard PH, et al. Renal failure after liver transplantation: outcome after calcineurin inhibitor withdrawal. *Clin Transplant* 2002;16:368-73.
- O'Riordan A, Dutt N, Cairns H, et al. Renal biopsy in liver transplant recipients. *Nephrol Dial Transplant* 2009;24:2276-82.
- Iwatsuki S, Starzl TE, Todo S, et al. Experience in 1000 liver transplants under cyclosporine-steroid therapy: a survival report. *Transplant Proc* 1988;20:498-504.
- Platz KP, Mueller AR, Blumhardt G, et al. Nephrotoxicity after orthotopic liver transplantation in cyclosporin A and FK 506-treated patients. *Transpl Int* 1994;7 Suppl 1:S52-7.
- O'Grady JG, Forbes A, Rolles K, Calne RY, Williams R. An analysis of cyclosporine efficacy and toxicity after liver transplantation. *Transplantation* 1988;45:575-9.
- Kim JY, Akalin E, Dikman S, et al. The variable pathology of kidney disease after liver transplantation. *Transplantation* 2010;89:215-21.
- Pillebout E, Nochy D, Hill G, et al. Renal histopathological lesions after orthotopic liver transplantation (OLT). *Am J Transplant* 2005;5:1120-9.
- Kamar N, Guilbeau-Frugier C, Servais A, et al. Kidney histology and function in liver transplant patients. *Nephrol Dial Transplant* 2011;26:2355-61.
- Schwarz A, Haller H, Schmitt R, et al. Biopsy-diagnosed renal disease in patients after transplantation of other organs and tissues. *Am J Transplant* 2010;10:2017-25.
- Trawalé JM, Paradis V, Rautou PE, et al. The spectrum of renal lesions in patients with cirrhosis: a clinicopathological study. *Liver Int* 2010;30:725-32.
- Laish I, Braun M, Mor E, Sulkes J, Harif Y, Ari ZB. Metabolic syndrome in liver transplant recipients: prevalence, risk factors, and association with cardiovascular events. *Liver Transpl* 2011;17:15-22.
- Laryea M, Watt KD, Molinari M, et al. Metabolic syndrome in liver transplant recipients: prevalence and association with major vascular events. *Liver Transpl* 2007;13:1109-14.
- Pagadala M, Dasarathy S, Eghtesad B, McCullough AJ. Posttransplant metabolic syndrome: an epidemic waiting to happen. *Liver Transpl* 2009;15:1662-70.
- Londoño MC, López MC, Sánchez-Fueyo A. Minimization of immunosuppression in adult liver transplantation: new strategies and tools. *Curr Opin Organ Transplant*. Epub 2010 Sep 30.
- Takatsuki M, Uemoto S, Inomata Y, et al. Weaning of immunosuppression in living donor liver transplant recipients. *Transplantation* 2001;72:449-54.
- Chapman JR. Chronic calcineurin inhibitor nephrotoxicity—lest we forget. *Am J Transplant* 2011;11:693-7.