

# Endobronchial ultrasound-guided transbronchial needle aspiration in lung cancer: the first experience in Hong Kong

CME

Matthew KY Wong 黃敬恩  
James CM Ho 何重文  
Florence Loong 龍杏林  
David CL Lam 林志良  
WM Wong 黃慰梅  
Terence CC Tam 譚子雋  
L Han 韓 鵬  
Mary SM Ip 葉秀文



A video of endobronchial ultrasound-guided transbronchial needle aspiration in lung cancer is available at <[www.hkmj.org](http://www.hkmj.org)>.

**Objective** To investigate the diagnostic performance and safety of endobronchial ultrasound-guided transbronchial needle aspiration in patients presenting with radiological features of lung cancer.

**Design** Prospective case series.

**Setting** University teaching hospital, Hong Kong.

**Patients** Consecutive patients with mediastinal or hilar abnormalities suspected of or confirmed as having lung cancer underwent endobronchial ultrasound-guided transbronchial needle aspiration and presented between August 2006 and December 2010.

**Main outcome measures** Diagnostic performance (including sensitivity, specificity, negative predictive value and accuracy), procedural complications, and tissue adequacy for molecular profiling.

**Results** A total of 269 procedures were performed in 259 patients, with malignancy confirmed in 210 (81%) of them. In the whole cohort with confirmed or suspected lung cancer, the overall sensitivity, specificity, negative predictive value, and accuracy of endobronchial ultrasound-guided transbronchial needle aspiration were 87%, 100%, 74%, and 91%, respectively. Among 42 patients with tumour samples sent for mutation tests (epidermal growth factor receptor and/or anaplastic lymphoma kinase), 40 (95%) were found to be adequate. No complication or mortality ensued from these procedures.

**Conclusion** Endobronchial ultrasound-guided transbronchial needle aspiration is highly effective in determining the diagnosis and lymph node staging in patients with lung cancer. In combination with its excellent safety profile, it should be considered a frontline diagnostic test for patients presenting with mediastinal abnormalities suspicious of lung cancer.

## Key words

Biopsy, fine-needle; Bronchoscopy; Lung neoplasms; Neoplasm staging; Sensitivity and specificity

*Hong Kong Med J* 2013;19:20-6

The University of Hong Kong, Queen Mary Hospital, Pokfulam, Hong Kong:

Department of Medicine

MKY Wong, MB, BS, FRCP

JCM Ho, MD, FRCP

DCL Lam, MB, BS, PhD

WM Wong, MB, BS, MRCP

TCC Tam, MB, BS, MRCP

L Han, BMed, MPhil

MSM Ip, MD, FRCP

Department of Pathology

F Loong, MB, BS, FRCPA

Correspondence to: Dr JCM Ho  
Email: [jhocm@hku.hk](mailto:jhocm@hku.hk)

## New knowledge added by this study

- Endobronchial ultrasound-guided transbronchial needle aspiration (EBUS-TBNA) carries high diagnostic accuracy for lung cancer in Hong Kong.
- The safety of EBUS-TBNA has been well-demonstrated in our local setting.

## Implications for clinical practice or policy

- EBUS-TBNA should be considered as one of the upfront investigations-of-choice for suspected lung cancer.

## Introduction

When there is an abnormal lung lesion evident on radiological examination, the next step is to establish the diagnosis and accurately determine its stage if lung cancer is suspected. Both computed tomography (CT) and positron emission tomography (PET) are effective in localising the primary lesion and any metastatic foci. However, pathological confirmation remains the gold standard, especially in Hong Kong, where tuberculosis is endemic and not uncommonly masquerades as malignancy.

Conventional flexible fiberoptic bronchoscopy (FOB) is useful in the diagnosis of endobronchial lesions, but many lung cancers are extraluminal and thus invisible

during bronchoscopy. Because of the extensive branching and angulation of the lower bronchial tree, the diagnostic yield of FOB coupled with fluoroscopy-guided transbronchial lung biopsy (TBLB) is still suboptimal for parenchymal lung lesions, and depends on the lesion's size and location. Conventional transbronchial needle aspiration (TBNA) without image guidance has high diagnostic yield for lesions adjacent to the airway, but has been underutilised in most parts of the world including Hong Kong, partly due to reported serious complications such as bleeding and pneumothorax.<sup>1-3</sup> Alternatively, CT-guided needle aspiration is useful in the diagnosis of peripheral lung lesions but carries significant risks of a pneumothorax (25%) and having a chest tube inserted (5%).<sup>4,5</sup> Pathological lymph node staging of the mediastinum remains unattainable with both TBLB and CT-guided needle biopsy.

Recently, endobronchial ultrasound-guided transbronchial needle aspiration (EBUS-TBNA) has been shown to be a highly accurate and safe procedure for the diagnosis and staging of patients with confirmed or suspected lung cancer.<sup>6,7</sup> The procedure can be incorporated with conventional FOB in a single bronchoscopic session using local anaesthesia. This can provide adequate tissue to assess epidermal growth factor receptor (EGFR) mutation status to guide treatment with modern targeted oral therapeutic agents.<sup>8</sup> Since the first introduction of EBUS-TBNA in Hong Kong in 2005, the technology has now become widely available in the community. As pioneers in adopting this new technology locally, we describe the first experience of EBUS-TBNA in Hong Kong and discuss its role in comparison with currently available alternatives.

Thus, the aim of this study was to define the overall diagnostic performance of EBUS-TBNA in the setting of suspected or confirmed lung cancer, as well as according to the final diagnoses including malignancy and infection. The performance of EBUS-TBNA as the first pathological diagnostic test was also defined.

## Methods

### Recruitment and procedure of endobronchial ultrasound-guided transbronchial needle aspiration

This study was performed prospectively between August 2006 and December 2010, allowing at least 1 year of clinical follow-up at the time of analysis. Queen Mary Hospital was the first centre in Hong Kong that provided EBUS-TBNA with the approval from the Hospital Authority. All patients having confirmed or suspected lung cancer referred for EBUS-TBNA with enlarged (short diameter >1 cm) mediastinal/hilar lesions or lung lesions closely abutting adjacent

## 支氣管內超聲引導針吸活檢術作肺癌診斷： 香港的初步經驗

**目的** 探討支氣管內超聲引導針吸活檢術為有肺癌放射特徵的病人作診斷的表現以及安全性。

**設計** 前瞻性病例系列。

**安排** 香港一所大學教學醫院。

**患者** 因縱隔或肺門異常被懷疑或確診肺癌而於2006年8月至2010年12月期間接受支氣管內超聲引導針吸活檢術的所有患者。

**主要結果測量** 診斷表現（包括敏感性、特異性、陰性預測效度及準確度）、手術併發症及用作分子分析的組織量是否足夠。

**結果** 259位病人中（269例）有210人（81%）確診患有惡性腫瘤。在懷疑或確診肺癌病例中，支氣管內超聲引導針吸活檢術的總敏感性為87%、特異性100%、陰性預測效度74%、和準確度91%。把42人的腫瘤樣本作突變測試（表皮生長因子受體和/或間變性淋巴瘤激酶），發現40人（95%）的組織樣本是足夠的。整個過程中並無任何併發症或死亡病例。

**結論** 支氣管內超聲引導針吸活檢術對於肺癌的診斷和淋巴結分期相當有效。由於整個程序有非常良好的安全性，前線人員應利用此技術作診斷縱隔異常的懷疑肺癌患者。

airways on CT (with or without PET confirmation) were recruited. If the target lesion was subcentimetre on CT and yet <sup>18</sup>F-fluorodeoxyglucose avid on PET, EBUS-TBNA was also considered. All the procedures were performed by a chief operator (MKW) who received relevant training in year 2005 and launched the EBUS-TBNA service in Queen Mary Hospital from 2006. The abnormal lymph node stations as detected by CT scan and/or PET were taken as reference. If more than one lymph node station was involved, the procedure was performed in the order N3 to N1 node, according to the seventh edition of the American Joint Committee on Cancer cancer staging manual. Contra-indications and preparations were the same as for patients undergoing FOB with biopsy intent, and included having a medically unstable condition, bleeding diathesis, and lack of consent. The procedures were performed under conscious sedation with midazolam and pethidine used intravenously, in addition to local anaesthesia. The specially designed EBUS scope (XBFUC260F-OL8; Olympus, Tokyo, Japan) had the curvilinear transducer incorporated at the tip with an outer diameter of 6.7 mm. It was administered trans-orally. A saline-inflated balloon kept the probe in contact with the bronchial wall while sampling the lymph node. The system had an integrated colour

Doppler function, with enhanced visualisation of blood vessels to prevent inadvertent puncturing. A dedicated 22-gauge fine needle was deployed to perform TBNA under direct visualisation, so that the excursion of the needle within the lesion could be maximised and large histological cores could be obtained. Rapid-on-site cytological examination (ROSE) was not available in our centre and the procedure was stopped if no satisfactory specimen was obtained after five needle passes per lesion. All specimens were sent for histological (preserved in 10% buffered formalin), cytological (fixed in 50% alcohol), and microbiological examinations (acid-

fast bacilli and fungi). Molecular profiling, namely EGFR mutation tests, were analysed for those with confirmed adenocarcinoma from October 2008 when the test became commonly adopted. Conventional FOB was carried out if indicated. Chest radiography was performed after the patients were transferred back to the wards to exclude pneumothorax. Procedure-related complications such as excessive bleeding, infection, pneumothorax, and respiratory failure warranting intervention were to be recorded.

Written informed consent was obtained from all study patients, and the study was approved by the Institutional Review Board of the University of Hong Kong/Hospital Authority Hong Kong West Cluster (HKU/HA HKW IRB: UW 06-236T/1261).

### Statistical analyses

In this study, diagnostic performance was procedure-based. A positive result was defined if a specific diagnosis (eg carcinoma or tuberculosis) was made, without the need for surgical diagnostic intervention. A negative result referred to proceeding to further investigation (eg mediastinoscopy or thoracotomy), which was always undertaken unless the patient was unfit for such a procedure or declined it. A false-negative result was defined as no specific diagnosis until further investigation yielded positive findings from the target area or follow-up eventually confirmed a positive diagnostic result in the area of interest. True negative was defined as a biopsy being confirmed as negative after surgical exploration, or unremarkable follow-up for at least 1 year. The diagnostic yield including sensitivity (true positives/[true positives + false negatives]), negative predictive value (true negatives/[true negatives + false negatives]), and accuracy ((true positives + true negatives)/[true positives + true negatives + false positives + false negatives]) were calculated. Taking the pathological or microbiological diagnosis revealed by EBUS-TBNA as the gold standard, false positives were assumed to be absent.

Skewed continuous and normally distributed variables were presented as medians (ranges), and means and standard deviations (SDs), respectively.

## Results

### Clinical and demographic characteristics

Over the study period of 4 years and 4 months, there were 269 EBUS-TBNAs performed in 259 patients, which included three who had repeat procedures to confirm the diagnosis. Seven patients who had first EBUS-TBNA-confirmed lung cancer underwent mediastinal restaging by EBUS-TBNA after neoadjuvant therapy. The median age of these 259 patients was 62 (range, 24-86) years; all were Asians and there was a predominance of males (63%). The

TABLE 1. Characteristics of 259 patients undergoing endobronchial ultrasound-guided transbronchial needle aspiration (EBUS-TBNA)

Characteristic	Median (range) or No. (%) of patients
Age (years)	62 (24-86)
Gender	
Male	164 (63%)
Female	95 (37%)
Final diagnosis of malignancy	210 (81%)
Diagnosed by EBUS-TBNA	158 (75%)
No. of patients with underlying malignancy	95 (37%)
Lung cancer, previously treated	26 (27%)
Head and neck cancer	23 (24%)
Breast cancer	20 (21%)
Gastro-intestinal cancer	13 (14%)
Urological cancer	8 (8%)
Hepatocellular carcinoma	6 (6%)
Gynaecological cancer	5 (5%)
Lymphoma	4 (4%)
Duration of malignancy prior to EBUS-TBNA (years)	3.8 (0-32)

TABLE 2. Characteristics of 269 lesions sampled by endobronchial ultrasound-guided transbronchial needle aspiration\*

Characteristic	Mean $\pm$ SD or No. (%) of patients
Lymph node size on CT scan (cm)	1.36 $\pm$ 0.61
Lymph node sites with sample taken	
Mediastinal	231 (86%)
Right paratracheal	158 (59%)
Left paratracheal	52 (19%)
Subcarinal	165 (61%)
Hilar/interlobar	94 (35%)
Lung lesion size in long diameter (cm)	5.0 $\pm$ 3.0
Lung lesion sampled	38 (14%)
No. of needle passes per site	2.69 $\pm$ 1.11
No. of sites sampled per patient	2.00 $\pm$ 1.00

\* CT denotes computed tomography, and SD standard deviation

prevalence of confirmed malignancy in this cohort was 81% (210 patients), among whom malignancy was revealed in specimens obtained by EBUS-TBNA in 158 (75%; Table 1). The characteristics of the lesions sampled are shown in Table 2. Regarding the 269 EBUS-TBNA procedures performed, 38 (14%) had lung lesions sampled, of which 29 (76%) were found to be diagnostic. Whereas, 231 (86%) of these procedures entailed mediastinal lymph node sampling and 94 (35%) entailed hilar/interlobar lymph node sampling. The right paratracheal and subcarinal lymph nodes were the most commonly sampled, and accounted

for 59% and 61% of all such sampling, respectively (Fig 1).<sup>9</sup> The size of the lymph nodes sampled had a mean diameter of 1.36 cm (SD, 0.61 cm). Before their EBUS-TBNA procedure, results from PET were only available in 122 (45%) of the patients. Among the group with non-diagnostic EBUS-TBNA findings, there were 30 patients who underwent subsequent surgical exploration, and three had a second EBUS-TBNA. The remaining 60 patients were clinically followed up only. Among the latter, there were 33 with no evidence of malignancy during a mean follow-up duration of 1.7 (SD, 1.3) years (Fig 2).

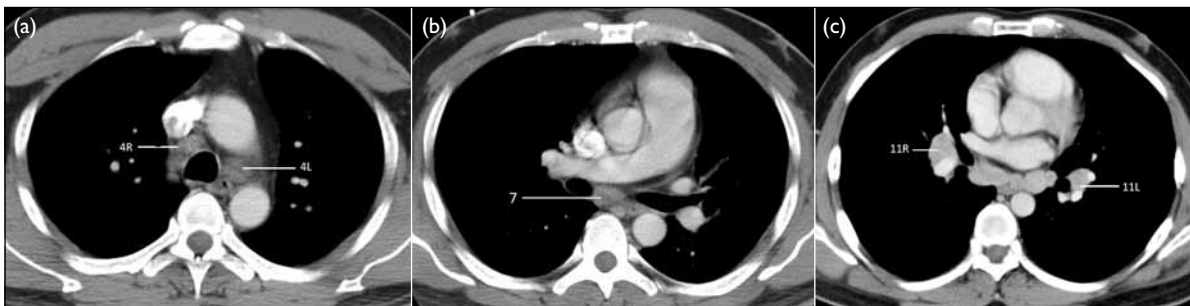

FIG 1. Computed tomographic scans of the typical location of lymph nodes sampled by endobronchial ultrasound-guided transbronchial needle aspiration

Based on the 7th edition of the Cancer Staging Manual and Stage Grouping of Lung Cancer<sup>9</sup>: (a) 4R denotes right lower paratracheal lymph node, and 4L left lower paratracheal lymph node. (b) 7 denotes subcarinal lymph node. (c) 11R denotes right interlobar lymph node, and 11L left interlobar lymph node

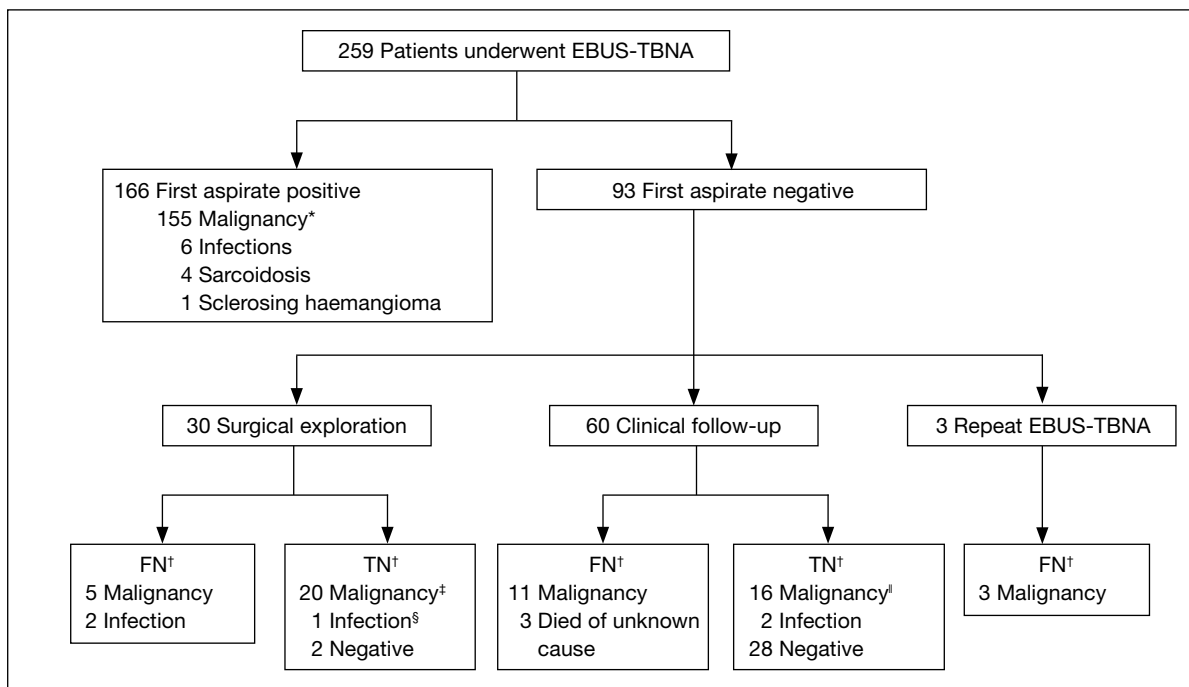


FIG 2. Flowchart for patients with suspected lung cancer with enlarged mediastinal lymph nodes who underwent endobronchial ultrasound-guided transbronchial needle aspiration (EBUS-TBNA) and follow-up. Patients were categorised by final diagnoses

\* Including 7 patients with repeat EBUS-TBNA for restaging after neoadjuvant therapy. After restaging by second EBUS-TBNA and confirmed by surgery, 4 of them were true positives, 2 were true negatives, and 1 was false negative

† FN and TN refer to the outcome of the first EBUS-TBNA; FN denotes false negative, and TN true negative

‡ Confirmed no pathological lymph node at surgery. Final diagnosis of malignancy confirmed in lung or other primary sites

§ Confirmed active pulmonary tuberculosis with reactive lymph node at surgery

¶ Confirmed malignancy in primary sites (lung, head, and neck) and received local radiotherapy. Previous EBUS-TBNA sampled lymph nodes showed no interval change during clinical follow-up

### Diagnostic performance

The diagnostic performance of these 269 EBUS-TBNA procedures resulted in a sensitivity, specificity, negative predictive value, and accuracy of 87% (173/[173+25]), 100%, 74% (71/[71+25]), and 91% ([173+71]/269), respectively. In the 220 procedures yielding a final diagnosis of malignancy, the respective sensitivity and negative predictive values were 89% (162/[162+20]) and 66% (38/[38+20]). Regarding the lesions that turned out to be infections (10 cases of tuberculosis and 1 of cryptococcosis), though lung cancer was suspected initially, the sensitivity and negative predictive values were 75% (6/[6+2]) and 60% (3/[3+2]), respectively. Regarding EBUS-TBNA used as the first diagnostic test (ie for tissue sampling), there were 158 procedures that yielded sensitivity and negative predictive values of 90% (100/[100+11]) and 81% (47/[47+11]), respectively (Table 3).

In all, 95 (37%) of the patients had a pre-existing malignancy diagnosed with a median of 3.8 years before the EBUS-TBNA. In 27 (28%) of these individuals, the pathology revealed by the procedure was other than that of the pre-existing one.

### Molecular profiling and histological classification

When EBUS-TBNA was introduced locally in 2006, molecular profiling such as for EGFR and anaplastic lymphoma kinase (ALK) was not widely accepted as standard practice. It was not until October 2008 that molecular profiling was included as routine when adenocarcinoma was diagnosed by EBUS-TBNA. Subgroup analysis was therefore performed to determine whether EBUS-TBNA was a reliable diagnostic tool for retrieving adequate tissue for EGFR or ALK mutation tests. Among 40 patients with samples sent for EGFR and/or ALK, 38 (95%) were found to be adequate. Among these, 24 (60%) harboured mutations in the *EGFR* gene exons 18-21 as detected by polymerase chain reaction and DNA sequencing and 13 (33%) were negative (wild-type), and one had the ALK translocation.

Apart from the origin of the tumour, it is now considered imperative to know the cell type within non-small-cell lung cancer (NSCLC) as chemotherapy may then be individualised. Of the 158 patients confirmed to have malignancy by EBUS-TBNA, only 22 (14%) were revealed to be NSCLC without information about the exact cell type, differentiation of the tumour, EGFR status, or primary origin of the tumour.

### Complications

Regarding all 269 procedures performed, there were no significant complications (bleeding, pneumothorax, infection, or respiratory distress) warranting reversal of sedation or any other intervention. All the patients, including 14 with superior vena caval obstruction and 1 with severe heart failure (left ventricular ejection fraction 20%), tolerated the procedures well and no procedure was prematurely terminated.

### Discussion

Most patients with lung cancer are in locally advanced or metastatic stages upon diagnosis and proper staging is important in classifying patients into operable or inoperable status.<sup>10,11</sup> In the absence of distant metastases, mediastinal lymph node staging remains the most important factor determining overall staging. Sampling of mediastinal lymph nodes is therefore important in both diagnosis and staging, which should guide subsequent treatment. The term 'personalised therapy' is coined in contrast with that in the past, when treatment for lung cancer was mainly classified into small-cell lung cancer or NSCLC only. Nowadays, among advanced stages of NSCLC, oral targeted therapy (EGFR tyrosine kinase inhibitor) is considered the preferred first-line treatment in the presence of EGFR mutations in exon 19 and 21.<sup>12</sup> Falling short of this, specific anti-cancer therapeutic options (chemotherapy and anti-angiogenic agents) are currently decided

TABLE 3. Diagnostic yield of endobronchial ultrasound-guided transbronchial needle aspiration (EBUS-TBNA)

EBUS-TBNA procedure	No. of EBUS-TBNA procedures	Sensitivity (95% CI*)	Negative predictive value (95% CI)	Accuracy
All procedures	269	87% (82-91%)	74% (64-82%)	91%
Procedures with a final diagnosis of malignancy	220	89% (84-93%)	66% (53-76%)	91%
Patients with a final diagnosis of infective cause	11	75% (41-93%)	60% (23-88%)	82%
EBUS-TBNA as the first diagnostic test	158	90% (83-94%)	81% (69-89%)	93%

\* CI denotes confidence interval

according to the carcinoma cell types, namely: small, large, adeno, or squamous.<sup>13-15</sup> In patients with pre-existing malignancy, subsequent treatment is largely dictated by differentiating metastatic disease from primary carcinoma of the lung. Based on our 4-year experience since 2006, EBUS-TBNA has demonstrated high diagnostic accuracy in providing clear-cut histological classification and molecular profiling that facilitated state-of-the-art treatment for lung cancer.

Previously, surgical intervention such as mediastinoscopy was the only diagnostic modality with access to the mediastinal lymph nodes for tissue sampling, though the hilar area remained a sanctuary site. However, surgical exploration is not usually considered the upfront diagnostic investigation, due to the need for general anaesthesia for which most patients with advanced lung cancer are not good candidates. Recourse to EBUS-TBNA opens a new diagnostic paradigm for patients having mediastinal or hilar lymphadenopathy. In our study, its diagnostic yield was close to 90%, which is similar to most clinical series reported worldwide.<sup>5,6</sup> A negative result from EBUS-TBNA (with the negative predictive value of 74% only), however, warrants further investigation and may be best explained by the sampling error associated with a fine needle.

The advantage of using EBUS-TBNA with a 22-G fine needle for sampling under real-time guidance is that it minimises inadvertent puncturing of blood vessels by the Doppler mode screening. This was exemplified by the excellent safety demonstrated in our series. Regrettably, ROSE was not available in our centre, but has the potential to reduce the number of needle passes and sites sampled per patient, and hence the complication rate. The procedural time was not recorded but was estimated to be around 20 to 50 minutes, depending on the number of lesions sampled. Recently, we have shown that EBUS-TBNA was safe even in patients with superior vena caval obstruction.<sup>16</sup> Using the fine needle does not jeopardise securing adequate pathological data required for formulating personalised treatment. Of the 210 patients confirmed as having malignancy as their final diagnosis, EBUS-TBNA was able to detect extrathoracic malignancy in 23 (11%) and primary lung cancer in 135 (64%). Among those 135 patients with confirmed primary lung cancer, 118 (87%) had the exact cell type delineated, although this could have been confounded by concomitant changes in the pathological classification and management of NSCLC during the study period. For the 40 patients who had molecular profiling, adequate tissues for

EGFR or ALK mutation tests were obtained in 38 (95%), which was much higher than the 36% reported in a recent landmark clinical trial on targeted therapy (IPASS study) using conventional diagnostic methods.<sup>17</sup> Moreover, EBUS-TBNA is useful in the diagnosis of synchronous lung cancers and other benign conditions affecting the mediastinum such as tuberculosis, fungal infection, or sarcoidosis.<sup>18-21</sup>

Endoscopic ultrasound-guided fine-needle aspiration (EUS-FNA), via the trans-oesophageal approach, was developed earlier than EBUS-TBNA and is also reported to have high diagnostic performance in mediastinal lymphadenopathy. However, EUS-FNA provides limited access to the hilum and the right side of the mediastinum. Although the inferior mediastinal nodal stations such as para-oesophageal (below the carina) and pulmonary ligament can be approached by EUS-FNA but not EBUS-TBNA, metastatic involvement in these areas is relatively uncommon. In a local study, it only accounted for about 6% of lymph nodes sampled by EUS-FNA.<sup>22</sup> Nevertheless, the combination of EBUS-TBNA and EUS-FNA has even better diagnostic performance than either procedure alone.<sup>23</sup> However, whether this combined approach can replace mediastinoscopy is yet to be elucidated.

In summary, EBUS-TBNA has been shown to have high diagnostic performance and excellent safety. Similar to other technical procedures, it requires a defined period of training. Due to the steep learning curve at the beginning, some professional bodies have recommended a minimum requirement of 25 procedures be performed annually to maintain the technical skill for EBUS proficiency.<sup>24</sup> The diagnostic yield was also associated with annual hospital EBUS-TBNA volume and reflects the combined team experience, and also involves anaesthetic use and cytopathological interpretation.<sup>25-27</sup>

In Hong Kong, EBUS-TBNA has been introduced for the past 7 years, and has emerged as an important tool in the field of interventional pulmonology, which is rapidly evolving worldwide. The management of lung cancer is greatly advanced with all these new diagnostic and therapeutic modalities in the pipeline, underscoring the importance of personalised therapy, which is the new paradigm.

## Acknowledgement

This study was partially supported by the Wu Jieh Yee Charitable Foundation Ltd, which enabled acquisition of the EBUS machine.

## References

- Harrow EM, Abi-Saleh W, Blum J, et al. The utility of transbronchial needle aspiration in the staging of bronchogenic carcinoma. *Am J Respir Crit Care Med* 2000;161:601-7.
- Wang KP, Brower R, Haponik EF, Siegelman S. Flexible transbronchial needle aspiration for staging of bronchogenic carcinoma. *Chest* 1983;84:571-6.
- Patelli M, Lazzari Agli L, Poletti V, et al. Role of fiberoptic transbronchial needle aspiration in the staging of N2 disease due to non-small cell lung cancer. *Ann Thorac Surg* 2002;73:407-11.
- Gould MK, Fletcher J, Iannettoni MD, et al. Evaluation of patients with pulmonary nodules: when is it lung cancer?: ACCP evidence-based clinical practice guidelines (2nd edition). *Chest* 2007;132(3 Suppl):108S-130S.
- Wang Memoli JS, Nietert PJ, Silvestri GA. Meta-analysis of guided bronchoscopy for the evaluation of the pulmonary nodule. *Chest* 2012;142:385-93.
- Yasufuku K, Chiyo M, Koh E, et al. Endobronchial ultrasound guided transbronchial needle aspiration for staging of lung cancer. *Lung Cancer* 2005;50:347-54.
- Herth FJ, Eberhardt R, Vilmann P, Krasnik M, Ernst A. Real-time endobronchial ultrasound guided transbronchial needle aspiration for sampling mediastinal lymph nodes. *Thorax* 2006;61:795-8.
- Garcia-Olivé I, Monsó E, Andreo F, et al. Endobronchial ultrasound-guided transbronchial needle aspiration for identifying EGFR mutations. *Eur Respir J* 2010;35:391-5.
- Lababede O, Meziane M, Rice T. Seventh edition of the cancer staging manual and stage grouping of lung cancer: quick reference chart and diagrams. *Chest* 2011;139:183-9.
- Robinson LA, Ruckdeschel JC, Wagner H Jr, Stevens CW, American College of Chest Physicians. Treatment of non-small cell lung cancer-stage IIIA: ACCP evidence-based clinical practice guidelines (2nd edition). *Chest* 2007;132(3 Suppl):243S-265S.
- Socinski MA, Crowell R, Hensing TE, et al. Treatment of non-small cell lung cancer, stage IV: ACCP evidence-based clinical practice guidelines (2nd edition). *Chest* 2007;132(3 Suppl):277S-289S.
- Keedy VL, Temin S, Somerfield MR, et al. American Society of Clinical Oncology provisional clinical opinion: epidermal growth factor receptor (EGFR) mutation testing for patients with advanced non-small-cell lung cancer considering first-line EGFR tyrosine kinase inhibitor therapy. *J Clin Oncol* 2011;29:2121-7.
- Galvani E, Peters GJ, Giovannetti E. Thymidylate synthase inhibitors for non-small cell lung cancer. *Expert Opin Investig Drugs* 2011;20:1343-56.
- Salgia R. Prognostic significance of angiogenesis and angiogenic growth factors in nonsmall cell lung cancer. *Cancer* 2011;117:3889-99.
- Kulesza P, Ramchandran K, Patel JD. Emerging concepts in the pathology and molecular biology of advanced non-small cell lung cancer. *Am J Clin Pathol* 2011;136:228-38.
- Wong MK, Tam CT, Lam DC, Ip MS, Ho JC. EBUS-TBNA in patients presented with superior vena cava syndrome. *Lung Cancer* 2012;77:277-80.
- Mok TS, Wu YL, Thongprasert S, et al. Gefitinib or carboplatin-paclitaxel in pulmonary adenocarcinoma. *N Engl J Med* 2009;361:947-57.
- Navani N, Molyneaux PL, Breen RA, et al. Utility of endobronchial ultrasound-guided transbronchial needle aspiration in patients with tuberculous intrathoracic lymphadenopathy: a multicentre study. *Thorax* 2011;66:889-93.
- Wong M, Loong F, Khong PL, Kwong YL, Leung AY. Mediastinal cryptococcosis masquerading as therapy-refractory lymphoma. *Ann Hematol* 2011;90:601-2.
- Wong M, Yasufuku K, Nakajima T, et al. Endobronchial ultrasound: new insight for the diagnosis of sarcoidosis. *Eur Respir J* 2007;29:1182-6.
- Wong MK, Wong MP, Lam DC, et al. Endobronchial ultrasound for diagnosis of synchronous primary lung cancers. *Lung Cancer* 2009;63:154-7.
- Lee YT, Lai LH, Sung JJ, Ko FW, Hui DS. Endoscopic ultrasonography-guided fine-needle aspiration in the management of mediastinal diseases: local experience of a novel investigation. *Hong Kong Med J* 2010;16:121-5.
- Vilmann P, Puri R. The complete "medical" mediastinoscopy (EUS-FNA + EBUS-TBNA). *Minerva Med* 2007;98:331-8.
- Bolliger CT, Mathur PN, Beamis JF, et al. ERS/ATS statement on interventional pulmonology. *European Respiratory Society/ American Thoracic Society. Eur Respir J* 2002;19:356-73.
- Stather DR, Maceachern P, Rimmer K, Hergott CA, Tremblay A. Validation of an endobronchial ultrasound simulator: differentiating operator skill level. *Respiration* 2011;81:325-32.
- Steinfurt DP, Hew MJ, Irving LB. Bronchoscopic evaluation of the mediastinum using endobronchial ultrasound: a description of the first 216 cases performed at an Australian tertiary hospital. *Intern Med J* 2011;12:815-24.
- Ost D, Ernst A, Lei X, et al. Diagnostic yield of endobronchial ultrasound guided transbronchial needle aspiration: results of the AQUIRE Registry. *Chest* 2011;140:1557-66.