

# Benign metastasising leiomyoma after hysterectomy and bilateral salpingo-oophorectomy

Manisha M Beck  
Bivas Biswas  
Aparajita D'Souza  
Ramani Kumar

Benign metastasising leiomyomatosis is a rare condition affecting women in the reproductive age-group with a history of uterine fibroids, who have undergone treatment by myomectomy or hysterectomy. It is characterised by development of multiple, indolent, smooth muscle tumours outside the uterus, most commonly in the lungs, and manifests several years after the uterine surgery. We describe the case of a young woman, who had undergone total abdominal hysterectomy and bilateral salpingo-oophorectomy for multiple fibroids and a right ovarian cyst. After 5 years of being on oestrogen replacement therapy, she was detected to have benign metastasising leiomyoma, for which an additional laparotomy was performed. At laparotomy, removal of the pelvic mass was associated with several complications. The metastatic lesions in the lung responded well to progestogens (megestrol acetate) alone as evidenced by regression of the lesions detected at follow-up after 6 months and 1 year.

## Case report

A 30-year-old unmarried woman, who had undergone total abdominal hysterectomy (TAH) and bilateral salpingo-oophorectomy (BSO) for multiple uterine fibroids and a right ovarian cyst 5 years earlier, presented with symptoms of irregular bleeding per vagina, pain and heaviness of the lower abdomen in September 2009. Eight years prior to TAH and BSO, she had had laparotomies at which myomectomies were carried out on two occasions. She was started on oestrogen replacement therapy following her last surgery and had been doing well for 5 years. The oestrogen replacement therapy was discontinued following her complaints and she was started on progestogens, whereupon the vaginal bleeding ceased.

She was found to have 0.15 m x 0.15 m abdominopelvic mass that was firm, non-tender and had restricted mobility. Ultrasonography (USG) evaluation elsewhere showed a 0.15 m x 0.10 m solid pelvic mass, which appeared to be causing bilateral hydronephrosis. She was advised to undergo another laparotomy to remove the mass. Routine preoperative chest radiography, however, revealed multiple, bilateral pulmonary nodules that were also confirmed by computed tomography (CT). With a diagnosis of advanced malignancy with pulmonary metastases, she was referred to the Christian Medical College and Hospital for further management in February 2010. The CT images were reviewed and the findings confirmed (Fig a). A USG-guided biopsy of the pelvic mass was reported as showing benign leiomyoma.

At laparotomy, there were two leiomyomas, measuring 0.10 m x 0.10 m and 0.08 m x 0.08 m, bunched up together and were densely adherent to posterior bladder wall and sigmoid colon. The bladder was injured inadvertently during surgery and repaired with a urologist's assistance. The patient developed consumptive coagulopathy, associated with

### Key words

Leiomyomatosis; Lung Neoplasms;  
Megestrol acetate; Progestins

*Hong Kong Med J* 2012;18:153-5

Christian Medical College and Hospital,  
Vellore, Tamil Nadu, India:  
Department of Obstetrics and  
Gynaecology  
MM Beck, MD  
B Biswas, MD, MRCOG  
A D'Souza, MD  
Department of Pathology  
R Kumar, MD, MRCPath

Correspondence to: Dr MM Beck  
Email: beckmanisha@yahoo.com

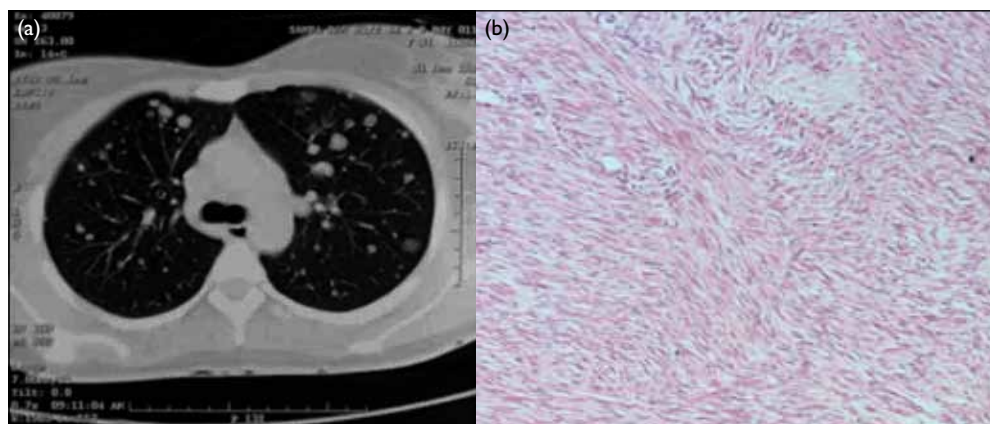


FIG. (a) Multiple, bilateral discrete pulmonary nodules on chest computed tomography. (b) Histopathology of the pelvic mass: closely packed bundles of smooth muscle cells with no cellular atypia or mitotic activity (H&E, x 20)

## 進行子宮切除術及雙側輸卵管卵巢切除術後的 良性轉移性平滑肌瘤

良性轉移性平滑肌瘤很罕見，主要影響有子宮肌瘤並已接受子宮肌瘤剔除術或子宮切除術的處於生育年齡的女性。這種病會在子宮術後幾年出現，一般發生於肺部，症狀包括在子宮外出現多個鰐伏型平滑肌腫瘤。本文報告一名年青女性因有多個肌瘤及右卵巢囊腫接受全子宮切除及雙側輸卵管卵巢切除術。患者五年來一直接受雌激素補充療法，後被發現有良性轉移性平滑肌瘤，因而進行剖腹術。術中移走盆腔內腫瘤時出現併發。在第六個月及一年的跟進當中，發現病人的肺部轉移瘤對於助孕激素（一種黃體素合成物）反應良好，腫瘤漸漸消退。

massive intra-operative blood loss (4 L), which was corrected following transfusion of blood and blood products. The abdominopelvic mass was completely excised. She was shifted to the surgical intensive care unit for postoperative care. The catheter was removed after 2 weeks and she had no voiding problems.

Cut section of the mass yielded grey and white areas that were firm in consistency, and showed a whorled pattern, similar to that of a leiomyoma. Pathology of the excised mass showed it to be a cellular leiomyoma with focal necrosis. In the multiple sections examined histologically, there was no cellular atypia or increase in mitotic activity (<1 mitotic figure/10 high-power field) to suggest malignancy (Fig b).

The patient was started on high-dose progestogens (megestrol acetate, 0.04 g thrice daily) for her pulmonary lesions. At follow-up of 6 months and 1 year later, chest X-rays showed that the nodules had regressed. The dose of megestrol was tapered down and at present she takes 0.04 g once daily. She continues to be followed up in our department every 6 months.

### Discussion

Benign metastasising leiomyomatosis (BML) was first described by Steiner in 1939.<sup>1</sup> It is now used to describe the presence of cytologically bland, mitotically inactive smooth muscle tumours in extrauterine sites, which occur in conjunction with similarly appearing or previously removed leiomyomas (at myomectomy or hysterectomy).<sup>2</sup> Although they are most commonly found in the lungs, they have also been detected in lymph nodes, skin, bones, the retroperitoneum,<sup>3</sup> the heart,<sup>4</sup> and the brain.<sup>5</sup> Much controversy surrounds the pathogenesis of BML and several mechanisms have been proposed.<sup>6</sup> These include lymphovascular embolisation; seeding from ruptured leiomyoma; metaplasia from mesothelial mesenchyme and true metastases from low-grade leiomyosarcomas of the uterus.

Most commonly patients present with pulmonary lesions, and the history reveals that years earlier the women had undergone myomectomy or hysterectomy for uterine fibroids. Moreover, like our patient, they were often started on hormone replacement therapy following TAH and BSO at a young age.<sup>6</sup> Benign metastasising leiomyomatosis has also been described following uterine artery embolisation.<sup>7</sup> Late recurrences (even after 20 years) have been reported.<sup>8</sup> Usually the patients are asymptomatic, and the lesions are often discovered incidentally. Symptoms, if present, include mild cough, dyspnoea, and flu-like illnesses. Rarely do patients progress to respiratory failure. The differential diagnosis includes primary or metastatic leiomyosarcoma, pulmonary hamartomas, primary pulmonary leiomyomas, lymphangiomyomatosis and inflammatory pseudotumours.

The pulmonary lesions tend to be bilateral, multiple, nodular, and well-circumscribed and do not display contrast enhancement on CT. The nodules show no significant metabolic activity on positron emission tomography scans. The pathology of pulmonary nodules retrieved by thoracoscopy-guided biopsy appears consistent with leiomyomas. Immunohistochemical staining is positive for oestrogen and progesterone receptors, thereby confirming their uterine origin. In the present clinical scenario, the pulmonary lesions co-existed with the pelvic mass. An USG-guided biopsy of the mass revealed a benign leiomyoma, thereby obviating the need for a thoracoscopy-guided biopsy of lung lesions.

The optimal management of BML is still unclear, and several management options have been considered (Table<sup>9-14</sup>). 'Wait-and-watch' strategy with close surveillance has been described by some, but can lead to late complications after several years.<sup>9</sup> Local excision of the lung nodules along with TAH and BSO has been described by many authors, but may not be feasible or desirable in certain situations, owing to the associated morbidity.

The growth of BML was long thought to be oestrogen-dependant, as there were reports of spontaneous regression following pregnancy or menopause.<sup>15</sup> Both surgical and medical castration have been described as effective, including treatment with selective oestrogen receptor modulators (eg raloxifene), aromatase P-450 inhibitors (eg anastrozole), and gonadotropin-releasing hormone agonists.<sup>10</sup> Some authors have described success with the use of luteinising-hormone releasing hormone analogues for treating BML.<sup>11</sup>

Varied results have been reported following treatment of BML using progestogens. Cohen and Robins<sup>12</sup> reported progressive worsening of lesions with their use and complete regression on

TABLE. Management options of benign metastasising leiomyomatosis in the literature\*

Author(s)	No. of case	Prior surgery	Age at presentation (years)	Site of metastasis	Treatment	Outcome
Hoetzenecker et al, <sup>9</sup> 2009	1	TAH	56	Lung	Expectant	Increased tumour size
Rivera et al, <sup>10</sup> 2004	1	TAH	37	Lung	Raloxifene + anastrozole	Regression
Hague et al, <sup>11</sup> 1986	1	TAH	NA	Lung	LHRH analogue	Regression
Cohen and Robins, <sup>12</sup> 1993	1	TAH	NA	Lung	Progestins (MPA followed by megestrol )	Progression
Wentling et al, <sup>13</sup> 2005	1	TAH + USO	37	Lung	Thoracotomy + progestins (megestrol)	Regression
Motegi et al, <sup>14</sup> 1993	1	TAH + USO	47	Lung	Progestins (MPA)	Regression

\* TAH denotes total abdominal hysterectomy, NA not available, LHRH luteinising-hormone releasing hormone, MPA medroxyprogesterone acetate, and USO unilateral salpingo-oophorectomy

discontinuation of therapy. On the other hand, Hague et al<sup>11</sup> reported successful outcomes after treatment with progestogens. Others, like Wentling et al,<sup>13</sup> reported complete disappearance of lung lesions with megestrol, even in the presence of intact ovarian function, having used megestrol acetate at a dose of 0.04 g thrice daily for 3 months. Motegi et al<sup>14</sup> reported regression of lung nodules with medroxyprogesterone acetate, used as a daily dose of 0.6 g for 2 years. This discordancy in response to progestogens might be related to the presence or absence of oestrogen and progesterone receptors in the lesions.

Our report describes a patient whose BML occurring following multiple surgeries for uterine leiomyomata. Occurrence following TAH and BSO has been reported sparsely in literature and hormone replacement therapy may also play a role.<sup>6</sup> At laparotomy for removal of the tumour, potential life-threatening complications ensued. We found megestrol acetate to be a simple and effective drug for treating hormone receptor-positive BML, thereby obviating the need for additional procedures like thoracotomy which are associated with increased morbidity.

## References

- Steiner PE. Metastasizing fibroleiomyoma of the uterus: Report of a case and review of the literature. *Am J Pathol* 1939;15:89-110.
- Nucci MR, Drapkin R, Dal Cin P, Fletcher CD, Fletcher JA. Distinctive cytogenetic profile in benign metastasizing leiomyoma: pathogenetic implications. *Am J Surg Pathol* 2007;31:737-43.
- Kayser K, Zink S, Schneider T, et al. Benign metastasizing leiomyoma of the uterus: documentation of clinical, immunohistochemical and lectin-histochemical data of ten cases. *Virchows Arch* 2000;437:284-92.
- Nayar AC, McAleer EP, Tunick PA, Applebaum RM, Colvin SB, Kronzon I. Benign metastasizing leiomyomatosis diagnosed by echocardiography. *Echocardiography* 2002;19:571-2.
- Kishore R, Richards AP, Evans N. Benign metastatic leiomyoma. *Clin Radiol Extra* 2004;54:29-31.
- Awonuga AO, Rotas M, Imudia AN, Choi C, Khulpateea N. Recurrent benign metastasizing leiomyoma after hysterectomy and bilateral salpingo-oophorectomy. *Arch Gynecol Obstet* 2008;278:373-6.
- Sill JM, Milkowski D, Peckham S, Jacobs D, Krivak T. A case of benign metastasizing leiomyomatosis after uterine artery embolisation [abstract]. *Chest* 2006;130:318S.
- Sargent EN, Barnes RA, Schwinn CP. Multiple pulmonary fibroleiomyomatous hamartomas. Report of a case and review of the literature. *Am J Roentgenol Radium Ther Nucl Med* 1970;110:694-700.
- Hoetzenecker K, Ankersmit HJ, Aigner C, et al. Consequences of a wait-and-see strategy for benign metastasizing leiomyomatosis of the lung. *Ann Thorac Surg* 2009;87:613-4.
- Rivera JA, Christopoulos S, Small D, Trifiro M. Hormonal manipulation of benign metastasizing leiomyomas: report of two cases and review of the literature. *J Clin Endocrinol Metab* 2004;89:3183-8.
- Hague WM, Abdulwahid NA, Jacobs HS, Craft I. Use of LHRH analogue to obtain reversible castration in a patient with benign metastasizing leiomyoma. *Br J Obstet Gynaecol* 1986;93:455-60.
- Cohen JD, Robins HI. Response of "benign" metastasizing leiomyoma to progestin withdrawal. Case report. *Eur J Gynaecol Oncol* 1993;14:44-5.
- Wentling GK, Sevin BU, Geiger XJ, Bridges MD. Benign metastasizing leiomyoma responsive to megestrol: case report and review of the literature. *Int J Gynecol Cancer* 2005;15:1213-7.
- Motegi M, Takayanagi N, Sando Y, et al. A case of so-called benign metastasizing leiomyoma responsive to progesterone [in Japanese]. *Nihon Kyobu Shikkan Gakkai Zasshi* 1993;31:890-5.
- Arai T, Yasuda Y, Takaya T, Shibayama M. Natural decrease of benign metastasizing leiomyoma. *Chest* 2000;117:921-2.