

# Intracranial electroencephalogram to evaluate refractory temporal and frontal lobe epilepsy

Lisa Au 區穎芝  
 Howan Leung 梁浩雲  
 Patrick Kwan 關國良  
 XL Zhu 朱獻倫  
 Danny TM Chan 陳達明  
 HT Wong 黃海東  
 WS Poon 潘偉生  
 Venus YH Tang 鄧如卿  
 Sam KS Ng 吳桂生  
 Deyond Siu 蕭容媛  
 Tom CY Cheung 張智欣  
 PT Choi 蔡柏達  
 KS Wong 黃家星

## Key words

Electrodes; Electroencephalography;  
 Epilepsy; Magnetic resonance imaging

*Hong Kong Med J 2011;17:453-9*

The Chinese University of Hong Kong,  
 Prince of Wales Hospital, Shatin, Hong  
 Kong;

Division of Neurology, Department of  
 Medicine and Therapeutics

L Au, MB, ChB, MRCP

H Leung, MRCP, FHKAM (Medicine)

P Kwan, FRCP, FHKAM (Medicine)

KS Wong, MD, FHKAM (Medicine)

Division of Neurosurgery, Department of  
 Surgery

XL Zhu, FRCS, FHKAM (Surgery)

DTM Chan, FRCS, FHKAM (Surgery)

HT Wong, FRCS, FHKAM (Surgery)

WS Poon, FRCS, FHKAM (Surgery)

Department of Imaging and  
 Interventional Radiology

D Siu, FRCR, FHKAM (Radiology)

TCY Cheung, FRCR, FHKAM (Radiology)

Department of Clinical Psychology,  
 New Territories East Cluster, Hospital  
 Authority, Hong Kong

VYH Tang, MSSc

SKS Ng, PhD

Department of Nuclear Medicine,  
 Pamela Youde Nethersole Eastern  
 Hospital, Chai Wan, Hong Kong

PT Choi, MRCP, FHKAM (Radiology)

Correspondence to: Dr Howan Leung  
 Email: howanleung@hotmail.com

**Objective** We undertook a collaborative study in a multidisciplinary team to channel refractory epilepsy patients to test a hypothesis about placement of intracranial electroencephalography arrays.

**Design** This was a descriptive case series. Prospective non-invasive presurgical evaluations were based on clinical semiology, magnetic resonance imaging, video-electroencephalography findings and neuropsychological assessments. If the results were discordant, a hypothesis was generated using individualised combinations of positron emission tomography, single-photon emission computed tomography, functional magnetic resonance imaging and Wada tests. The indications for intracranial electroencephalography were: (a) focal magnetic resonance imaging, ictal/interictal scalp electroencephalography with variable results (group A); (b) multi-focal magnetic resonance imaging, focal/multi-focal ictal scalp electroencephalography (group B); (c) non-lesional magnetic resonance imaging, focal/multi-focal ictal scalp electroencephalography (group C). We evaluated whether the seizure-onset zones and eloquent areas were delineated, surgical outcomes (if operated on), and pathology results.

**Setting** A tertiary referral centre for neurology in Hong Kong.

**Patients** A total of 105 refractory epilepsy patients completed non-invasive presurgical evaluations over the period 2007 to 2009. Thirty-two patients were eligible for direct resective surgery, and another 25 patients had a testing hypothesis formulated. Of these 25 patients, 10 were eligible for intracranial electroencephalography based on technical/financial considerations.

**Results** All 10 patients (group A=2, group B=4, group C=4) had their epileptogenic zones defined. Six patients underwent functional mapping, all of whom had their eloquent areas defined. Seven of the 10 patients underwent resective surgery; four of them achieved Engel class I/II outcomes. The dichotomised outcomes were 100% (group A), 50% (group B), and 33% (group C) achieving Engel class I/II. Two patients had asymptomatic subdural haematoma. There was no intracranial infection or operative mortality. In five (71%) of seven of the patients, a histological diagnosis was established.

**Conclusion** Proper deployment of intracranial electroencephalography is useful in the presurgical evaluation of patients with refractory epilepsy. This modality of management is potentially of benefit for patients with refractory epilepsy, but is underutilised locally.

## New knowledge added by this study

- Refractory epilepsy patients who have failed treatment with two appropriately selected and well-tolerated antiepileptic drugs may be considered for epilepsy surgery, even if they have multi-focal or non-lesional magnetic resonance imaging (MRI) findings, and a range of ictal and interictal (electroencephalography [EEG]) findings.
- Intracranial EEG has been successfully piloted in Hong Kong.
- With the present technological advances, seizure outcomes after surgery are best if MRI reveals a single focal lesion, as opposed to multi-focal or no lesions.

## Implications for clinical practice or policy

- Intracranial EEG is a new technique that can be developed in Hong Kong with a team of multidisciplinary professionals who can help patients with refractory epilepsy, and though presently underdeveloped, improvement and expansion in the service is foreseeable.

## 顱內腦電圖評估難治性顳葉和額葉癲癇病源

- 目的** 一跨部門小組把顱內腦電圖監察技術應用在難治性癲癇患者身上，來對一項關於此技術能成功找出癲癇病變源頭的假設進行測試。
- 設計** 本研究為一描述性病例系列。根據臨床症狀特徵、磁力共振影像（MRI）、視頻腦電圖（VEEG）結果及神經心理學評估為難治性癲癇患者作出非侵入性的術前評估。假如結果不一致，便使用個別的正電子發射型體層顯像（PET）、單光子發射電腦斷層攝影（SPECT）、功能性MRI及Wada試驗的組合來作出一項假設。分別有三組患者可以接受顱內腦電圖監測：（甲組）局灶性MRI、發作期及發作間期頭皮EEG有不同結果；（乙組）多灶性MRI、局灶性或多灶性發作期頭皮EEG；及（丙組）無病灶性MRI、局灶性或多灶性發作期頭皮EEG。本文評估顱內腦電圖監察技術是否可以準確地界定癲癇發作源頭的範圍和功能區、術後結果（如進行手術）及病理學結果。
- 安排** 香港一所腦神經科三級轉介中心。
- 患者** 從2007年到2009年，共105名難治性癲癇患者完成非侵入性的術前評估。其中32人被定為適合接受切除手術。另為25人制定測試假說，其中有10人基於技術上及財政上的考慮，可以進行顱內腦電圖監測。
- 結果** 確定了10人的致癇區，他們分別為甲組2人、乙組4人、丙組4人。6人進行功能定位以確定其功能區。10人中有7人進行切除手術；其中4人達至Engel療效分級I或II級。二分化結果為甲組100%、乙組50%、丙組33%達至Engel療效分級I或II級。兩人出現無症狀的硬膜下血腫，並無顱內感染或術中死亡。進行切除手術的7人中，4人（71%）可憑病理學結果確定腦電圖監察技術能準確地界定癲癇發作源頭的範圍。
- 結論** 顱內腦電圖監察技術可以為難治性癲癇患者成功找出癲癇病變源頭的範圍。雖然如此，本地醫院並未充分利用此項對於難治性癲癇患者有潛在診斷價值的技術。

### Introduction

Epilepsy is a common neurological disorder in Hong Kong, with an estimated prevalence of 4 per 1000 inhabitants.<sup>1</sup> Refractory epilepsy is commonly encountered by clinicians as a third of patients with epilepsy continue to have seizures despite treatment with two or more appropriately chosen antiepileptic drugs.<sup>2,3</sup> In these patients, the surgical option may be considered as the next step of modern-day treatment. In which case, prior assessment by a multidisciplinary team becomes necessary to identify the seizure focus and to evaluate cortical functions. There are over 3500 patients in Hong Kong suitable for the presurgical evaluation of refractory epilepsy, and many local sites are already offering multi-modal investigations and epilepsy surgery.<sup>4</sup> Clinicians involved with the presurgical evaluation

are faced with cases of increasing complexity, eg patients with discordant results, subtle lesions, or no lesion at all. The most widely practised presurgical evaluations involve video-electroencephalography (VEEG), magnetic resonance imaging (MRI), and neuropsychological assessment, but may not always delineate the epileptogenic zone with sufficient accuracy to enable direct resective surgery.

An emerging modality of investigation, which has remained under-developed locally, is the use of intracranial electroencephalography (EEG). It is an invasive technique based on recording EEG signals directly from the human cortex or deeper structures, and is therefore an operative procedure in its own right. Recordings may be achieved by means of subdural grids or strips of electrodes, or by using multiple-contact depth electrodes. The intracranial EEG has been considered the 'gold standard' for defining epileptogenic zones with low-amplitude fast activities as the hallmark of epileptogenicity.<sup>5</sup> As the placement of intracranial electrodes may be hypothesis driven and the recording can take up to 2 weeks to complete, close collaboration between neurologists and neurosurgeons is required. Functional mapping can be conferred by intracranial EEG, allowing meticulous delineation of important eloquent areas prior to surgery, with the comfort of an extra-operative setting for the patient and the doctor.

We piloted a collaborative study between neurologists and neurosurgeons to channel refractory epilepsy patients with a testable hypothesis towards placement of intracranial EEG arrays with the aim of proceeding to safe and effective resective surgery.

### Methods

This was a descriptive case series in which refractory epilepsy patients from a tertiary referral centre were evaluated for the latest treatment modalities in epilepsy. Data were collected using an electronic database. Refractory epilepsy may be defined as persistent seizures despite the use of two or more appropriately chosen antiepileptic drugs. For the practical purpose of undergoing video monitoring, (1) a seizure frequency of at least once per month was required and (2) the patients must consent to in-patient monitoring and antiepileptic drug tapering. Between the years 2007 and 2009, 105 patients with refractory epilepsy satisfying criteria (1) and (2) who had prospectively completed non-invasive presurgical evaluation (MRI and VEEG) were considered for direct resective surgery if the presurgical results were concordant. If the results were discordant, or if the MRI showed no lesion, a testing hypothesis was formulated, based on a combination of further investigation results, eg positron emission tomography (PET), single-photon

emission computed tomography (SPECT), functional MRI and/or Wada tests. In selected cases where technical considerations were met, funding for intracranial EEGs was solicited by the neurologists. The technical considerations were: (1) presence of an epileptogenic zone as defined by an array of strip and grid electrodes, or, depth electrodes alone; our expertise did not as yet allow the simultaneous use of all three types of electrodes owing to the complexity of the procedures; and (2) a requirement that the specific placement of electrodes for that patient would not entail an excessive risk of bleeding during monitoring. Intra-operative monitoring could be considered in place of in-dwelling electrodes in patients with a focal cortical dysplasia, where interictal discharges may provide good seizure-localising information. Extra-operative functional mapping was performed whenever the suspected epileptogenic zone was close to an eloquent area. In due course, neuropsychological assessment was conducted on all cases who received surgery. The indications for intracranial EEG were classified as follows<sup>6</sup>:

- (a) Focal MRI, ictal and interictal scalp EEG with variable results (group A)
- (b) Multi-focal MRI, focal ictal scalp EEG or multi-focal ictal scalp EEG (group B)
- (c) Non-lesional MRI, focal ictal scalp EEG or multi-focal ictal scalp EEG (group C)

The tolerability and safety of the intracranial EEG procedure were also reviewed. The outcome of patients receiving intracranial EEG was gauged in terms of the following criteria:

- (1) Proportion of patients having their seizure onset zones delineated which were otherwise missed or not confirmed based on surface data alone;
- (2) Proportion of patients having their eloquent areas delineated when operations close to such areas were imminent;
- (3) Proportion of patients receiving resective surgery and Engel class outcome assessment based on a follow-up period of 1 to 2 years (Class I: free of disabling seizures; Class II: rare disabling seizures; Class III: worthwhile improvement; Class IV: no worthwhile improvement); and
- (4) Pathological specimens from resected tissues showing a relevant tissue diagnosis.

### Results

Among 105 patients who completed the non-invasive presurgical evaluation, 32 patients were eligible for direct resective surgery and another 25 patients had a testing hypothesis formulated, based on the best available results of non-invasive investigations. Among these 25 patients, 10 were eligible for intracranial EEG using a combination of grid and strip electrodes or depth electrodes alone. Four patients did not undergo intracranial EEG as sampling would have entailed simultaneous grid and depth electrode monitoring. One patient did not undergo invasive monitoring as the bleeding risk was perceived to be too high. In 10 patients, the procedures were withheld due to financial constraints. The characteristics of the 10 patients who underwent intracranial EEGs are given in Table 1.

TABLE 1. Patient characteristics\*

Patient No. <sup>†</sup>	Age (years)	Sex	Seizure duration (years)	Seizure type	MRI	Ictal EEG	Interictal EEG	PET	SPECT	Group <sup>‡</sup>
1	34	F	14	CPS/GTC	L temporal cavernous haemangioma	L temporal	Variable	-	Normal	A
2	45	M	33	SPS/GTC	R frontal FCD	R frontal	R frontal	-	-	A
3	27	F	4	CPS/GTC	Bilateral MTS	Bilateral temporal	Variable	Bilateral temporal	-	B
4	39	M	34	CPS/GTC	Bilateral MTS	R temporal	Variable	Normal	Normal	B
5	40	F	11	CPS	Bilateral MTS	L temporal	L temporal	L temporal	L temporal	B
6	37	F	26	CPS	Bilateral MTS	R temporal	R temporal	Bilateral temporal	-	B
7	38	F	22	SPS	Normal	R frontal	L temporal	Normal	R frontal	C
8	33	F	18	CPS/GTC	Normal	L temporal	Bilateral temporal	L temporal	-	C
9	30	M	13	CPS/GTC	Normal	Bilateral temporal	Bilateral temporal	L temporal	L temporal	C
10	25	M	8	SPS/CPS	Normal	Bi-frontal	Variable	L mid frontal	L mid frontal	C

\* CPS denotes complex partial seizure, EEG electroencephalography, FCD focal cortical dysplasia, GTC generalised tonic-clonic seizure, MRI magnetic resonance imaging, MTS mesial temporal sclerosis, PET positron emission tomography, SPECT single-photon positron emission tomography, and SPS simple partial seizure

<sup>†</sup> All patients are right-handed

<sup>‡</sup> Grouping: (A) focal MRI, ictal and interictal EEG with variable results, (B) multi-focal MRI, focal or multi-focal EEG, (C) non-lesional MRI, focal or multi-focal EEG

**Indications for intracranial electroencephalography: hypothesis generation**

Based on the non-invasive presurgical results, two patients had focal MRIs, ictal and interictal scalp EEGs with variable results (group A). Four patients had multi-focal MRIs, focal ictal scalp EEGs or multi-focal ictal scalp EEGs (group B). Another four patients had non-lesional MRIs, focal ictal scalp EEG or multi-focal ictal scalp EEGs (group C). In group A, the decision for placement of grid electrodes was based solely on MRIs, although the suspected epileptogenic zone was possibly larger than the lesion itself and sampling of cortical area around the lesion was performed. In group B, three patients had bilateral mesial temporal sclerosis with a focal ictal scalp EEG and the decision for depth electrode placement was supported by further evidence from interictal PET showing unilateral hypometabolism. One patient from group B had a multi-focal MRI and multi-focal ictal scalp EEG epileptogenic foci, which were anticipated to be bilateral. The patient and family were counselled about the use of intracranial EEG to determine if the ratio of seizure onsets fell under a desirable range for consideration of surgery to decrease the seizure frequency without aiming to achieving complete freedom from seizures. In group C, two patients were without lesions but the ictal scalp EEGs were focal and concordant with either ictal SPECT or interictal PET. Two patients had no lesion discerned by multi-focal ictal scalp EEGs, but the functional imaging was so convincingly

unilateral that placement of intracranial EEG was still feasible based on ictal SPECT or interictal PET.

**Outcomes of intracranial electroencephalography**

The outcomes of the 10 patients are given in Table 2. In group A, all patients had their epileptogenic zones defined, which were essentially limited to the lesions themselves, without involvement of the surrounding cortical areas. Both patients underwent resective surgery. In group B (those with multi-focal MRI and focal ictal scalp EEGs), all patients had their epileptogenic zones defined; all were unilateral. In patients 4 and 5, the side of epileptogenic zone was opposite to the anticipated side of onset. In the only patient with multi-focal MRI and multi-focal ictal scalp EEG (patient 3), the epileptogenic zones were also proven to be bilateral (multi-focal), in keeping with the original hypothesis. Patients 5 and 6 underwent resective surgery, whilst patients 3 and 4 did not. Group C (those with non-lesional MRI and focal ictal scalp EEGs) had their epileptogenic zones defined but in one patient (patient 8), the epileptogenic zone fell near the edge of the sampled area and slightly beyond. In the two patients with non-lesional MRI and multi-focal ictal scalp EEGs, one patient had a well-defined unilateral epileptogenic zone (patient 10) and another had an essentially unilateral mesial and anterobasal onset, although dislodgement of contralateral electrode strips could not rule out bilateral epileptogenicity (patient 9). Patients 8, 9, and

TABLE 2. Patient outcomes\*

Patient No.	Group	Hypothesis	Intracranial EEG scheme
1	A	L temporal focus close to eloquent area	L temporal grid (4x8) and strip (1x6)
2	A	R frontal focus and the epileptogenic zone may reside beyond the MRI lesion	R frontal, 2 strips (1x4)
3	B	Bilateral temporal focus with a possibility of seizure onset favouring one side	Bilateral temporal depth electrodes
4	B	R temporal focus	Bilateral temporal depth electrodes
5	B	L temporal focus	Bilateral temporal depth electrodes
6	B	R temporal focus	R hippocampal depth electrode
7	C	R frontal focus	R frontal grid (8x8), 2 strips (1x6, 1x4)
8	C	L posterior temporal focus	L temporal grid (4x8), inferior temporal, 2 strips (1x4)
9	C	L temporal focus	L temporal grid (8x4), L inferior temporal, 2 strips (1x4), R temporal strip (1x4)
10	C	L frontal focus	L frontal grid (8x8), interhemispheric strip (1x4)

\* EEG denotes electroencephalography, and MRI magnetic resonance imaging

† Engel Classification — Class 1: free of disabling seizures; Class 2: rare disabling seizures; Class 3: worthwhile improvement; Class 4: no worthwhile improvement



10 underwent resective surgery but patient 7 did not (for reason given below).

During extra-operative monitoring, functional mapping was carefully performed in six patients. In one patient (patient 1), the MRI lesion was in the posterior temporal lobe of the dominant cerebral hemisphere, close to eloquent areas. Functional mapping facilitated the safe resection of the lesion without any impingement on language functions. In one patient (patient 7), the motor area for hand and thumb function was mapped and found to be overlapping with the epileptogenic zone, hence preventing the patient from undergoing resective surgery.

Based on the intracranial EEGs and functional mapping, seven (70%) patients were offered resective surgery. Overall, four (57%) patients achieved an Engel Class I/II outcome. The dichotomised outcomes in group A, B and C were 100%, 50% and 33%, respectively. Subdural haematomas associated with electrode implantation occurred in two patients but neither had a symptomatic haematoma for which emergency re-exploration was performed. In one patient, the haematoma was partly induced by self-pulling on the intracranial array resulting in a strip electrode dislodgement. No patient suffered an intracranial infection, and there was no operative mortality. In terms of functional outcomes, no patient suffered from any form of language dysfunction as a result of either implantation or surgery. At follow-up, two patients had an upper quadrantanopia detected on detailed visual

field testing, which was anticipated following their anterior temporal lobectomy. In five (71%) patients, a tissue diagnosis was established, confirming the success of epileptogenic zone localisation.

**Case 1: refractory temporal lobe epilepsy**

Patient 6 was a 37-year-old right-handed woman with a history of febrile convulsions and temporal lobe epilepsy since the age of 8 years. She had frequent complex partial seizures with oral automatism (3 times per month on average). The MRI showed bilateral hippocampal sclerosis. Scalp EEG lateralised the ictal onset to the right temporal region. Interictal PET showed bilateral temporal hypometabolism. Neuropsychological assessment confirmed impaired figurative memory and Wada test showed a language score of +0.65, representing partial left cerebral dominance (injection of the left side gave 7% baseline and injection of right side gave 44% baseline). The hypothesis was a right hippocampal focus and any resection was to be limited as far as possible to preserve memory function. Intracranial depth electrode implanted into the right hippocampus registered low-amplitude fast activities from contact points A1-A3 (anterior part of depth electrodes; Fig 1). The left hippocampus was not implanted due to the perceived risk to memory. Selective right amygdalo-hippocampectomy with minimal right anterior temporal lobectomy was performed. There was no recurrence of seizures with up to 2 years of

Intracranial EEG findings	Resection	Complication	Pathology	Engel Class†
Epileptogenic zone defined and functional mapping showed no motor/speech function	Yes (L posterior temporal lesionectomy)	No	Cavernous malformation	1
Epileptogenic zone defined and functional mapping showed no motor/speech function	Yes (R frontal lesionectomy)	No	Ganglioglioma	2
Confirmed bilateral epileptogenicity with ratio L:R = 65:9	No	-	-	-
L temporal onset	No	-	-	-
R temporal onset	Yes (R temporal lobectomy and hippocampectomy)	Haematoma	Quantity insufficient	4
R hippocampal onset	Yes (R temporal lobectomy and hippocampectomy)	No	Atrophy	1
R frontal onset and functional mapping showed overlap with R hand motor area	No	-	-	-
L temporal onset but epileptogenic zone might fall slightly beyond the edge of sampling	Yes (L temporal lobectomy and hippocampectomy)	No	No pathological lesion	2
L mesial and anterobasal onset but dislodgement of R strip electrode might overlook bilateral epileptogenicity	Yes (L temporal lobectomy and hippocampectomy)	Haematoma	Mesial temporal sclerosis	3
L anterior frontal onset and functional mapping showed no motor/speech function	Yes (L frontal lesionectomy)	No	Cortical dysplasia	1

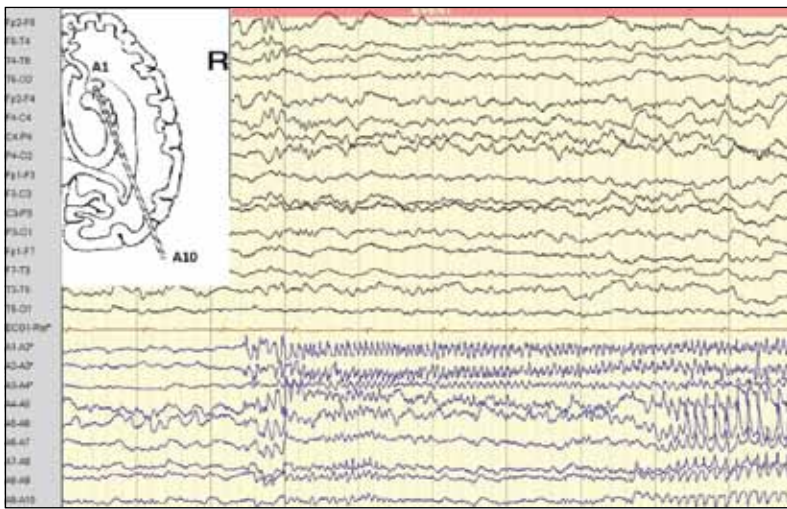


FIG 1. Depth electrode configuration and intracranial electroencephalography of patient 6

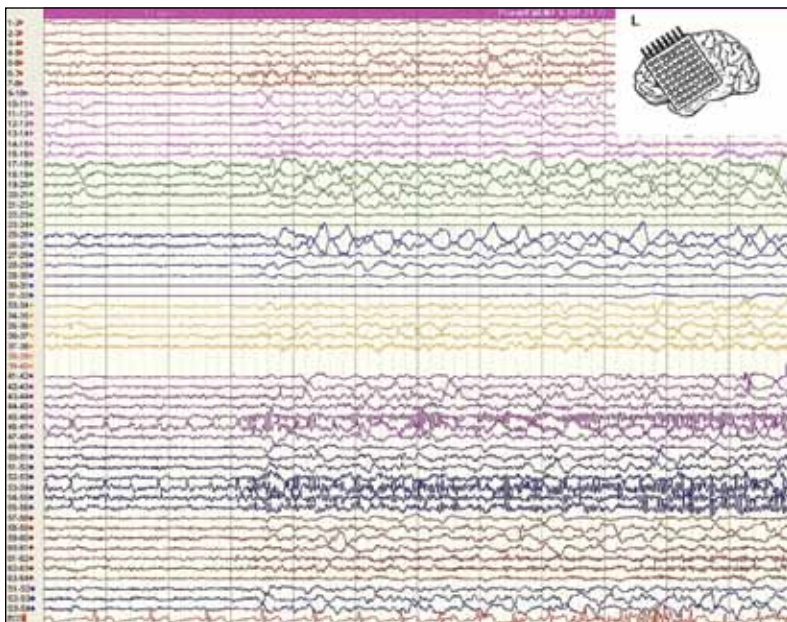


FIG 2. Grid electrode configuration and intracranial electroencephalography of patient 10

follow-up.

**Case 2: refractory frontal lobe epilepsy**

Patient 10 was a 25-year-old right-handed man with daily nocturnal complex partial seizures since the age of 17 years. Seizures were mostly in the form of brief stereotypic body flexion and extension. Scalp EEG showed bi-frontal rhythmic sharps, followed by fast activities, whereas MRI showed no lesion. Subtraction analysis of ictal SPECT suggested a seizure focus in the left frontal cortex. The hypothesis was a left anterior frontal onset and that functional mapping could facilitate safe resection of the lesion, without

impinging on motor or speech function. Left frontal craniotomy for implantation of a subdural grid and inter-hemispheric strips was performed. Intracranial EEG monitoring showed low-amplitude fast activities originating from contact points 45, 46, 53, 54 and 55, which corresponded closely to the SPECT-defined area (Fig 2). Cortical mapping around the lesion did not reveal any motor or speech function. Lesionectomy was performed and pathology showed cortical dysplasia. The patient remained seizure-free after 6 months of follow-up.

**Discussion**

The offer of intracranial EEG may be seen as a tool to maximise the probability of channeling refractory temporal and frontal lobe epilepsy patients towards surgery. The patients who may benefit from this modality of investigation will be, by the same token, those with epileptogenic zones that are difficult to define, or close to eloquent areas. Previous studies reporting outcomes of resective surgery following subdural electrode arrays<sup>7-10</sup> indicated that this group of patients also had a relatively worse outcome at the outset but this may not preclude them from receiving the work-up and the surgery as long as the perceived risk can be balanced by the perceived benefit. In the study by Kim et al,<sup>9</sup> only 42% of patients undergoing intracranial studies and resective surgery achieved seizure freedom, but the extent of resection as guided by intracranial EEGs correlated with outcomes.

The proper deployment of intracranial EEGs was closely tied to the availability of functional imaging such as interictal PET and ictal SPECT. In the current study, approximately a third of the patients could be offered surgery directly, but among the remainder only 25 had a hypothesis formulated. The cost of interictal PET, which hitherto has required out-of-pocket payments from patients and families, may be a contributing factor. As for ictal SPECT, the logistics and set-up that are required for successful ictal scans may still limit the chance of achieving hypothesis generation.

In our pilot study, paradoxically the outcome of frontal lobe epilepsy was better than that of temporal lobe epilepsy (100% vs 40% achieved Engel class I/II). The complex temporal cases that we encountered included the so-called ‘temporal-plus’ epilepsies,<sup>11</sup> in which the epileptogenic zone was thought to include the temporal lobe but may also extend beyond it in the directions of the frontal, parietal, or occipital lobes. Such non-lesional cases were highly challenging, as the placement of intracranial arrays required a fine balance between maximal sampling and minimal risk (haematoma formation and infection). The use of quantitative interictal PET (eg statistical parametric mapping) may generate better hypotheses for more

accurate placement of intracranial EEG electrodes. The result of our pilot study also demonstrated that intracranial diagnostics which contradict the original hypothesis may indicate worse surgical outcomes.

### Limitations

The current prospective pilot study had a small sample size and no statistical analysis in terms of risk factor stratification was therefore possible. The genuine yield of intracranial EEGs also remained unknown, because some individuals were not offered resective surgery after risk/benefit considerations. Hence, seizure outcome or pathological specimens may not be available to correlate with other findings in all of the cases.

### Conclusions

Intracranial EEG recording is a useful tool when

non-invasive presurgical evaluation has not led to a definitive decision for surgery. A multi-disciplinary team is needed to evaluate all the results of non-invasive tests. This can facilitate formulation of a hypothesis and determine a strategy for placement of intracranial electrodes. Intracranial electrodes are useful for mapping cortical functions extra-operatively. In our pilot study, we identified the epileptogenic zones in all patients in the absence of mortality or significant morbidity. Intracranial EEG is an underutilised modality locally, and might be potentially of benefit in patients with refractory epilepsy.

### Acknowledgements

We would like to acknowledge the contributions from the KS Lo Foundation towards the cost of treatment, which has made this pilot study a success. We also thank all the staff members of the electro-diagnostic unit at our hospital.

### References

1. Fong GC, Kwan P, Hui AC, Lui CH, Fong JK, Wong V. An epidemiological study of epilepsy in Hong Kong SAR, China. *Seizure* 2008;17:457-64.
2. Kwan P, Brodie MJ. Early identification of refractory epilepsy. *N Engl J Med* 2000;342:314-9.
3. Mohanraj R, Brodie MJ. Diagnosing refractory epilepsy: response to sequential treatment schedules. *Eur J Neurol* 2006;13:277-82.
4. Kwan P, Chan DT, Lui C, Chak WK. Epilepsy surgery program in Hong Kong. *Neurology Asia* 2007;12(Suppl 2):5-8.
5. Kahane P, Minotti L, Hoffmann D, Lachaux JP, Ryvlin P. Invasive EEG in the definition of the seizure onset zone: depth electrodes. In: Rosenow F, Lüders HO, editors. *Presurgical assessment of the epilepsies with clinical neurophysiology and functional imaging. Handbook of clinical neurophysiology*. Vol. 3. Amsterdam: Elsevier BV; 2004: 109-33.
6. Pondal-Sordo M, Diosy D, Téllez-Zenteno JF, Sahjapaul R, Wiebe S. Usefulness of intracranial EEG in the decision process for epilepsy surgery. *Epilepsy Res* 2007;74:176-82.
7. Tonini C, Beghi E, Berg AT, et al. Predictors of epilepsy surgery outcome: a meta-analysis. *Epilepsy Res* 2004;62:75-87.
8. Jennum P, Dhuna A, Davies K, Fiol M, Maxwell R. Outcome of resective surgery for intractable partial epilepsy guided by subdural electrode arrays. *Acta Neurol Scand* 1993;87:434-7.
9. Kim DW, Kim HK, Lee SK, Chu K, Chung CK. Extent of neocortical resection and surgical outcome of epilepsy: intracranial EEG analysis. *Epilepsia* 2010;51:1010-7.
10. Yun CH, Lee SK, Lee SY, Kim KK, Jeong SW, Chung CK. Prognostic factors in neocortical epilepsy: multivariate analysis. *Epilepsia* 2006;47:574-9.
11. Barba C, Barbati G, Minotti L, Hoffmann D, Kahane P. Ictal clinical and scalp-EEG findings differentiating temporal lobe epilepsies from temporal 'plus' epilepsies. *Brain* 2007;130:1957-67.