

## Case summary

A newborn infant was referred to the Department of Diagnostic Radiology, Princess Margaret Hospital, for further assessment for renal abnormalities detected by antenatal ultrasonography. Postnatal ultrasonography showed a cluster of non-communicating cysts of varying sizes in the left renal fossa (Fig 1). The largest cyst was peripherally located. No normal renal parenchyma was detected in the left renal fossa. Hydronephrosis was seen in the right kidney (Fig 2), but the right renal parenchyma otherwise appeared normal. No hydroureter was seen.

Right percutaneous nephrostomy was

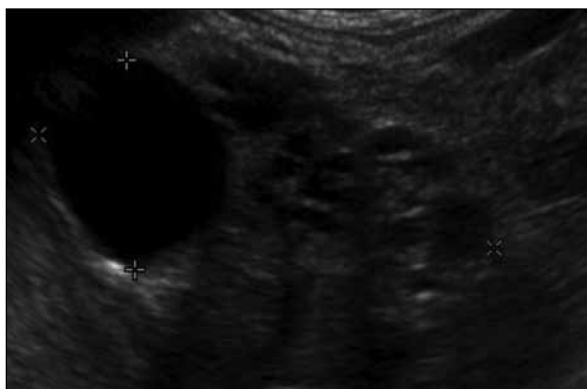

FIG 1. Ultrasonography of the left kidney showing multiple cysts of varying sizes replacing the left kidney, with no communication between the cysts. The largest cyst is peripherally located

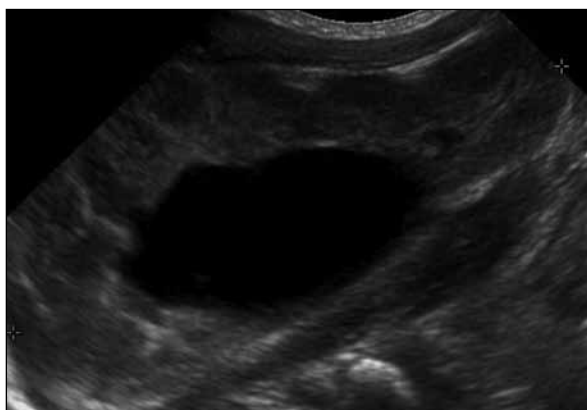


FIG 2. Ultrasonography of the right kidney showing a centrally located cystic structure, representing hydronephrosis with dilated renal pelvis. Renal parenchymal echogenicity and thickness are normal

performed. Subsequent antegrade pyelogram showed right hydronephrosis, and narrowing and irregularity at the pelviureteric junction (Fig 3). 99m-Technetium-mercaptoacetyltriglycine (MAG3) renography showed a non-functional left kidney with no tracer uptake (Fig 4). The right kidney was hydronephrotic with satisfactory perfusion and tracer extraction. The patient was referred to the Department of Urology. Pyeloplasty was planned for when the infant was aged 6 month.

## Discussion

This patient had right pelviureteric junction obstruction (PUJO) and left multicystic dysplastic kidney (MCDK).

Pelviureteric junction obstruction is the most common cause of fetal hydronephrosis. Fetal hydronephrosis is defined as renal pelvis dilation

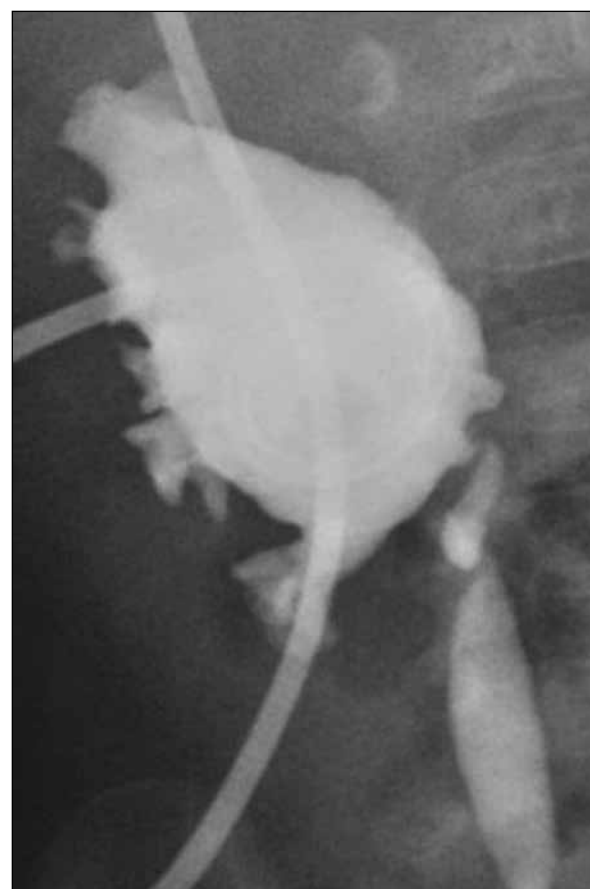

FIG 3. Antegrade pyelogram of the right kidney showing hydronephrosis with narrowing at pelviureteric junction

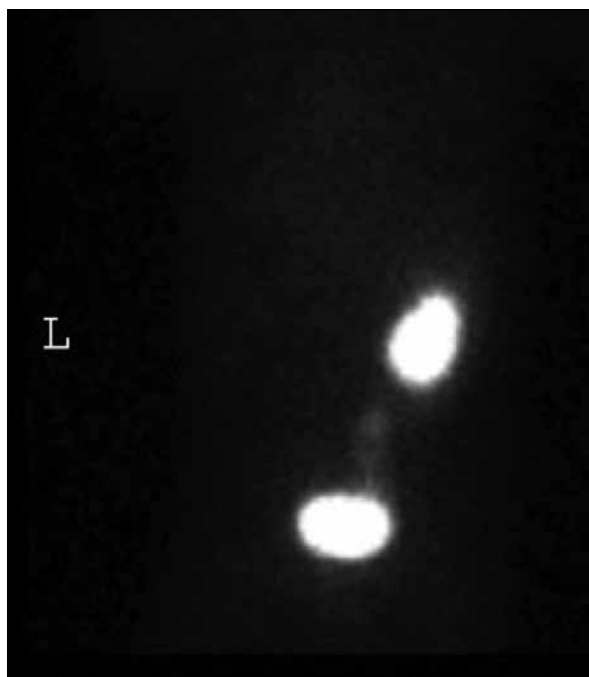


FIG 4. 99m-Techne-<sup>99m</sup>Tium-mercaptoacetyl-triglycine renography showing no activity in the left kidney, indicative of absence of functioning renal parenchyma. The right collecting system is dilated

with an anteroposterior diameter of more than 10 mm after 30 weeks of gestation.<sup>1</sup> Pelviureteric junction obstruction is unilateral in 70 to 90% of cases.<sup>2</sup> Around 27% of PUJO are associated with other anomalies such as vesicoureteral reflux, ureteral duplication, contralateral renal agenesis or contralateral multicystic dysplastic kidney,<sup>1</sup> as in this patient. The underlying aetiologies of congenital PUJO include replacement of PUJ muscle by collagen, dysmotility caused by abnormal muscle arrangement, and high ureteric insertion.<sup>1,2</sup> Pelviureteric junction obstruction is treated with pyeloplasty.

Multicystic dysplastic kidney is a form of cystic

renal dysplasia,<sup>3</sup> of which 80 to 90% of cases are unilateral.<sup>1</sup> Bilateral MCDK is fatal. The incidence of unilateral MCDK is estimated to be 1 in 4300 live births.<sup>1</sup> Associated anomalies of the contralateral kidney include vesicoureteral reflux, PUJO, and renal agenesis.<sup>1</sup> Most patients with MCDK undergo involution; Aslam et al<sup>4</sup> reported that 59% of patients with MCDK had complete involution at 10 years. Long-term complications such as hypertension and tumour formation are rare.<sup>3</sup> None of the patients in the report by Aslam et al<sup>4</sup> developed hypertension, significant proteinuria, or malignancy. Most cases can be managed conservatively with follow-up ultrasonography, and nephrectomy can be performed for complicated cases.<sup>1,3</sup>

Ultrasonography features can be used to differentiate PUJO from MCDK. Pelviureteric junction obstruction would show as dilation of the renal pelvis, which appears as a centrally located cystic structure that communicates with the renal calices. Multicystic dysplastic kidney would show as a cluster of non-communicating cysts that are of varying shapes and sizes, with the largest cysts tending to be peripherally located.<sup>1</sup> Normal renal parenchyma and central sinus complex would be absent in MCDK.<sup>1</sup> Renal scintigraphy would show lack of function, as demonstrated in this patient.

**Jessie TH Yeung**, MB, ChB, FRCR

Department of Diagnostic Radiology, Princess Margaret Hospital, Laichikok, Hong Kong

**Peter SM Yu**, MB, ChB

Email: [peteryu19@gmail.com](mailto:peteryu19@gmail.com)

Department of Diagnostic Radiology, United Christian Hospital, Kwun Tong, Hong Kong

**HY Lau**, MSc, RDMS

**CY Lui**, FRCR, FHKAM (Radiology)

Department of Diagnostic Radiology, Princess Margaret Hospital, Laichikok, Hong Kong

## References

1. Dahnert W, Radiology review manual. Philadelphia: Williams & Wilkins; 2007.
2. Ahuja AT. Diagnostic imaging: ultrasound. Canada: Amirsys; 2007.
3. Rottenberg GT, Gordon I, De Bruyn R. The natural history of the multicystic dysplastic kidney in children. *Br J Radiol* 1997;70:347-50.
4. Aslam M, Watson AR; Trent & Anglia MCDK Study Group. Unilateral multicystic dysplastic kidney: long term outcomes. *Arch Dis Child* 2006;91:820-3.