

KW Liu 廖建華
David LK Dai 戴樂群
K Wang 王琪
CY Cheung 張智欣

Dementia is a major worldwide public health concern in view of the global ageing phenomenon. Dementia usually occurs in old age. However, if the symptoms occur in young patients, the diagnosis can be challenging. Posterior cortical atrophy is a variant of the Alzheimer's disease, which is described as a presenile disease affecting relatively late-middle-aged patients. A combination of clinical, neuropsychological, and neuroimaging techniques may facilitate making a diagnosis of this particular patient group, as demonstrated in this report. Although there is no effective disease-modifying agent for treating these patients to date, there may be considerable pressure to arrive at a quick and accurate diagnosis from the perspective of employment and insurance.

Introduction

Dementia is an increasingly prevalent diagnosis in developed countries against a background of globally ageing phenomenon. The most frequent type of dementia is Alzheimer's disease (AD).¹ However, in last three decades there has been an accumulation of reports of neurodegenerative diseases with relatively isolated disturbance to visual processing that affects younger adults (age <65 years).²⁻⁴ Surprisingly, among the younger members of this patient group, amyloid plaque and neurofibrillary tangles are found, usually in association with the typical clinical syndrome affecting a single cognitive domain (not relating to the memory). In 1988, Benson et al³ introduced the term 'posterior cortical atrophy' (PCA) that is considered to be an atypical form of AD primarily affecting the occipito-parietal-temporal junction, based on five patients with progressive dementia initially presenting as apraxia, alexia, or visual agnosia. All five patients eventually developed components of Bálint's syndrome (sticky fixation, ocular dysmetria, and simultanagnosia) and Gerstmann's syndrome (right-left disorientation, finger agnosia, acalculia, and agraphia), though their language and affect were relatively normal. On the other hand, biomarkers (based on cerebrospinal fluid, neuroimaging, and blood tests) to identify this at-risk group of AD patients are being pursued. Neuroimaging is a relatively non-invasive means of contributing to the diagnosis of these patients. We report on a patient fulfilling the description of such a patient and his findings with respect to various types of imaging.

Case report

A 56-year-old right-handed tailor with good past health was referred by a general practitioner, on account of a 2-year history of cognitive impairment with atypical features of AD. The patient mainly complained of difficulties doing his usual job for about 1 year and misplacing personal objects, but in other respects there was a paucity of typical AD symptoms. He was a non-smoker and non-drinker, not in receipt of regular long-term medications, and had attended more than 9 years of formal education. Nor did he have any history of cognitive or psychiatric illness in his family, or severe head injury. He used to be good at calculations and enjoyed good manual dexterity, which was a requirement for preparing paper patterns that had served him well over the past 20 years of his work as a tailor. He himself and his boss both noted that compared with his previous abilities, he was having difficulties doing simple calculations and drawing simple paper patterns, resulting in erroneous calculations and wrong measurements. Moreover, his left/right orientation became impaired during both work and daily living, and went to the wrong location to see a close friend, whom he had been visiting him on a monthly basis. He was forced to quit his job due to recurring mistakes at work. He also got lost in a familiar Mass Transit Railway station. Nevertheless, he experienced no changes in personality, appetite, or sleeping pattern noted, nor was he observed to be a snorer or have spells of apnoea, and there was no history of auditory or visual hallucinations. He was aware of what was happening to him but felt helplessness. Functionally, he belonged to Functional Assessment Staging (FAST) of AD, stage 4 with decreasing ability to perform complex tasks such as arranging a meeting with his old friend, pay bills, and marketing.

Key words

Alzheimer disease; Atrophy;
Dementia; Electroencephalography;
Neuropsychological tests

Hong Kong Med J 2011;17:248-51

Prince of Wales Hospital, Shatin, Hong Kong
Department of Medicine and
Therapeutics

KW Liu, MRCP, FHKAM (Medicine)
DLK Dai, FRCP (Glasg), FHKAM (Medicine)
Department of Imaging and
Interventional Radiology
K Wang, FRCP, FHKAM (Radiology)
CY Cheung, FRCP, FHKAM (Radiology)

Correspondence to: Dr KW Liu
Email: kwliuhk@yahoo.com

一個年輕型腦退化症的病例

隨着全球人口老化的速度加快，腦退化症經已成為重要的公共健康問題。腦退化症的發病年齡一般較大，因此，年輕患者的病徵增加診斷難度。後腦皮質萎縮症是阿茲海默氏症的變種，被視為早老性的症狀，主要在中年過後發病。本文報告的病例結合臨床、神經心理和神經影像學技術，有助加快診斷。雖然現時未有治療方法讓患者完全康復，但從病人的就業及保險方面考慮，迅速和準確的診斷是非常重要的。

General neurological examination was normal. His speech remained fluent and there was no gaze palsy. His visual fields were unimpaired on confrontation. His Mini-Mental State Examination (MMSE) score was 17/30, which was low in the context of 9 years of formal education. Both writing and reading were mildly impaired as was his ability to perform calculations (reflected by a score of 1/5 in the MMSE). His Montreal Cognitive Assessment (MoCA) Hong Kong version score was 19/30, reflecting visual-spatial and constructional deficits, poor calculation, delayed recall and retrieval difficulty. He had impaired executive function, manifested as difficulties in loop drawing and retrieval in the MoCA. Yet his Geriatric Depression Scale score (3/15) was within the normal range. He also had mild difficulties in clock reading and clock drawing, which is an easy test for screening dementia (especially its executive component; Fig 1a and cube drawing). These are typically poor in patients with dementia as they can focus their attention on only one feature of a drawing at a time, and cannot adequately integrate separate features into a coherent whole (Fig 1b, c). He showed impaired copying of the Rey-Osterrieth Complex Figure (reflecting defective constructional, perceptual and organisational ability; and visual perceptual memory; Fig 1d, e); MMSE and MoCA may be too insensitive to pick up early visual-spatial dysfunction. His result was less than 1 percentile, when age-adjusted.

Biochemical investigations for disorders involving thyroid function, vitamin B12, and folate were unremarkable, as were the Venereal Disease Research Laboratories, ceruloplasmin level and human immunodeficiency virus serology test results.

Computed tomography (CT) of his brain showed the right posterior parietal lobe to be slightly more atrophic than that on the contralateral side (Fig 1f). T2-weighted magnetic resonance imaging (MRI) of the brain showed right posterior parietal sulci to be more dilated than that on the contralateral side (Fig 1g). In this patient, there was no significant small or large vessel disease on fast fluid-attenuated inversion-recovery MRI and the magnetic resonance angiogram. Thus, there was no evidence of a vascular insult to explain the patient's features. Single-photon emission computed tomography

(SPECT) shown in Figures 1h and 2 exhibited severe right posterior parietal hypoperfusion. Magnetic resonance spectroscopy (MRS) targets the single voxel at the right and the left posterior cingulate gyri to registered ratios of N-acetylaspartate/creatinine (NAA/Cr) and myo-inositol/creatinine (MI/Cr) ratio. 18F-fluorodeoxyglucose positron emission tomography (FDG-PET) of the brain showed mild diffusely decreased cerebral glucose metabolism over the posterior cingulate gyrus, precuneus and both temporal lobes (though worse on the right). Moderately decreased metabolism was noted in both parietal lobes, though worse on the right (Fig 1i, j). After 11C Pittsburgh compound B position emission tomography (11C PIB PET), there was abnormal retention over the posterior cingulate gyrus, precuneus, as well as both frontal, parietal, occipital, and temporal lobes (Fig 1k, l).

This young patient had an unusual cognitive complaint. The clinical features, structural and functional imaging were compatible with the diagnosis of PCA (as reflected by acalculia, agraphia, visual agnosia, left right disorientation, and visual-spatial impairment). Imaging findings together with FAST staging (stage 4 result) were also consistent. After a trial of cholinesterase-inhibitor therapy, his MMSE improved to 22/30 on his second follow-up visit and further follow-up will continue.

Discussion

Dementia usually occurs in old age. In people aged 70 years or above, its prevalence in Hong Kong is reported to be 6.1% or above, which is similar to that in the West.⁴ Alzheimer's disease is the most frequent cause of dementia. If the symptoms occur in young patients, the diagnosis can present a substantial challenge. Posterior cortical atrophy is a variant of the AD, described as a presenile affliction of relatively late-middle age. Unlike AD or frontotemporal dementia, the clinical presentation of PCA is different. The prevalence of PCA is unclear. Age of onset is usually lower than that in the typical AD patient in whom the onset increases sharply with age; the mean being in the seventh decade. The main feature of PCA is visual-spatial impairment, while memory and language are less affected. Their posterior cingulate cortex shows a high density of amyloid plaques and neurofibrillary tangles. The posterior cingulate is important in long-term memory and self-representation and has a complex topographically organised structure.

In our patient, CT and MRI of the brain showed parietal-occipital lobe atrophy. We also proceeded to undertake single-voxel proton MRS (1H MRS) to examine the anatomic distribution of metabolite signals. The latter includes those of compounds containing NAA, Cr and phosphocreatine, and MI. Magnetic resonance spectroscopy has proven to be a promising tool for predicting conversion to

dementia, when used to examine the posterior cingulate gyrus.⁵ The metabolite NAA is consistently found in lower concentrations, and the metabolite MI is higher in the 1H MRS spectra of patients with AD.⁶ Reduction of NAA level may indicate neuronal loss or damage, mitochondrial dysfunction, or decreased hydration, while elevated MI levels have been linked to gliosis, membrane dysfunction, or cytoskeletal abnormalities. On the other hand, there is a positive correlation between the magnitude of NAA reduction and the severity of neuropathological findings (ie increased count of amyloid plaques and neurofibrillary tangles).⁷ Myo-inositol may be a marker of glial cell activity in neurodegenerative disease. Regional elevations of MI/Cr levels in prodromal AD suggests that the 1H MRS may be a sensitive biochemical change heralding the pathologic progression of AD before significant loss of neuronal integrity in that region.⁶ In our patient, the MRS results also showed increase in MI level and decreased NAA levels in posterior cingulate gyrus and is compatible with AD.

¹⁸F-fluorodeoxyglucose positron emission tomography makes use of glucose metabolism for imaging cerebral metabolism. In a community-based series of patients with early-onset dementia, AD was detected by FDG-PET with 78% sensitivity and 81% specificity.⁸ The high specificity of FDG-PET implies that a negative or normal scan in the presence of a suspicion of dementia makes diagnosis unlikely. In our patient, the FDG-PET brain result was compatible with typical PCA, whereas the FDG-PET usually shows hypometabolism of the occipito-parieto-temporal cortex that is usually more severe on the right side.

Molecular imaging techniques have been widely used to study disease pathology and drug actions both in clinical and preclinical stages. Among these imaging, PET and SPECT play a unique and important role. Single-photon emission computed tomography entails use of ^{99m}Tc-HMPAO (technetium-99m hexamethylpropylene amine oxime) or ^{99m}Tc-ECD (technetium-99m-ethyl cysteinate dimer) as a substrate and assesses regional blood flow in the brain. In terms of diagnostic accuracy, a systematic review of SPECT studies reported 74% sensitivity and 70% specificity for AD versus control subjects, and 76% specificity for other forms of dementia.⁹ In contrast to the typical features of AD in terms of hypoperfusion of the temporo-parietal area, PCA patients have occipito-parietal hypoperfusion and hypometabolism. On the other hand, the availability of in-vivo PET ligands for amyloid such as ¹¹C-PIB, ie 2-[4'-(methylamino) phenyl]-6-hydroxybenzothiazole, has opened up the possibility of studying the relationship between brain atrophy and amyloid deposition directly and in vivo. Amyloid plaque is one of the pathological hallmarks of AD. Other associated pathological changes include: neurofibrillary tangles, loss of neurons, loss

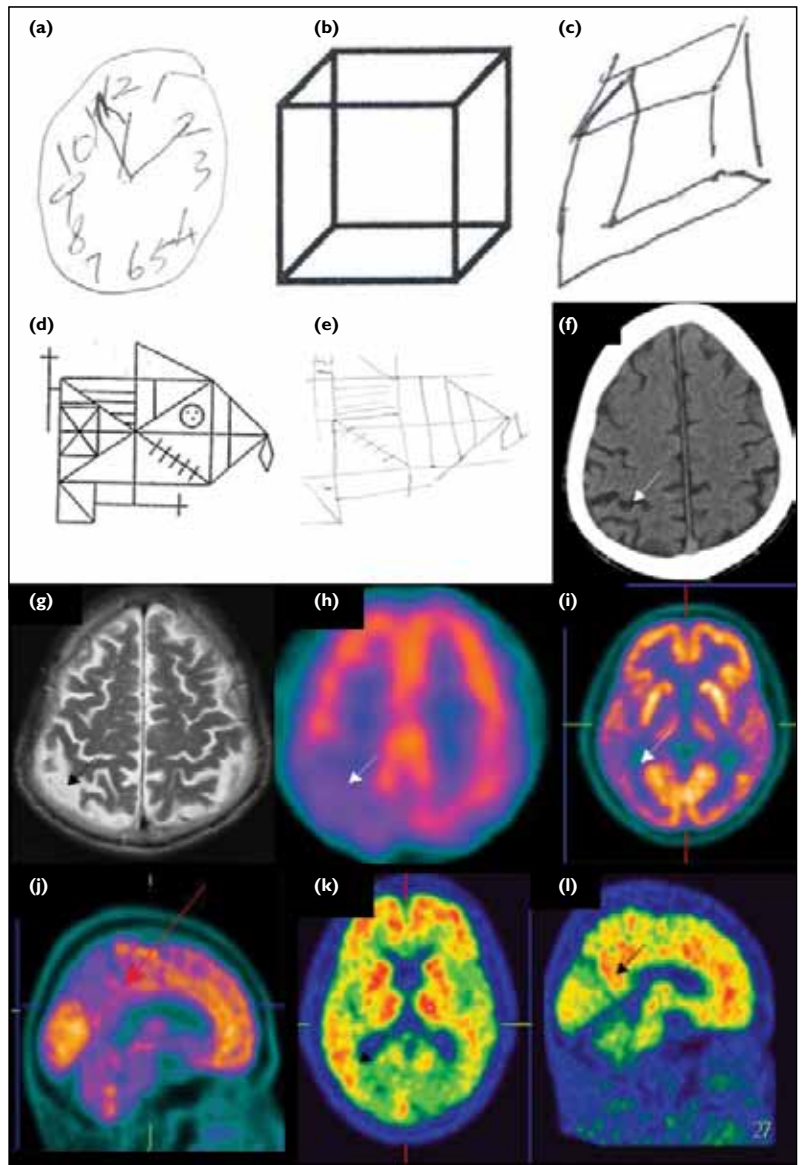


FIG 1. (a) Impairment of clock-face drawing of ten past ten by the patient. (b, c) A cube and the patient's copy of the cube. The latter shows that his copying was impaired. (d) The Rey-Osterrieth Complex Figure as a widely used neuropsychological tool for assessing visuospatial processing, memory and executive function in clinical populations. (e) The patient's copy of the Rey-Osterrieth Complex Figure displays visuospatial processing impairment. (f) Axial computed tomogram (CT) of the patient showing that the right posterior parietal lobe is slightly more atrophic than that on the contralateral side. (g) Axial T2-weighted magnetic resonance image (MRI) of the patient showing that the right posterior parietal sulci are more dilated than that on the contralateral side; right posterior cortical atrophy is more obvious on MRI than CT. (h) Axial technetium-99m-ethylcysteinate dimer single-photon emission computed tomography of the patient showing markedly decreased perfusion in the right posterior parietal lobe. (i, j) Decreased ¹⁸F-fluorodeoxyglucose activity over the posterior cingulate gyrus of the right parietal lobe indicates hypometabolism in the right parietal lobe. (k, l) The 35-minute delayed images showing abnormal Pittsburgh compound B retention over the posterior cingulate gyrus, which indicate increased amyloid deposit over the right posterior parietal lobe

of synapses, and dendritic dearborisation. Numerous ¹¹C PIB PET studies of amnesic AD have been conducted.¹⁰ The availability of ligands that may be specific for amyloid has increased its application to the early diagnosis of AD.¹¹ From the pathological point of view, the most prevalent associated

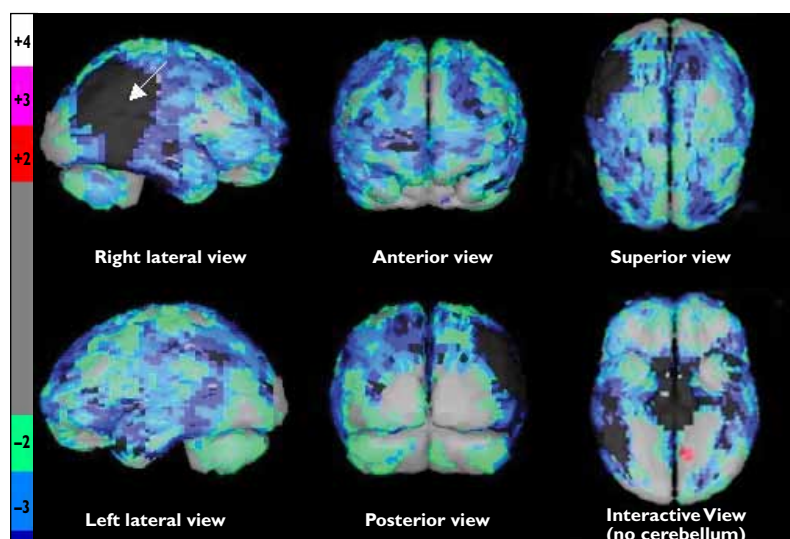


FIG 2. Talairach analysis of cerebral ethyl cysteinate dimer single-photon emission computed tomography (compared with computer-generated normal elderly database). The right posterior parietal lobe shows severe hypoperfusion (black-coloured area pointed out by white arrow) than for normal elderly, in addition to generalised mild-to-moderate cerebral hypoperfusion. The colour bar on the left is a scale representing the patient's cerebral perfusion with reference to the normal elderly database: grey colour denotes similar perfusion as the database; red, violet and white colours progressive hyperperfusion; green, blue, purple and black colours (not shown) progressive hypometabolism compared with the database

pathological findings of PCA are amyloid plaques and neurofibrillary tangles predominantly affecting the visual association areas.¹² Numerous ¹¹C PIB studies of amnesic AD patients have been conducted to study the association. However, the link between amyloid beta and regional brain dysfunction remains controversial.¹³ In our patient, PCA was demonstrated in the right posterior parietal lobes, there being

severe hypoperfusion in SPECT and abnormal PIB retention over posterior cingulate gyrus, precuneus, as well as over both frontal, parietal, occipital and temporal lobes.

Conclusion

Diagnosis is sometimes difficult in a patient presenting with atypical symptoms of cognitive impairment or dementia, especially for a young patient. It is of particular importance in a younger patient, because an accurate diagnosis is vital in relation to employment and insurance. Other aspect includes driving. Continuing to drive is not recommended as there is significant impairment of memory related to visuospatial skills, insight and judgement, and they may have problematic hallucinations or delusions. Baseline and periodic reviews are required as most forms of cognitive impairment and dementia are progressive. Moreover, drivers with a diagnosis of dementia generally do not meet required commercial standards. On the other hand, treatment of these patients remains a dilemma. Cholinesterase inhibitors might be expected to help AD patients, and therefore commenced for our patient. Finally, both structural and functional imaging techniques are valued components, which can assist in the diagnosis and management of dementia with atypical symptoms.

Acknowledgement

The work described in this paper was partially supported by a grant from the Research Grants Council of the Hong Kong Special Administrative Region, China (Project No. SEG_CUHK02).

References

1. Beard CM, Kokmen E, O'Brien PC, Kurland LT. The prevalence of dementia is changing over time in Rochester, Minnesota. *Neurology* 1995;45:75-9.
2. Cogan DG. Visual disturbances with focal progressive dementing disease. *Am J Ophthalmol* 1985;100:68-72.
3. Benson DF, Davis RJ, Snyder BD. Posterior cortical atrophy. *Arch Neurol* 1988;45:789-93.
4. Chiu HF, Lam LC, Chi I, et al. Prevalence of dementia in Chinese elderly in Hong Kong. *Neurology* 1998;50:1002-9.
5. Modrego PJ. Predictors of conversion to dementia of probable Alzheimer type in patients with mild cognitive impairment. *Curr Alzheimer Res* 2006;3:161-70.
6. Kantarci K, Petersen RC, Boeve BF, et al. 1H MR spectroscopy in common dementias. *Neurology* 2004;63:1393-8.
7. Klunk WE, Panchalingam K, Moosy J, McClure RJ, Pettegrew JW. N-acetyl-L-aspartate and other amino acid metabolites in Alzheimer's disease brain: a preliminary proton nuclear magnetic resonance study. *Neurology* 1992;42:1578-85.
8. Hoffman JM, Welsh-Bohmer KA, Hanson M, et al. FDG PET imaging in patients with pathologically verified dementia. *J Nucl Med* 2000;41:1920-8.
9. Dougall NJ, Bruggink S, Ebmeier KP. Systematic review of the diagnostic accuracy of 99mTc-HMPAO-SPECT in dementia. *Am J Geriatr Psychiatry* 2004;12:554-70.
10. Edison P, Archer HA, Hinz R, et al. Amyloid, hypometabolism, and cognition in Alzheimer disease: an [¹¹C]PIB and [¹⁸F] FDG PET study. *Neurology* 2007;68:501-8.
11. Frisoni GB, Lorenzi M, Caroli A, Kemppainen N, Någren K, Rinne JO. In vivo mapping of amyloid toxicity in Alzheimer disease. *Neurology* 2009;72:1504-11.
12. Renner JA, Burns JM, Hou CE, McKeel DW Jr, Storandt M, Morris JC. Progressive posterior cortical dysfunction: a clinicopathologic series. *Neurology* 2004;63:1175-80.
13. Li Y, Rinne JO, Mosconi L, et al. Regional analysis of FDG and PIB-PET images in normal aging, mild cognitive impairment, and Alzheimer's disease. *Eur J Nucl Med Mol Imaging* 2008;35:2169-81.