

Lilian PY Lee 李寶儀
WK Chiu 趙華強
HB Chan 陳衍標
Kelvin KW Liu 廖鑑榮

A minimally invasive technique of chest drain insertion using the Mini Step bladeless trocar is described. Thirty-one chest drain insertions were performed with this technique between January 2007 and December 2009. It is a safe, efficient, fast, and easily acquired means of chest drain insertion in children, which has a high success rate and minimal morbidity. Overwhelmingly positive responses were obtained from doctors of all levels who used this technique, which is highly recommended for chest drain insertion in conscious children.

Introduction

Chest drain insertion is a common procedure for the treatment of various clinical conditions, including pneumothorax, haemopneumothorax, malignant and parapneumonic pleural effusion, empyema and postoperative drainage following cardiothoracic surgery.¹ Because of its clinical utility in a wide variety of conditions, chest drain insertion is considered to be a mandatory procedure that clinicians in many disciplines should be able to perform. Blunt dissection and insertion of chest drain without trocar has been a well-accepted technique.^{2,3} This potentially life-saving procedure, however, may lead to significant morbidity. Etoch et al⁴ found an "improper placement" of chest drains in 5% of patients and an undrained pneumothorax or effusion in an additional 5%. In one series, up to 30% of patients had complications after chest drain insertion,⁵ including pain, vascular injury, improper positioning of chest drain, as well as empyema and pneumonia. In January 2007, we introduced a minimally invasive technique for chest drain insertion in children.

Methods



A video of minimally invasive chest drain insertion is available at <www.hkmj.org>

The technique involves tube thoracostomy using the Mini Step bladeless trocar (United States Surgical, Tyco Healthcare Group LP). The necessary equipment is shown in Figure 1. It includes: (1) a 14-gauge insufflation and access needle (S110000 Step Short Insufflation/Access Needle, 14 Gauge, Covidien Autosuture), (2) a radially expandable plastic sleeve, and (3) a 5-mm cannula and dilator assembly of 90-mm workable length (MS100705 Mini Step Short 5-mm, Cannula and Dilator with Radially Expandable Sleeve, Covidien Autosuture).

The system utilises the radially expandable sleeve that fits snugly over the short insufflation and access needle (Fig 2a). After the sleeve-needle assembly has been advanced through the thoracic wall into the thoracic cavity (Fig 2b), the needle is removed, allowing dilatation of the expandable sleeve with insertion of the cannula and dilator assembly (Fig 2c). The dilator is then dislodged from the system (Fig 2d), leaving the cannula in-situ. A 16-Fr chest drain is inserted through the cannula into the thoracic cavity (Fig 2e). The tip of the chest drain should be aimed towards the lung apex for pneumothorax, and to the lung base for draining fluid. When the chest drain has been advanced to a desired length, the open end of the chest drain is connected to an underwater seal. The cannula and the expandable sleeve together are then gently pulled out of the thoracic cavity and left overlying the chest drain (Fig 2f). The chest drain is then secured to the skin by sutures.

A larger-bore cannula and dilator assembly of 10-mm internal diameter and 90-mm length is adopted for insertion of a larger-bore chest drain of 28 Fr, for use in patients with haemopneumothorax, pleural effusion, and empyema.

Records of consecutive patients aged less than 18 years having chest drain insertion using the Mini Step bladeless trocar between January 2007 and December 2009 were retrieved from the Clinical Management System. Data regarding age, gender, body weight, diagnosis, indications of chest drain insertion, amount of sedation administered, position of the chest drain tip, effectiveness of chest tube drainage, and complications were collected.

Tube thoracostomy was performed by the attending paediatrician. Patient positioning

Key words
Chest tubes; Child; Drainage;
Pneumothorax; Surgical instruments

Hong Kong Med J 2011;17:137-40

United Christian Hospital, Kwun Tong,
Hong Kong:
Department of Paediatrics and
Adolescent Medicine
LPY Lee, FHKCPaed, FHKAM (Paediatrics)
WK Chiu, FHKCPaed, FHKAM (Paediatrics)
HB Chan, FHKAM (Paediatrics), FRCPCH
Division of Paediatric Surgery,
Department of Surgery
KKW Liu, FHKAM (Surgery), FRCS

Correspondence to: Dr LPY Lee
Email: leeypl@ha.org.hk

於兒童身上微創放置胸腔引流管

本文描述有關使用Mini Step無刀片穿刺套管進行微創放置胸腔引流管的手術。我們在2007年1月至2009年12月期間共進行了31宗放置胸腔引流管的手術，發現此技術為兒童放置胸腔引流管提供了安全、有效、快捷及容易的方法，而且成功率高、罹病率低。曾使用此技術的各層面的醫生都一致給予高度的評價，並極力推薦在意識清醒的兒童身上使用這技術。

and site of chest drain insertion remained the same as for the traditional method, that is, at the safety triangle.¹ The procedure was performed using aseptic technique; sedation and local anaesthetic were used before insertion.

A questionnaire on the difficulties encountered during chest drain insertion before and after the introduction of Mini Step bladeless trocar was sent to the attending paediatricians of our department. The aspects surveyed included: (1) amount of




FIG 1. Equipments constituting the Mini Step bladeless trocar

sedation and analgesia employed, (2) ease of creation of muscle tunnel, (3) positioning of chest drain, (4) average time required for chest drain insertion, and (5) the preference of methods for chest drain insertion.

Results

Thirty-one episodes of chest drain insertion on 26 paediatric patients using the Mini Step bladeless trocar were identified. Patient ages ranged between 3 and 17 (mean, 13) years. About 4 times as many males as females had such chest drains inserted (21:5), and their body weights ranged between 13 and 60 kg. Indications for chest drain insertion included: primary spontaneous pneumothorax (n=18, 58%), tension pneumothorax (n=3, 10%), haemopneumothorax (n=5, 16%), and pleural effusion (n=5, 16%).

The position of the tip of the chest drain was classified as appropriate if chest radiograph demonstrated that the chest drain was in the thoracic cavity pointing upwards towards the lung apex for pneumothorax and basally for pleural effusion. In our series, all the 31 chest drains (100%) inserted by the Mini Step bladeless trocar were inserted within the thoracic cavity. Thirty (97%) episodes were deemed successful drainage of air or fluid. The remaining episode was an undrained pneumothorax. The chest drain was placed in the thoracic cavity but was kinked and required resiting for lung expansion. There was no other morbidity.

The questionnaires were completed by 13 out of 28 doctors in our department to whom they were sent; their medical experience ranged from 1 to 23 years. The participants included eight paediatric specialists and five paediatric trainees. All doctors responding to the questionnaire found the Mini Step bladeless trocar technique easier for creating the muscle tunnel. Most (77%) stated using smaller

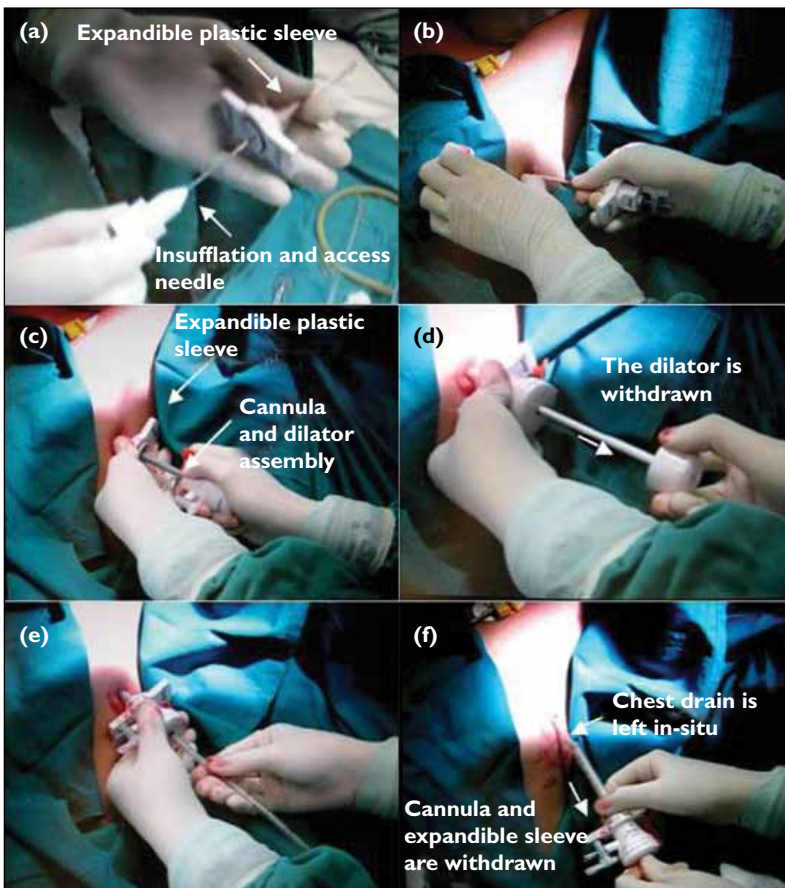


FIG 2. (a) The expandible plastic sleeve was fitting over the insufflation and access needle. (b) The sleeve-needle assembly was punctured into the thoracic cavity. The needle was then removed. (c) The cannula and dilator assembly was advanced through the expandible sleeve. (d) The dilator was withdrawn from the assembly. (e) A 16-Fr chest drain was inserted through the cannula. (f) The cannula and the expandible sleeve were removed out of the thoracic cavity and they were left overlying the chest drain, leaving the chest drain in-situ

TABLE. Difference in time required between paediatric specialists and trainees for chest drain insertion using the Mini Step bladeless trocars*

	≤10 mins	>10 mins	Total
No. of paediatric specialists	5 (63%)	3 (37%)	8
No. of paediatric trainees	3 (60%)	2 (40%)	5

* P=0.928

dosages of sedation and analgesia for the procedure. The doctors were unanimous in stating that the procedure time for using this technique was shorter. The mean procedure times for blunt dissection and Mini Step bladeless trocar insertion were 25 and 10 minutes, respectively. There was no significant difference in the time required by paediatric specialists and trainees using this technique (Table).

Discussion

It is not uncommon to see reports of chest drain insertion causing morbidity including injuries to the stomach⁶ and pulmonary artery,⁷ perforation of the lung,⁸ diaphragm and intra-abdominal organs.⁹ The Mini Step bladeless trocar minimises this risk as the sleeve-needle assembly consists of an external puncture sharp edge enclosing a slightly longer blind-ended springeable tip in the centre. During the advancement of the sleeve-needle assembly through the chest wall, the central tip recedes upon physical resistance offered by the skin, intercostal muscle, and pleura. Once the sleeve-needle assembly enters the thoracic cavity, the central tip springs out to its original position upon loss of resistance. This design helps prevent puncture damage to the lung parenchyma and other internal organs. The sleeve-needle assembly efficiently creates a 'tunnel' through the chest wall that enables safe introduction of the chest tube.

Pain is an important concern in children undergoing invasive procedures. Placement of a chest drain even in a sedated child can be a very traumatic experience for both the clinician and patient. Chest drain insertion has even been reported to be a bedside procedure causing unacceptable pain levels.¹⁰ Chest tube insertion using the Mini Step bladeless trocar is minimally invasive, since it involves a smaller wound, less trauma to the intercostal muscles, and less blood loss compared to the traditional methods entailing blunt dissection. A small superficial incision of the skin and subcutaneous tissue of about 5 mm is required to accommodate the cannula and dilator

assembly. The cannula and dilator assembly allows the passage of 16-Fr chest tube. A chest tube of this size is contemporarily advocated by the latest British Thoracic Society guideline for management of primary spontaneous pneumothorax.¹ The smaller wound inflicts less pain and hence the need for smaller amounts of analgesia. It may also reduce the subsequent risk of wound bleeding and infection.

A limitation of this retrospective study was the lack of any objective comparison of the amounts of sedation and analgesia used in patients undergoing traditional blunt dissection and those managed with the bladeless trocar. The amount and types of sedation prescribed varied according to the doctor's preference and thus it was difficult to compare.

Efficient and quick insertion of the chest tube is another benefit of employing the Mini Step bladeless trocar, irrespective of the size of chest drain. This is especially important during emergency situations like tension pneumothorax and massive haemothorax, in which prompt and accurate positioning of chest tube is life-saving. The proper positioning of the chest drain also minimises the risk of complications. From our experience with the Mini Step bladeless trocar since January 2007, the mean duration of the procedure ranged from 10 to 15 minutes. The efficiency of this technique was shown to be reproducible, even in the hands of paediatric trainees. In our series, only one of the chest drains inserted by the Mini Step bladeless trocar was non-functional due to kinking. Our positional complication rate was 3.2% (1 out of 31), compared to the 4 to 5% reported by conventional insertion methods.^{4,11} All the participating doctors responding to our questionnaire preferred the Mini Step bladeless trocar as a means of chest drain insertion.

Components of the Mini Step bladeless trocar are single-use devices. It costs HK\$840 for the three-component set. The relatively high cost of the Mini Step bladeless trocar is worthwhile, in view of its safety, user-friendliness, and lower risk of complications.

Conclusion

The Mini Step bladeless trocar facilitates safe, minimally invasive, fast, and efficient chest drain insertion with minimal morbidity. It can be readily used by doctors with all grades of clinical experience. It is an important innovation in chest drain insertion at bedside in emergency conditions, and is a method of choice for use in all children requiring tube thoracostomy.

References

1. Henry M, Arnold T, Harvey J; Pleural Diseases Group, Standards of Care Committee, British Thoracic Society. BTS guidelines for the management of spontaneous pneumothorax. *Thorax* 2003;58 Suppl 2:ii39-52.
2. Mehrabani D, Kopelman AE. Chest tube insertion: a simplified technique. *Pediatrics* 1989;83:784-5.
3. Hyde J, Sykes T, Graham T. Reducing morbidity from chest drains. *BMJ* 1997;314:914-5.
4. Etoch SW, Bar-Natan MF, Miller FB, Richardson JD. Tube thoracostomy. Factors related to complications. *Arch Surg* 1995;130:521-6.
5. Ball CG, Lord J, Laupland KB, et al. Chest tube complications: how well are we training our residents? *Can J Surg* 2007;50:450-8.
6. İçöz G, Kara E, Ilkgül O, Yetgin S, Tunçyürek P, Korkut MA. Perforation of the stomach due to chest tube complication in a patient with iatrogenic diaphragmatic rupture. *Acta Chir Belg* 2003;103:423-4.
7. Takanami I. Pulmonary artery perforation by a tube thoracostomy. *Interact Cardiovasc Thorac Surg* 2005;4:473-4.
8. Fraser RS. Lung perforation complicating tube thoracostomy: pathologic description of three cases. *Hum Pathol* 1988;19:518-23.
9. Zieren J, Enzweiler C, Müller JM. Tube thoracostomy complicates unrecognized diaphragmatic rupture. *Thorac Cardiovasc Surg* 1999;47:199-202.
10. Luketich JD, Kiss M, Hershey J, et al. Chest tube insertion: a prospective evaluation of pain management. *Clin J Pain* 1998;14:152-4.
11. Bailey RC. Complications of tube thoracostomy in trauma. *J Accid Emerg Med* 2000;17:111-4.