

# A rare combination of recurrent pneumonia, diarrhoea, and visual loss in a patient after thymectomy: Good syndrome

Jasperine KY Ho 何家儀  
Maureen ML Wong 黃慕蓮  
Thomas KF Tai 戴嘉發  
Doris MW Tse 謝文華

This report describes a 68-year-old Chinese man who was diagnosed with Good syndrome 6 years after initial presentation when he underwent thymectomy. He presented with recurrent pneumonia, diarrhoea, weight loss, and visual symptoms. Extensive examination for anaemia and neutropenia was done, yet no conclusive diagnosis could be derived. During his last admission for pneumonia, his history of AB thymoma suggested the possibility of Good syndrome. Immunological testing revealed low T cells, absent B cells, and low immunoglobulin M and immunoglobulin G levels. Moreover, he had histologically identified cytomegalovirus pneumonia, cytomegalovirus colitis, and fundoscopic features of cytomegalovirus retinitis. He was treated with a 2-week course of intravenous ganciclovir, lifelong oral valganciclovir, and monthly immunoglobulin infusion. It took 6 years for the diagnosis to be established, therefore, early attention and vigorous search for such potentially treatable conditions in post-thymectomy patients presenting with recurrent infections is recommended.

## Case report

A 68-year-old Chinese man, who was an ex-smoker and a non-drinker first presented to the Department of Medicine, Caritas Medical Centre, Hong Kong, in 2003 with a persistent cough. Computed tomography (CT) of the thorax identified a 10 x 10 cm thymoma. He underwent thymectomy and the pathological staging was type AB minimally invasive thymoma (World Health Organization classification<sup>1</sup>).

Between July 2003 and September 2009, he underwent multiple hospital admissions for fever, chronic cough, chronic diarrhoea, weight loss, and visual disturbance. In July 2003, he was admitted for fever and cough. His peripheral neutrophil count was  $0.5 \times 10^9/L$  (reference range,  $1.8-7.8 \times 10^9/L$ ). Chest radiograph showed right hilar opacity and right lower lobe haziness. Sputum culture was negative. He responded to a 1-week course of Tazocin (4.5 g intravenously every 8 hours; Wyeth, Carolina, US). Computed tomography of the thorax showed a contracted right lower lung with coarse interstitial thickening, traction bronchiectasis, and fibrotic changes.

In January 2007, the patient was admitted to the Department of Ophthalmology with sudden deterioration in visual acuity in his left eye. The diagnosis was left amaurosis fugax and he was treated with aspirin. In July 2007, he was admitted with right lower lobe pneumonia. The sputum culture yielded *Streptococcus pneumoniae* and *Haemophilus influenzae*. The symptoms resolved after a week of treatment with Augmentin (1.2 g intravenously every 8 hours; Beecham Pharmaceuticals, UK).

In April 2008, he was admitted with watery diarrhoea, chronic cough, and weight loss of 9 kg in the previous 4 months. His haemoglobin level was 90 g/L (reference range, 140-175 g/L) and his neutrophil count was  $0.5 \times 10^9/L$ . Chest radiograph showed right lower zone pneumonia. Sputum culture identified *H influenzae*. Computed tomography of the thorax showed a tree-in-bud appearance in both lungs, mainly involving the lower lobes. Three sputum specimens for tuberculosis and stool cultures for bacteria were negative. Thyroid function was normal. Gastroenteroscopy showed no gross lesions. Colonic biopsy found non-specific proctitis. Small bowel follow-through identified no abnormality. His condition improved after a course of Augmentin (1.2 g intravenously every 8 hours, Reyoung Pharmaceuticals Co Ltd, Shandong, PRC).

In March 2009, the patient presented with fever, chronic cough, reduced appetite, and watery diarrhoea for 3 months. His peripheral neutrophil count was  $0.6 \times 10^9/L$ . His haemoglobin level dropped from 120 to 90 g/L in 8 months. His serum iron was 1.5  $\mu\text{mol/L}$  (reference range, 10.7-26.9  $\mu\text{mol/L}$ ) and total iron binding capacity was 22.8  $\mu\text{mol/L}$  (44.8-71.6  $\mu\text{mol/L}$ ), while his serum vitamin B12 and folate levels were normal. Carcinoembryonic antigen, alpha-fetoprotein, and prostate specific antigen were unremarkable. Bone marrow

### Key words

Agammaglobulinemia; Cytomegalovirus retinitis; Immunoglobulins, intravenous; Thymoma; Thymus neoplasms

Hong Kong Med J 2010;16:493-6

Department of Medicine, Caritas Medical Centre, Shamshuipo, Kowloon, Hong Kong  
JKY Ho, MRCP (UK)

MML Wong, FHKAM (Medicine), FRCP (Edin)  
TKF Tai, FCOphth HK, FHKAM (Ophthalmology)  
DMW Tse, FHKAM (Medicine), FRCP (Lond, Edin)

Correspondence to: Dr JKY Ho  
Email: hoky2@ha.org.hk

## 古德綜合徵：胸腺切除後出現罕有的復發性肺炎、腹瀉及視力喪失

一名68歲華籍男性出現復發性肺炎、腹瀉、體重下降及視力喪失，被確診古德綜合徵（Good syndrome）。病人6年前曾接受胸腺切除。入院時經仔細檢查，確定病人並無貧血及中性白細胞減少症。最後病人因肺炎入院才發現AB型胸腺瘤的病史顯示他患有古德綜合徵。免疫學檢查顯示病人的T細胞水平偏低，缺乏B細胞，以及免疫球蛋白M及G水平偏低。病人亦有巨細胞病毒肺炎、巨細胞病毒結腸炎和巨細胞病毒性視網膜炎的眼底症狀。病人接受靜脈注射更昔洛韋（ganciclovir）兩星期的療程，長期口服巽更昔洛韋（valganciclovir），及每日進行靜脈注射免疫球蛋白治療。接受胸腺切除後的病人如果出現復發性感染，應盡早留意及積極找出病因以治癒這病。

examination was performed because of bicytopenia. The results showed marrow hypocellularity, normal granulopoiesis by trephine biopsy, and no evidence of malignancy. Human immunodeficiency virus (HIV) serology was negative. Repeated stool cultures and *Clostridium difficile* toxin were negative. The neutropenic fever responded to Tazocin (4.5 g every 8 hours; Wyeth).

In August 2009, he was admitted with persistent symptoms. His peripheral neutrophil count was  $1.0 \times 10^9/L$ . Chest radiograph showed right lower lobe bronchiectatic changes. Sputum culture identified *Pseudomonas aeruginosa*. Stool culture for *C. difficile* toxin was negative. He was discharged after a course of piperacillin (4 g intravenously every 6 hours; Piperacillin North China Pharmaceuticals Co Ltd, Shandong, PRC) and oral Ciproxin (400 mg orally twice a day; AP Pharma Ltd, Hong Kong).

In view of the repeated right lower lobe pneumonia, he was admitted for bronchoscopy in September 2009, which showed mildly swollen left lower lobe orifices. Subsequently, a random right lower lobe biopsy was positive for cytomegalovirus (CMV)–staining nuclear and cytoplasmic inclusions. He also complained of acute visual deterioration in his right eye for 5 days before admission. The visual acuity in his right was 6/60, and an ophthalmologist's initial diagnosis was right branch retinal artery occlusion. The patient was then examined for suspected adult-onset immunodeficiency. Repeat HIV serology was negative, and peripheral blood CMV pp65 was undetectable. The lymphocyte subset profile showed low T cells, low CD4+ to CD8+ ratio, absent B cells, and low immunoglobulin (Ig) M and IgG levels (Table). With his background of AB thymoma, a diagnosis of Good syndrome with CMV

TABLE. The patient's lymphocyte subset profile by flow cytometry and immunoglobulin levels

Lymphocyte subset profile	Dual-platform analysis	Reference range
T cells CD3	452 cells/mL 86.5%	672-2638 cells/mL 54.8-83.0%
T helper cells CD4	85 cells/mL 16.2%	292-1366 cells/mL 23.1-51.0%
Ts/c* CD8	285 cells/mL 54.6%	240-1028 cells/mL 17.9-47.5%
CD4:CD8 ratio	0.3	0.6-2.5
B cells CD19	0 cells/mL 0%	82-560 cells/mL 5.1-20.8%
Natural killer cells CD16/56	73 cells/mL 13.9%	130-938 cells/mL 7.1-38.0%
Immunoglobulin G (g/L)	6.66	8-18
Immunoglobulin M (g/L)	0.17	0.5-2.2
Immunoglobulin A (g/L)	0.77	1.1-5.6

\* Ts/c denotes T-suppressor/cytotoxic

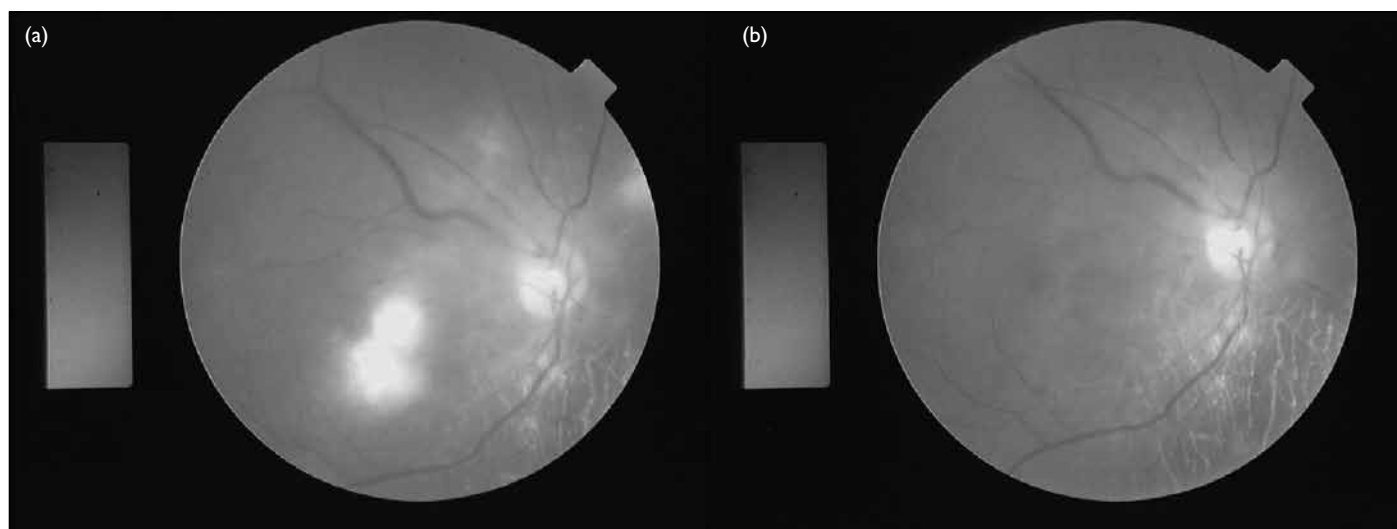


FIG. Right retina (a) before administration of intravenous ganciclovir showing patches of retinitis at the parafoveal region and superonasal quadrant, and vitreous haziness; and (b) after 2 weeks of intravenous ganciclovir showing that the retinitis resolved and the vitreous became clearer

pneumonia was made. A second colonoscopy was performed for the persistent diarrhoea. Despite a normal macroscopic appearance of the colon, random colonic biopsy revealed CMV inclusion bodies.

The retinographs of both eyes, reviewed by an ophthalmologist, showed features highly compatible with CMV infection, including patches of retinitis and vitreous haziness in the right eye and scarring in the left eye due to previous insults. As the patient's left eye was blind, right eye biopsy was not contemplated. A diagnosis of Good syndrome with disseminated CMV infection was made. He was treated with intravenous ganciclovir 5 mg/kg 12 hourly for 2 weeks, followed by lifelong oral maintenance with valganciclovir 900 mg daily for CMV retinitis. He also started trimethoprim-sulfamethoxazole 900 mg 3 times per week for *Pneumocystis jiroveci* pneumonia prophylaxis. Monthly Ig infusion was scheduled to maintain his IgG within the reference range. His respiratory and gastrointestinal conditions improved afterwards. He had a good appetite and gained weight. His right visual acuity improved from 6/60 to 6/30 (Fig). Follow-up high-resolution CT of the thorax in October 2009 showed chronic lung changes.

## Discussion

Good syndrome was first described in 1954 by Robert Good.<sup>2</sup> Good syndrome is characterised by low or absent circulating B lymphocytes, hypogammaglobulinaemia, CD4+ T-cell lymphopenia, and inverted CD4+ to CD8+ ratio. The condition is a rare adult-onset immunodeficiency disease associated with thymoma. Thymoma is found in 10% of patients with adult-onset hypogammaglobulinaemia<sup>3</sup> and there are less than 60 reported cases of Good syndrome worldwide at present. The mean age at onset of patients with Good syndrome is 56 years, which manifests with infection, thymoma, or hypogammaglobulinaemia. The full syndrome is generally established within 6 years of the onset of initial symptoms.<sup>4</sup>

This patient first presented with anaemia and neutropenia. Reports have suggested that anaemia is present in half of patients with Good syndrome.<sup>4</sup> Pure red cell aplasia is found in 35% of patients with Good syndrome, and aplastic anaemia, haemolytic anaemia, and pernicious anaemia have all been described.<sup>5-9</sup> Approximately 55% of patients with Good syndrome have a low white cell count, and 18% have neutropenia.<sup>10</sup> Thrombocytopenia is found in 20% of patients with Good syndrome.<sup>5</sup> Both pure red cell aplasia and neutropenia may respond to glucocorticosteroids, suggesting the possibility of an underlying autoimmune pathogenesis. Glucocorticosteroid therapy was not attempted

for this patient as his peripheral haemoglobin and neutrophil counts remained static during out-patient follow-up. The pathogenesis of immunodeficiency in patients with Good syndrome remains unknown, and reversal of the immunodeficiency after thymectomy has not been reported. However, thymectomy usually has favourable outcomes for associated conditions such as pure red cell aplasia and myasthenia gravis.

In this patient, the globulin levels were persistently normal despite having repeated infections and evidence of chronic inflammatory disease. Paradoxically, normal globulin levels could be a clue to hypoglobulinaemia in patients with Good syndrome with co-existing infections. The pathogenesis of hypogammaglobulinaemia is not well understood.

Infectious characteristics of patients with Good syndrome are recurrent sinopulmonary infection with encapsulated bacteria such as *H influenza* and *S pneumoniae*.<sup>10</sup> Lung abscess and empyema are rare, but bronchiectasis could develop in some patients, probably as a consequence of the low IgG levels. However, this patient did not contract tuberculosis, which is endemic in Hong Kong.

Gastrointestinal complications are common in patients with Good syndrome. Most patients with diarrhoea have no definite identifiable pathogens although CMV, *Giardia lamblia* and non-typhoidal *Salmonella* spp can occasionally be found.<sup>11</sup>

This patient also presented with acute visual deterioration, and the CMV retinitis and vitreous haziness in his right eye were completely resolved after intravenous ganciclovir. Other authors have reported that ocular manifestations of good syndrome may include toxoplasma retinitis and herpetic keratitis.<sup>11</sup>

Cytomegalovirus infection is rarely described in patients with normal immunity, but secondary reactivation of latent CMV infection is a common and characteristic manifestation of cell-mediated immunity defects. Patients with Good syndrome have reduced T-cell numbers and often have generalised defects in in-vitro T-cell proliferation in response to mitogens and antigens. There has been a report of CMV-specific defects in CMV-induced proliferation and interferon- $\gamma$  production in patients with Good syndrome.<sup>12</sup> Additionally, the lymphopenia in patients with Good syndrome is much less profound than in patients with HIV infection.<sup>13</sup> This suggests significant functional CD4+ T-cell defects in Good syndrome, and is supported by abnormal in-vitro lymphocyte studies in some patients.<sup>4,14</sup> In contrast, prolonged CD4+ T lymphopenia may be caused by acute CMV infection.

Although this patient had disseminated CMV infection, his peripheral CMV pp65 antigen was

negative. This can be explained by the limited number of available white blood cells, making it impossible to detect in leukopenic patients.

The mortality rate of patients with Good syndrome is higher than those with X-linked gammaglobulinaemia or common variable immunodeficiency. The 5- and 10-year survival rates of Good syndrome are 70% and 33%, respectively.<sup>11</sup>

In summary, these authors recommend checking Ig levels and lymphocyte subsets in patients with thymoma and considering the possibility of Good syndrome as soon as signs of infection are apparent. The investigations are simple, but a high index of suspicion is of paramount importance. In

addition, the immunological parameters may be normal initially, and it may be necessary to repeat the immunological investigations if Good syndrome is suspected.

As patients with immunodeficiency cannot mount appropriate immunological responses to infection, aggressive antimicrobial treatment for patients with Good syndrome presenting with evidence of infection is recommended. Patients with Good syndrome should have regular IgG infusions to maintain IgG at the lower end of the reference range and be given cotrimoxazole prophylaxis for *P jiroveci* pneumonia. Finally, while thymectomy does not restore immune function, it does help to prevent local invasion and metastatic spread.

## References

1. Travis WD, Brambilla E, Muller-Hermelink HK, Harris CC, editors. Pathology and genetics of tumours of the lung, pleura, thymus and heart. WHO classification of tumours. Lyon: IARC Press; 2004.
2. Good RA. Agammaglobulinaemia: a provocative experiment of nature. Bull Univ Minn Hosp Med Found 1954;26:1-19.
3. Rosenow EC 3rd, Hurley BT. Disorders of the thymus. A review. Arch Intern Med 1984;144:763-70.
4. Mitchell EB, Platts-Mills TA, Pereira RS, Malkovska V, Webster AD. Acquired basophil and eosinophil deficiency in a patient with hypogammaglobulinaemia associated with thymoma. Clin Lab Haematol 1983;5:253-7.
5. Crawford WW, Yusin JS, Klaustermeyer WB. Nonsurgical regression of thymoma following corticosteroid/azothioprine therapy. Ann Allergy Asthma Immunol 1999;83:13-6.
6. Murray WD, Webb JN. Thymoma associated with hypogammaglobulinaemia and pure red cell aplasia. Am J Med 1966;41:974-80.
7. Barnes RD, O'Gorman P. Two cases of aplastic anaemia associated with tumours of the thymus. J Clin Pathol 1962;15:264-8.
8. Mongan ES, Kern WA Jr, Terry R. Hypogammaglobulinemia with thymoma, hemolytic anemia, and disseminated infection with cytomegalovirus. Ann Intern Med 1966;65:548-54.
9. Davila DG, Ryan DH. Thymoma, hypogammaglobulinemia, and pernicious anemia. South Med J 1986;79:904-6.
10. Tarr PE, Sneller MC, Mechanic LJ, et al. Infections in patients with immunodeficiency with thymoma (Good syndrome). Report of 5 cases and review of the literature. Medicine (Baltimore) 2001;80:123-33.
11. Assi AC, Lightman S. Clinicopathologic reports, case reports, and small case series: cytomegalovirus retinitis in patients with Good syndrome. Arch Ophthalmol 2002;120:510-2.
12. Huissoon AP, Davies G, Cox RA, Sloper CM, Thomson BJ, Robins RA. Loss of cytomegalovirus-specific immunological memory in a patient with thymoma. Clin Exp Immunol 2002;129:297-301.
13. Kelleher P, Misbah SA. What is Good's syndrome? Immunological abnormalities in patients with thymoma. J Clin Pathol 2003;56:12-6.
14. McCune CA, Hughes S, Unsworth DJ. Thymoma, autoimmunity and fatal immunodeficiency. QJM 2000;93:559-60.