

Recurrent and consecutive non-arteritic optic neuropathy in a patient with protein S deficiency

Ian YH Wong 王逸軒
Simon CY Koo 顧智仁
Clement WN Chan 陳偉能

A 50-year-old man with a history of protein S deficiency treated by long-term warfarin presented with right non-arteritic optic neuropathy. Following successful augmentation of warfarin to minimise the effect of thrombophilia, he had a recurrence in the right eye and involvement of the left eye 11 days after the initial onset. Further investigation showed a marginal blood lipid profile, which was treated with lipid-lowering agents. A combination of aetiologies was seen in this patient. Other unique factors, such as the short duration to recurrence and involvement of the fellow eye, are discussed.

Case report

In August 2009, a 55-year-old Chinese man with a history of protein S deficiency presented to the Department of Ophthalmology, Tung Wah Eastern Hospital, Hong Kong, with a painless inferior visual field defect in his right eye since waking that morning. Protein S deficiency was diagnosed 10 years previously following recurrent episodes of deep vein thrombosis, which was treated by warfarin to maintain his international normalised ratio (INR) in the range of 2.0 to 2.5. He did not have thrombotic episodes, and control of his condition was satisfactory with no recurrence of thrombosis after initiation of warfarin. He did not smoke.

Examination at presentation showed best-corrected visual acuity of 20/50 in the right eye and 20/30 in the left eye. A visual field defect was found in the right eye, involving the temporal field, as shown in Figures 1 and 2. He also had a right afferent pupillary defect (APD) and dyschromatopsia. The right optic disc was crowded, hyperaemic, and swollen with blurred margins, and there was a splinter haemorrhage over the nasal side of the disc. The left eye visual field and colour vision were normal and the disc did not show any abnormalities apart from being crowded.

He did not have symptoms suggestive of arteritic optic neuropathy, such as headache, jaw claudication, neck pain, temporal fossa tenderness, or other systemic discomfort. Erythrocyte sedimentation rate (ESR) and C-reactive protein (CRP) were within the normal ranges. Owing to the lack of typical symptoms and the normal ESR/CRP results, giant cell arteritis or other arteritic optic neuropathies were thought to be unlikely diagnoses, so temporal artery biopsy was not performed. He had no previous episodes and did not have symptoms suggestive of multiple sclerosis. He was afebrile.

In view of the clinical presentation, history of thrombophilia, characteristic visual field defect, and a crowded swollen hyperaemic disc, non-arteritic ischaemic optic neuropathy (NAION) in the right eye was diagnosed. Apart from the total cholesterol level approaching the upper limit of normal range (5.0 mmol/L; reference level, <5.17 mmol/L), blood tests for other risk factors did not demonstrate significant abnormalities, and his blood pressure was normal. Magnetic resonance imaging (MRI) was performed to exclude compressive lesions and intracranial pathology.

Initially, the causative factor was thought to be thrombophilia and a haematologist was involved in the management. The patient was taking warfarin with a target INR of 1.5 to 2.0. His INR at presentation was 1.9. In view of the possible association of thrombophilia with NAION, the warfarin dose was increased from 3.5 mg to 4.0 mg, and the target INR was increased to 2.0 to 2.5. An INR of 2.3 was achieved within 7 days. Apart from redefining the target INR, a conservative approach to management was adopted, which proved to be successful initially. His condition improved and the visual function (pupil response, visual acuity, colour vision) in his right eye returned to near normal within 7 days. On day 7, the visual acuity in his right eye was 20/25 and the left eye remained at 20/30.

On day 11, he presented with bilateral visual deterioration on waking, which was worse on the left side. His visual acuity was 20/100 in the right eye and counting fingers in the left eye. Pupil reaction was sluggish bilaterally, but was worse on the left side

Key words

Arteritis; Blood protein; Optic neuropathy, ischemic; Thrombophilia; Vision disorders

Hong Kong Med J 2010;16:480-3

Department of Ophthalmology, Tung Wah Eastern Hospital, Causeway Bay, Hong Kong
IYH Wong*, MRCS(Ed)
SCY Koo, FHKAM (Ophthalmology)
CWN Chan, FHKAM (Ophthalmology)

* IYH Wong is now with the Eye Institute, University of Hong Kong.

Correspondence to: Dr IYH Wong
Email: ianyhwong@gmail.com

with a weakly positive left APD. Dyschromatopsia was positive bilaterally. Humphrey visual field test showed an inferior visual field defect in the right eye and a gross visual field defect in the left eye. There was no interval change in the appearance of the right disc, but the left disc was hyperaemic and swollen with blurred margins, and a splinter haemorrhage was noted inferiorly. The impression was recurrent NAION in the right eye and consecutive NAION in the left eye.

Repeated blood pressure values and blood tests—including immune markers, fasting glucose, Venereal Disease Research Laboratory, complete blood count, and liver and renal function—were all within the normal range. Lipid profile was approaching upper limit of normal range, ie total

一名蛋白S缺乏症患者出現復發性及連續發生的非動脈性視神經病變

一名因有蛋白S缺乏症而長期接受華法林 (warfarin) 藥物治療的50歲男性，病發時右眼出現非動脈性視神經病變。為把易栓症的影響減至最低，加強了病人服用華法林的劑量，可是他的右眼再次出現非動脈性視神經病變。首次病發的11天後，病人的左眼亦受牽連。進一步調查顯示病人的血脂形態呈邊際水平，遂施以降血脂劑。這名病人病發時出現多種症狀。本文亦會討論有關非動脈性視神經病變的特徵，包括復發期短及牽連另一只眼。

cholesterol 5.0 mmol/L, low-density lipoprotein (LDL) 3.12 mmol/L (reference range, 1.55-3.37 mmol/L), high-density lipoprotein 1.01 mmol/L (reference range, 0.91-1.68 mmol/L), and triglycerides 1.88 mmol/L (reference range, 0.11-2.15 mmol/L). His INR was 2.2.

After consultation with the haematologist, a further increase of warfarin was thought to predispose the patient to a risk of haemorrhage, and was not likely to produce a beneficial effect since a recurrence and consecutive NAION occurred despite a successful increase in INR during the previous week.

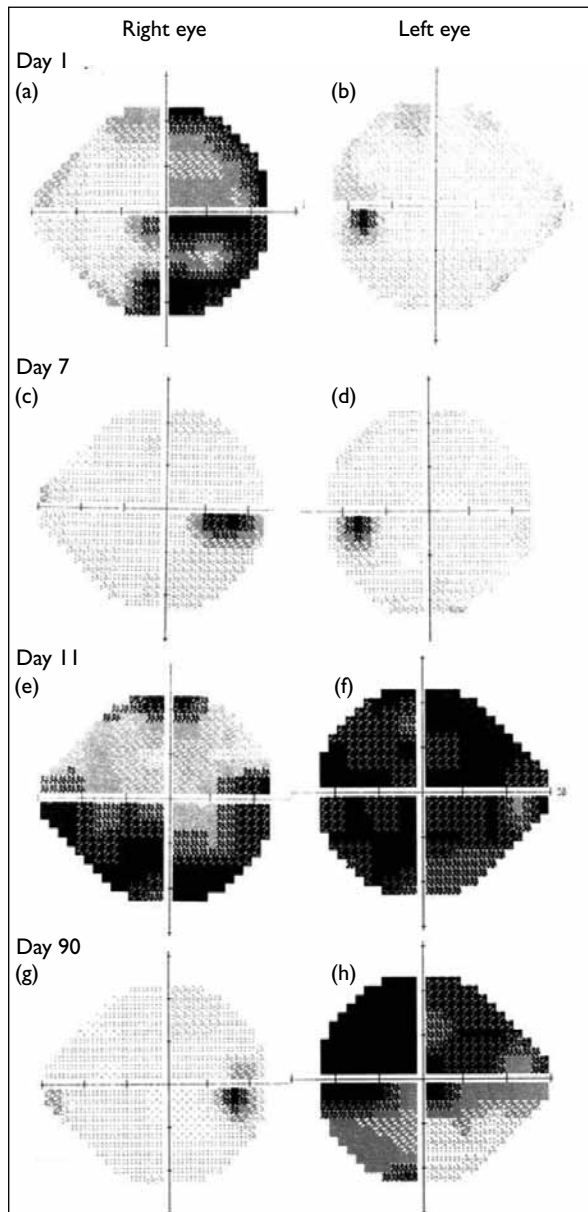


FIG 1. Humphrey visual field progression over time

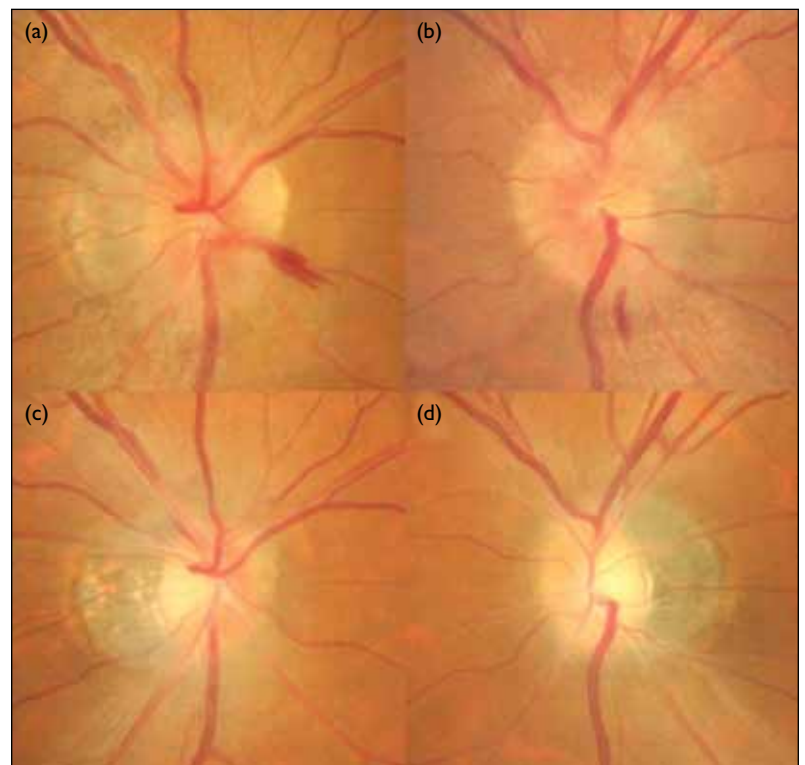


FIG 2. Disc photos of (a) the swollen right disc on day 1, with a nasal splinter haemorrhage, hyperaemia, and blurred margins; (b) the swollen left disc on day 11 with an inferior splinter haemorrhage, hyperaemia, and blurred margins; (c) the right disc and (d) left disc on day 90 showing resolution of the splinter haemorrhage and swelling, leaving disc pallor. The right disc shows temporal sectoral pallor, whereas the left disc shows diffuse pallor. Both discs are structurally crowded

A combined aetiology, rather than thrombophilia alone, was suspected. An effort was made to optimise his blood lipid profile to prevent further exacerbation of the condition. Atorvastatin 10 mg daily was started and, within 2 weeks, his total cholesterol decreased to 2.9 mmol/L, LDL to 1.45 mmol/L, and triglycerides to 0.96. Aspirin was considered, but after discussion with the haematologist it was deemed unnecessary because he was already taking warfarin, and there might not have been any added benefits from aspirin.

His condition stabilised and visual function recovered bilaterally, first in the right eye and then the left eye, with no further recurrences at his latest follow-up 4 months after the initial presentation.

Discussion

Non-arteritic ischaemic optic neuropathy is fairly commonly seen by general practitioners and ophthalmologists. The condition mimics other conditions presenting with sudden painless visual loss. Non-arteritic ischaemic optic neuropathy is caused by a partial or total infarction of the optic nerve head from occlusion of the short posterior ciliary arteries.¹ Classically, NAION occurs as an isolated event and affects middle-aged and elderly people. Predisposing factors include hypertension, diabetes, hypercholesterolaemia, collagen vascular disease, antiphospholipid antibody syndrome, sudden hypotensive events, and cataract surgery.¹

Non-arteritic ischaemic optic neuropathy typically presents with sudden painless unilateral visual loss on waking, and involves the inferior half of the visual field more than the superior half. Vision loss ranges from mild impairment to light perception only, and colour vision defect is proportional to vision loss. The pupil response varies from near normal to APD, and usually correlates with other findings. In the acute stage, a typical disc is hyperaemic with swollen margins, and may have splinter haemorrhages. A chronic or resolved disc is pale and either diffuse or sectoral corresponding to the nerve fibre damage. Important differential diagnoses include optic neuritis, association with multiple sclerosis, compressive optic neuropathy, and arteritic anterior ischaemic optic neuropathy, although the list is endless.

For optic neuritis, the presentation is classically acute unilateral painless visual loss in a young woman with a history of multiple sclerosis. There is usually APD and the disc is usually hyperaemic and swollen. The visual field defect is commonly diffuse. The atypical age and sex, and lack of history of multiple sclerosis or plaques on MRI of the brain reduced the likelihood of a diagnosis of optic neuritis for this patient. Compressive optic neuropathies can present at any age, and vision loss is more gradual.

Pupil response can be normal. Disc swelling is diffuse in the acute stage, but the disc can be pale in the chronic stage. Classically, opticociliary shunts can be seen on the disc surface. Common aetiologies include optic nerve sheath meningioma and optic nerve glioma. The bilaterality and acute presentation of this patient made this diagnosis unlikely. Arteritic anterior ischaemic optic neuropathy typically occurs in older women with giant cell arteritis. Classically, there is dramatic vision loss associated with APD, jaw claudication, temporal fossa pain, and neck pain. The disc is classically chalky white and swollen. Bilateral involvement is common and urgent temporal artery biopsy is required for suspected cases. The lack of typical symptoms and age mismatch made this diagnosis unlikely. A rare differential diagnosis is Leber's hereditary optic neuropathy (LHON), which is a mitochondrial disease typically seen in young men in their twenties, with sudden loss of vision in one eye followed by involvement of the fellow eye in the next days or weeks. The vision usually remains poor (can be <6/60) in the long term. For this patient, this was a diagnosis of exclusion, but in view of the more likely diagnosis of NAION, further examination for LHON was deemed unnecessary.

This patient most likely had an episode of NAION in the right eye followed by a rapid recovery, and subsequently had a recurrence in the right eye together with a first episode in the left eye.

Apart from structurally crowded discs, protein S deficiency and hyperlipidaemia may have contributed to the development of an ischaemic optic neuropathy. According to a report by Salomon et al,² thrombophilia is not positively associated with NAION, as the high-flow rate within the arteries makes them less prone to developing microemboli. However, a report by Kuhl-Hattenbach et al³ found a high prevalence of thrombophilia among patients with NAION population. In this patient, after the first episode of NAION, the target INR was raised, but this failed to prevent the recurrence. Therefore, other aetiologies were likely to be involved.

While structurally crowded optic nerve heads are inborn and cannot be changed, the only other preventable risk factor was hyperlipidaemia. Atorvastatin was started after the recurrence and involvement of the fellow eye to minimise this risk factor. Following successful lowering of the patient's total cholesterol from 5.0 mmol/L to 2.9 mmol/L, his condition stabilised and improved gradually without further recurrences. This suggests that hyperlipidaemia was likely to be responsible for inducing the condition, in addition to a possible contribution from thrombophilia. This is in agreement with the report by Deramo et al,⁴ which supports the finding that NAION may be the initial presentation in a young patient with a raised lipid profile.

A peculiar feature in this patient was the short period to the involvement of the fellow eye. In a report by Newman et al,⁵ the interval to the involvement of the fellow eye ranged from 2 weeks to 22 years. In this patient, the interval between the first episode in the right eye to the occurrence in the left eye was only 11 days, which is shorter than the shortest interval reported.⁵

Another unusual feature was the recurrence of NAION in the right eye. According to the textbooks, NAION does not recur.⁶ In this patient however, NAION clearly did recur, as demonstrated by the visual field progression, which is in agreement with other reports.⁷ In a report by Hayreh et al,⁷ recurrence of NAION was found in 6.4% of 829 eyes. However, thrombophilia and hyperlipidaemia were not mentioned to be associated with recurrence of NAION. In our patient, a combination of aetiologies

may have contributed to the recurrence seen in the right eye. A possible explanation is that during the first insult, the ischaemic interval was so transient that reperfusion took place before irreversible damage occurred. As the causative factor was not corrected, a recurrence occurred within a short period.

In another report, improvement in visual function may be seen up to 6 months after the initial NAION attack.⁸ As it is only 4 months after the onset for this patient, there is still time for progress and more improvement may occur in the future. In the meantime, the target INR remains 2.0 to 2.5 and his cholesterol is kept low to provide an optimum environment for the optic nerve to regain its function.

For any patient with NAION, even with an apparent cause (protein S deficiency in this patient), other underlying confounding factors should still be sought.

References

1. Kanski JJ. *Clinical ophthalmology, a systemic approach*. 5th ed. London: Butterworth Heinemann; 2003.
2. Salomon O, Huna-Baron R, Kurtz S, et al. Analysis of prothrombotic and vascular risk factors in patients with nonarteritic anterior ischemic optic neuropathy. *Ophthalmology* 1999;106:739-42.
3. Kuhli-Hattenbach C, Scharrer I, Luchtenberg M, Hattenbach LO. Selective thrombophilia screening of patients with nonarteritic anterior ischemic optic neuropathy. *Graefes Arch Clin Exp Ophthalmol* 2009;247:485-90.
4. Deramo VA, Sergott RC, Augsburger JJ, Foroozan R, Savino PJ, Leone A. Ischemic optic neuropathy as the first manifestation of elevated cholesterol levels in young patients. *Ophthalmology* 2003;110:1041-6.
5. Newman NJ, Scherer R, Langenberg P, et al. The fellow eye in NAION: report from the ischemic optic neuropathy decompression trial follow-up study. *Am J Ophthalmol* 2002;134:317-28.
6. Smith JL, Glaser JS, editors. *Neuro-Ophthalmology Symposium of the University of Miami and the Bascom Palmer Eye Institute*. St Louis: Mosby; 1973: xi, 47.
7. Hayreh SS, Podhajsky PA, Zimmerman B. Ipsilateral recurrence of nonarteritic anterior ischemic optic neuropathy. *Am J Ophthalmol* 2001;132:734-42.
8. Hayreh SS, Zimmerman MB. Nonarteritic anterior ischemic optic neuropathy: natural history of visual outcome. *Ophthalmology* 2008;115:298-305.e2.