

A 61-year-old woman with adenocarcinoma of the left upper lobe of the lung and no hilar or mediastinal lymphadenopathy had a video-assisted thoracoscopic left upper lobectomy. A week after operation, the patient developed fever, cough, and shortness of breath. Chest radiograph showed opacified left hemithorax with abnormal air lucency in the upper zone (Fig 1). She was treated for chest infection. Bronchoscopy revealed a swollen left lower lobe bronchial orifice, although the bronchoscope could still pass through. The left upper lobe bronchial stump was intact. Contrast-enhanced computed tomographic (CT) scan was performed to exclude complications in view of the slow clinical improvement. Computed tomography showed abrupt termination and complete obstruction of the left lower lobe bronchus at its origin (Fig 2). The left lower lobe was situated at an abnormally high position in the thorax, which also showed areas of poor contrast enhancement and cavity formation. To further assess the status of the hilar structure, multiplanar reformation and volume rendering were performed at a workstation. On the volume-rendered image, the patient's left lower lobe pulmonary artery showed an anticlockwise twist (viewed from the left side of the patient) and had an abnormal cranial course (Fig 3). The diagnosis of left lower lobe torsion

was established and the findings were confirmed at thoracotomy and complete pneumonectomy was performed.

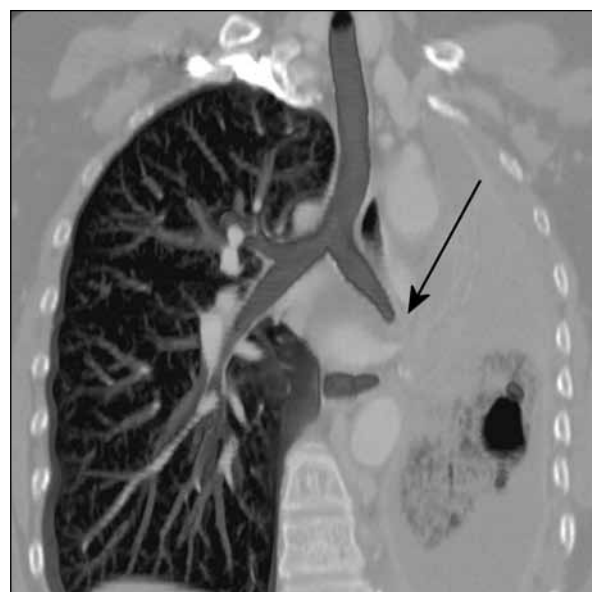

FIG 2. Coronal maximum-intensity projection computed tomographic image showing abrupt termination and complete obstruction of the left lower lobe bronchus at its origin (arrow)

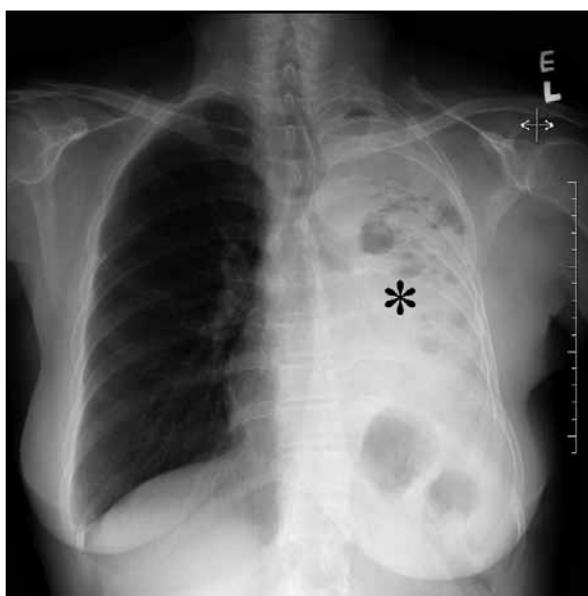


FIG 1. Chest radiograph showing an opacified left hemithorax with abnormal air lucency in the upper zone (*)

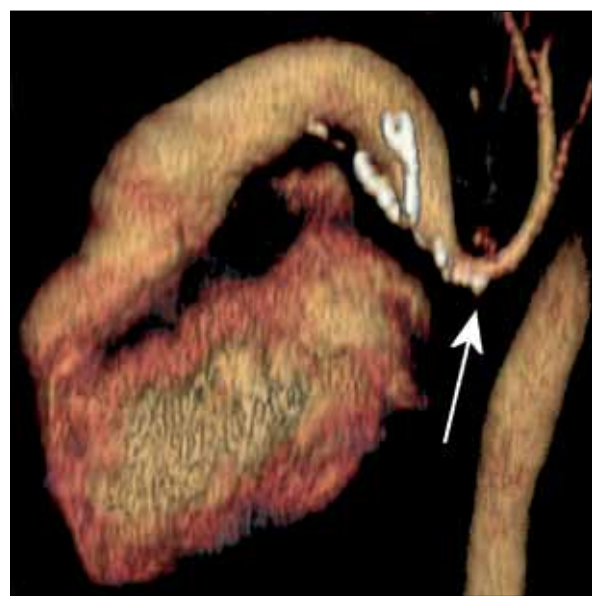

FIG 3. Volume-rendered computed tomographic image from the left side of the patient showing an anticlockwise twist of the left pulmonary artery, centred on the hilum, with a cranial instead of a normal caudal course (arrow)

Discussion

Lung torsion can follow surgery or trauma, or occur spontaneously. Lobar torsion after lobectomy occurs in 0.09 to 0.40% of patients.^{1,2} Right middle lobe torsion after upper lobectomy is commonest, and any lobe can be affected.² The clinical presentation varies from mild cough and dyspnoea to shock or air leak.¹ Plain radiography findings are of consolidation and collapse, with the involved lobe occupying an unusual position in the thorax.^{1,3} Apart from demonstrating the effects of torsion of infarct,⁴ infection, and pleural reaction, detailed analysis of the pulmonary vasculature can enable a definitive diagnosis of torsion to be made.^{3,5} This can avoid diagnostic delay especially in early cases when the lung CT findings are similar to those of infection or retained secretions. Multiplanar and volumetric image viewing at a workstation

facilitate accurate diagnosis and communication of findings to clinicians. These post-data capture processing procedures are also cost-effective as they can be easily performed with a standard reformat protocol that does not require additional imaging or manpower, or excessive time. Multiplanar CT with volumetric images should therefore be considered as routine for the assessment of postoperative patients.

Sonia HY Lam, MB, BS, FRCR

Email: sonia.lam@gmail.com

Stephen CW Cheung, MRCP, FHKAM (Radiology)

WK Tso, FRCR, FHKAM (Radiology)

Department of Radiology

Queen Mary Hospital

Pokfulam

Hong Kong

References

1. Hennink S, Wouters MW, Klomp HM, Baas P. Necrotizing pneumonitis caused by postoperative pulmonary torsion. *Interact Cardiovasc Thorac Surg* 2008;7:144-5.
2. Kanemitsu S, Tanaka K, Suzuki H, Tokui T, Kinoshita T. Pulmonary torsion following right upper lobectomy. *Ann Thorac Cardiovasc Surg* 2006;12:417-9.
3. Enön S, Kumbasar U, Kayi Cangir A, Atasoy C, Kavukçu S. A new non-invasive diagnostic method for lung lobe torsion: pulmonary CT angiography. *Tuberk Toraks* 2007;55:83-6.
4. Gilkeson RC, Lange P, Kirby TJ. Lung torsion after lung transplantation: evaluation with helical CT. *AJR Am J Roentgenol* 2000;174:1341-3.
5. Kanaan S, Boswell WD, Hagen JA. Clinical and radiographic signs lead to early detection of lobar torsion and subsequent successful intervention. *J Thorac Cardiovasc Surg* 2006;132:720-1.