

# Successful management of cholecystocolic fistula by endoscopic retrograde cholangiopancreatography: a report of two cases

Edward C Toll  
Michael D Kelly

Cholecystocolic fistula is a rare cause of diarrhoea, and the diagnosis may be significantly delayed. Air in the biliary tree on imaging should raise suspicion, and barium enema or endoscopic retrograde cholangiopancreatography will be diagnostic. Cholestyramine should provide effective symptomatic relief until definitive treatment is arranged. We report on two patients with cholecystocolic fistula presenting with severe diarrhoea. They were treated successfully by endoscopic retrograde cholangiopancreatography.

## Introduction

Cholecystocolic fistula is a rare cause of diarrhoea due to the action of bile salts in the colon. Cholecystocolic fistula tends to occur in elderly patients, not all of whom have a history of cholecystitis or gallstones. The clinician may be alerted to the diagnosis by the finding of air in the biliary tree on imaging. This report describes two patients with cholecystocolic fistula, and highlights that it is a rare cause of diarrhoea and that it can be successfully treated by endoscopic retrograde cholangiopancreatography (ERCP).

## Case reports

### Case 1

A 64-year-old woman with a 3-week history of severe diarrhoea was admitted to Frenchay Hospital, Bristol, United Kingdom, in November 2007 with dehydration and acute renal failure. She had multiple medical co-morbidities including chronic obstructive pulmonary disease, heart failure, reflux oesophagitis, and asymptomatic gallstones. Stool samples examined by microscopy showed both negative culture and *Clostridium difficile* toxin. Liver function tests were normal and a plain abdominal radiograph was normal. Abdominal ultrasound showed a contracted gallbladder with stones, but did not detect air in the biliary tree, which was shown on a subsequent computed tomographic (CT) scan. She was referred to the Department of Upper Gastrointestinal Surgery because of the air in the biliary tree, although the significance of this in relation to the diarrhoea had not been appreciated and she had not been given cholestyramine. She underwent ERCP, which clearly showed a fistula between the gallbladder and the hepatic flexure of the colon (Fig 1). A 10-French straight plastic stent was placed without sphincterotomy. The diarrhoea resolved and because of her co-morbidities, a decision was made not to proceed with cholecystectomy. At repeated ERCP 7 months later, the stent was removed and a formal sphincterotomy carried out after cholangiography had shown that the fistula had closed. She is well 2 years after her initial presentation, and there is no plan for elective cholecystectomy.

### Case 2

An 84-year-old previously healthy woman was referred to the colorectal out-patient clinic in July 2007 with a 3-month history of loose stools and mild abdominal pain preceding defecation. Abdominal examination revealed no abnormality and rectal examination, rigid sigmoidoscopy, and proctoscopy were unremarkable. A barium enema revealed a fistulous tract between the hepatic flexure and gallbladder (Fig 2). A subsequent CT scan done 6 weeks later demonstrated air in the biliary tree with a fistulous connection between the hepatic flexure and a thick-walled gallbladder. Liver function was abnormal with a bilirubin level of 28  $\mu\text{mol/L}$  (reference range, 3–22  $\mu\text{mol/L}$ ) and an alkaline phosphatase level of 348 IU/L (20–110 IU/L). She was referred to the Department of Upper Gastrointestinal Surgery, where she was given cholestyramine and an ERCP demonstrated a fistula. A 7-French pigtail stent was inserted after sphincterotomy. Four months later, at repeated ERCP, the fistula was found to be closed and the stent was removed. At review 18 months after presentation,

#### Key words

Biliary fistula; Contrast media; Diarrhea; Enema

*Hong Kong Med J* 2010;16:406–8

Department of Upper Gastrointestinal  
Surgery, Frenchay Hospital, Bristol,  
United Kingdom

EC Toll\*, MB, ChB, MRCS

MD Kelly, FRACS, FRCS

\* Currently at: Department of Plastic and  
Reconstructive Surgery, Frenchay Hospital,  
United Kingdom

Correspondence to: Dr EC Toll  
Email: edtol@gmail.com

she is asymptomatic and there is no plan for elective cholecystectomy.

## Discussion

A cholecystoenteric fistula probably occurs when acute and chronic inflammation causes adhesion of the gallbladder to the bowel. Inflammation coupled with pressure from a gallstone may result in necrosis of tissue and fistula formation. In addition to cholecystitis, cholecystocolic fistulae have been reported to occur secondary to inflammatory bowel

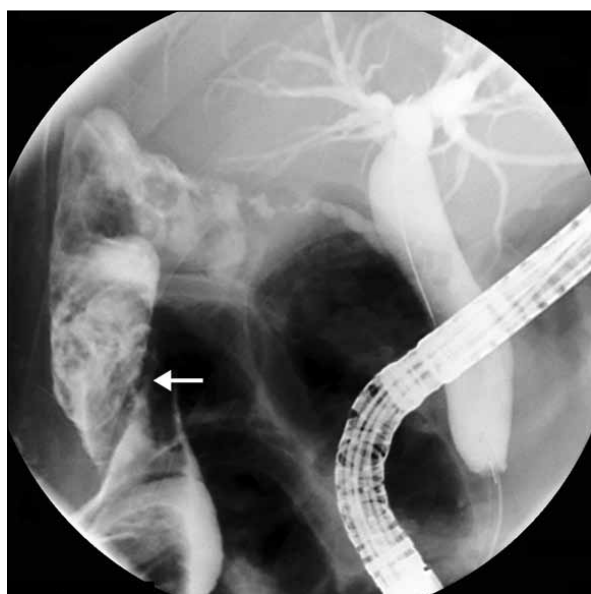


FIG 1. Endoscopic retrograde cholangiogram showing contrast opacifying the ascending colon (arrow)

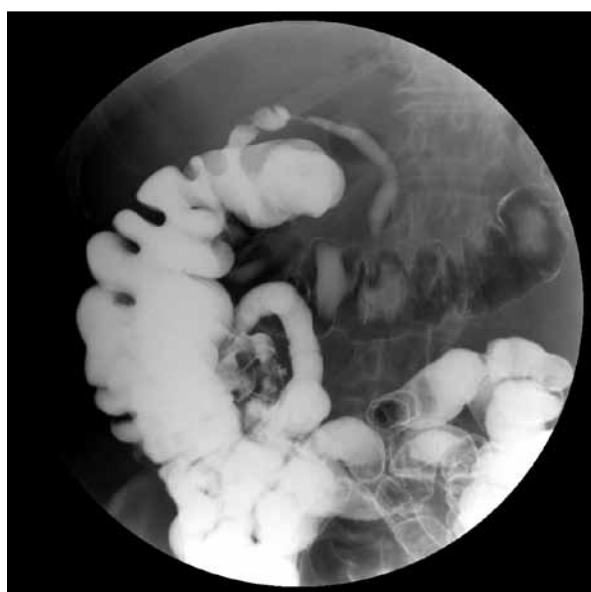

FIG 2. Barium enema showing a fistulous tract between the hepatic flexure and common bile duct

## 用內鏡逆行胰膽管造影成功醫治膽囊結腸瘤的兩個病例報告

由於膽囊結腸瘤引致腹瀉極為罕有，病人很可能會被延診。如果膽管樹在影像上顯示有空氣，醫護人員須提高警覺，並使用鉭劑灌腸造影或內鏡逆行胰膽管造影來診斷病症。消膽胺可以提供有效的症狀緩解，直至病人得到確定性治療為止。本文報告兩名膽囊結腸瘤患者病發時出現嚴重腹瀉，後經內鏡逆行胰膽管造影成功診斷而得到醫治。

diseases, abdominal trauma, and malignancy of the colon, biliary system, and head of the pancreas.<sup>1-3</sup> Forty-nine relevant English-language articles demonstrating the varied clinical features and management options for cholecystocolic fistula were found in a search of the Medline database using the terms "cholecystocolic" (all fields) AND "fistula" (all fields). Cholangitis can be a presenting feature, with Hession et al<sup>4</sup> reporting cholangitis in one of seven patients with cholecystocolic fistulae, although most presented as an incidental operative finding in patients with symptomatic gallstones. Cholecystocolic fistulae may also present with diarrhoea without symptoms attributable to the gallbladder, as for the two patients in this report. The most serious consequences of this disease are chronic diarrhoea, massive lower gastro-intestinal haemorrhage, and colonic gallstone ileus.<sup>5,6</sup> Cholecystoenteric fistulae are found in approximately 0.5% of patients undergoing cholecystectomy and most involve the duodenum, with cholecystocolic fistulae comprising 10 to 20% of biliary-enteric fistulae.<sup>7</sup>

Bile salts are essential for lipid absorption in the small intestine, where they undergo an enterohepatic circulation, with most being reabsorbed by an active process in the terminal ileum. Disease or resection of the terminal ileum or, as in these patients, a fistula can lead to high concentrations of bile salts in the colon and a secretory diarrhoea. The medical treatment of diarrhoea due to a cholecystocolic fistula is with the bile acid sequestrant cholestyramine, which is an anion exchange resin that forms insoluble complexes with bile acids in the intestine.<sup>8</sup> The severity of these patients' diarrhoea had decreased prior to commencing cholestyramine and this may represent a relative bile salt depletion.

While diarrhoea is common, cholecystoenteric fistula is rare and the diagnosis may be significantly delayed (by up to 2 years in one series).<sup>4</sup> There may not be a history of gallstones, as with one of these patients. Colonoscopy may miss the fistula, although good-quality barium enema should be diagnostic. Air in the biliary tree may also be missed on plain abdominal radiograph or ultrasound although CT

scan should detect it. This finding, in combination with diarrhoea, should alert clinicians to the possibility of a cholecystocolic fistula and cholestyramine should be commenced.

Modern techniques should allow safe laparoscopic cholecystectomy, even for patients with cholecystocolic fistula.<sup>7</sup> In cholecystoenteric fistulae, the opening into the bowel is usually small and may not even be apparent. The area tends to be friable due to inflammation and granulation tissue. Laparoscopic options include attempting to suture the defect, placing a drain into it or inserting a T-tube into the defect. On occasion, it may be safer to convert to open surgery. However, ERCP stenting and/or sphincterotomy is a less invasive and safer alternative. It is likely that the gallbladder would have already, at least partially, emptied itself

of stones into the colon. When the resistance of the choledochal sphincter is overcome by stenting, bile will preferentially flow into the duodenum rather than through the fistula. The fistula would then be expected to close over a period of time, as shown by these two patients, although sphincterotomy was selected as a definitive procedure. Whenever a diseased gallbladder is left in situ, there is a small risk of development of gallbladder cancer and this risk must be balanced against the risk of elective surgery for an asymptomatic patient.

Clinicians should be aware that cholecystocolic fistula is a rare cause of diarrhoea, which is more likely to occur in elderly patients with co-morbidities. Treatment with cholestyramine and ERCP can be curative.

## References

1. LeBlanc KA, Barr LH, Rush BM. Spontaneous biliary enteric fistulas. *South Med J* 1983;76:1249-52.
2. Rastogi R. Cholecystocolic fistula secondary to gallbladder carcinoma: a rare case. *Saudi J Gastroenterol* 2008;14:144-6.
3. Ahn SI, Hong KC, Hur YS, et al. Cholecystocolic fistula caused by blunt trauma. *Injury* 2001;32:341-2.
4. Hession PR, Rawlinson J, Hall JR, Keating JP, Guyer PB. The clinical and radiological features of cholecystocolic fistulae. *Br J Radiol* 1996;69:804-9.
5. Swinnen L, Sainte T. Colonic gallstone ileus. *J Belge Radiol* 1994;77:272-4.
6. Kaplan BJ. Massive lower gastrointestinal hemorrhage from cholecystocolic fistula. *Dis Colon Rectum* 1967;10:191-6.
7. Chowbey PK, Bandyopadhyay SK, Sharma A, Khullar R, Soni V, Baijal M. Laparoscopic management of cholecystoenteric fistulas. *J Laparoendosc Adv Surg Tech A* 2006;16:467-72.
8. Fromm H, Malavolti M. Bile acid-induced diarrhoea. *Clin Gastroenterol* 1986;15:567-82.