

Ambiguous genitalia, impaired steroidogenesis, and Antley-Bixler syndrome in a patient with P450 oxidoreductase deficiency

WM But 畢慧文
Ivan FM Lo 盧輝文
CC Shek 石志忠
WY Tse 謝詠儀
Steven TS Lam 林德深

Cytochrome P450 oxidoreductase deficiency is a recently established autosomal recessive disease characterised by ambiguous genitalia, impaired steroidogenesis, and skeletal malformations, referred to as Antley-Bixler syndrome. Clinical manifestations in affected patients are highly variable. We report on a girl with P450 oxidoreductase deficiency who presented with virilisation at birth. There was transient maternal virilisation during pregnancy as well. She was initially diagnosed with congenital adrenal hyperplasia caused by 21-hydroxylase deficiency and/or aromatase deficiency. At 1 year of age, skeletal abnormalities suggestive of Antley-Bixler syndrome were detected. Molecular analysis of the fibroblast growth factor receptor 2 (*FGFR2*) gene was normal but *POR* gene analysis showed that she was homozygous for an R457H missense mutation. The diagnosis, P450 oxidoreductase deficiency, was confirmed. Results of her endocrine studies and urinary steroid profiling are also presented.

Case report

The proband is a 10-year-old Nepalese girl. She was born at term with a birth weight of 3.3 kg. She was the first child in the family and her parents are first cousins. There was no family history of ambiguous genitalia, neonatal death, or skeletal abnormalities. Maternal virilisation—deepening of voice and clitoromegaly—were noted from the second trimester. After birth, the baby was found to have mild dysmorphic features including a prominent forehead, hypertelorism, a flat nasal bridge, and a prominent nose. The external genitalia were ambiguous. The phallus measured 1 cm in length and 0.6 cm in width. The labial folds were fused and pigmented with rugae. There was a single urogenital opening. Both gonads were impalpable and the anus was sited normally (Fig a). She was healthy and her blood pressure remained normal. Investigations showed normal electrolytes with no evidence of salt wasting. On day 3 after birth, her blood sugar was 4.0 µmol/L, plasma renin activity 6.3 ng/mL/h (reference range [RR], 2.0-35.0 ng/mL/h), 17-hydroxyprogesterone (17-OHP) 58 nmol/L (RR, 0.3-12.1 nmol/L), testosterone 0.3 nmol/L (RR, 0.4-1.0 nmol/L), luteinising hormone (LH) 1.9 IU/L (reference level, <0.5 IU/L), follicle-stimulating hormone (FSH) 9.3 IU/L (RR, 0.4-7.1 IU/L), and spot cortisol 143 nmol/L. An abdominal ultrasonogram showed an elongated soft tissue structure at the midline, compatible with a uterus. No ovaries were detected. Maternal blood taken on day 4 after delivery showed elevated testosterone (21.8 nmol/L; RR, 0.8-2.8 nmol/L) and 17-OHP (40.0 nmol/L) levels but both dropped to normal within 2 weeks. She was initially diagnosed with congenital adrenal hyperplasia caused by 21-hydroxylase deficiency (P450C21) and/or aromatase deficiency and was treated with glucocorticoid replacement therapy. The 17-OHP levels normalised on hormone replacement therapy. Corrective surgery was performed at around 3 years of age. She developed hydrocephalus at 6 months of age but this was managed conservatively.

Key words

Abnormalities, multiple; Cytochrome P-450 enzyme system; Genitalia, female; NADPH-ferrihemoprotein reductase; Steroids

Hong Kong Med J 2010;16:59-62

Queen Elizabeth Hospital, 30 Gascoigne Road, Hong Kong;
Department of Paediatrics
WM But, MB, BS, FRCP
WY Tse, MB, BS, FRCP
Department of Pathology
CC Shek, MB, BS, FRCPATH
Clinical Genetic Service, Department of Health, Hong Kong
IFM Lo, MRCP, FHKAM (Paediatrics)
STS Lam, FRCP, FHKAM (Paediatrics)

Correspondence to: Dr WM But
Email: butwm@ha.org.hk

Owing to the genital ambiguity, the patient was referred to the Clinical Genetic Service soon after birth. Urgent karyotyping showed a normal 46,XX set of chromosomes. She was diagnosed with Antley-Bixler syndrome (ABS) at 1 year of age. This was based on the parental consanguinity, genital ambiguity, adrenocortical insufficiency, and characteristic dysmorphic features including frontal bossing, brachycephaly, a large fontanelle, craniosynostosis, proptosis, mid-face hypoplasia, depressed nasal bridge, dysplastic ears, and restricted elbow extension and supination. Radiographs showed a decreased skull anteroposterior diameter and bilateral coronal craniosynostosis. Arachnodactyly was noted but no definite synostosis or bowing of the long bones was seen (Fig b). Molecular analysis of the fibroblast growth factor receptor 2 (*FGFR2*) gene was performed in view of the craniosynostosis and reports of *FGFR2* mutations causing ABS or ABS-like phenotypes in the literature. Mutational analysis using polymerase chain reaction (PCR) followed by direct sequencing of exons 8 and 10 of the *FGFR2* gene, which is the mutational hotspot, was done at the Genetic Laboratory of the Clinical Genetic Service.

一名有P450氧化還原酶缺乏症的病人出現外陰性別不明、類固醇生成受損及Antley-Bixler症候群

細胞色素P450氧化還原酶缺乏症是一種最近發現的常染色體隱性遺傳病，病徵為外陰性別不明、類固醇生成受損及骨骼畸形，統稱為Antley-Bixler症候群。患者的臨床表現差異很大。本文報告一名患有P450氧化還原酶缺乏症的女孩，她出生時有男性化的特徵，其母親於妊娠期間亦出現短暫的男性化特徵。患者起初被診斷為患上先天性腎上腺增生症，病因為21-羥化酶缺乏症以及/或者芳香酶缺乏症。患者一歲時出現骨骼畸形，遂被診斷為患上Antley-Bixler症候群。分子分析顯示成纖維細胞生長因子受體2 (FGFR2) 基因正常，但POR基因分析證實患者的R457H基因發生同型合子錯義突變，最後被確診為P450氧化還原酶缺乏症。本文並發表有關患者內分泌研究及尿液類固醇的資料。

No mutations were detected. When she was 7 years of age, a *POR* gene analysis, using PCR followed by direct sequencing of all the coding exons (1-15) of the *POR* gene, was performed at the same genetic laboratory. This was performed because Flück et al¹ reported mutations in the gene that encodes P450 oxidoreductase (POR) in four patients who had disordered steroidogenesis with and without ABS. She was found to be homozygous for the c.1370G→A mutation, which is a missense mutation that changes the amino acid code of the 457th codon from arginine to histidine (R457H). Both parents are heterozygous for the same mutation. The diagnosis of ABS due to POR deficiency was confirmed.

At 4 and 5 years of age, she went into adrenal crises with dehydration and hypoglycaemia after vomiting caused by gastroenteritis. She was managed with intravenous fluids, glucose, and hydrocortisone.

At 8 years of age, endocrine studies were performed after hydrocortisone was stopped for 2 days. She was prepubertal at that time. Serum adrenal steroids were measured before and after an adrenocorticotrophic hormone (ACTH) stimulation test (250 µg/m² bolus intravenous [IV]). Basal and peak serum LH and FSH were obtained during a gonadotropin releasing hormone (LHRH) stimulation test (100 µg/m² bolus IV). In addition, basal plasma ACTH, renin activity, and serum oestradiol were obtained. The results are shown in the Table. In brief, she had increased basal and ACTH-stimulated serum concentrations of progesterone and 17-OHP, low-to-normal basal and ACTH-stimulated serum concentrations of dehydroepiandrosterone sulphate (DHEA-S), and low-to-normal basal testosterone. This was compatible with both P450C21 and P450C17 deficiency. Her ACTH was elevated at baseline. Her cortisol was also normal at baseline but did

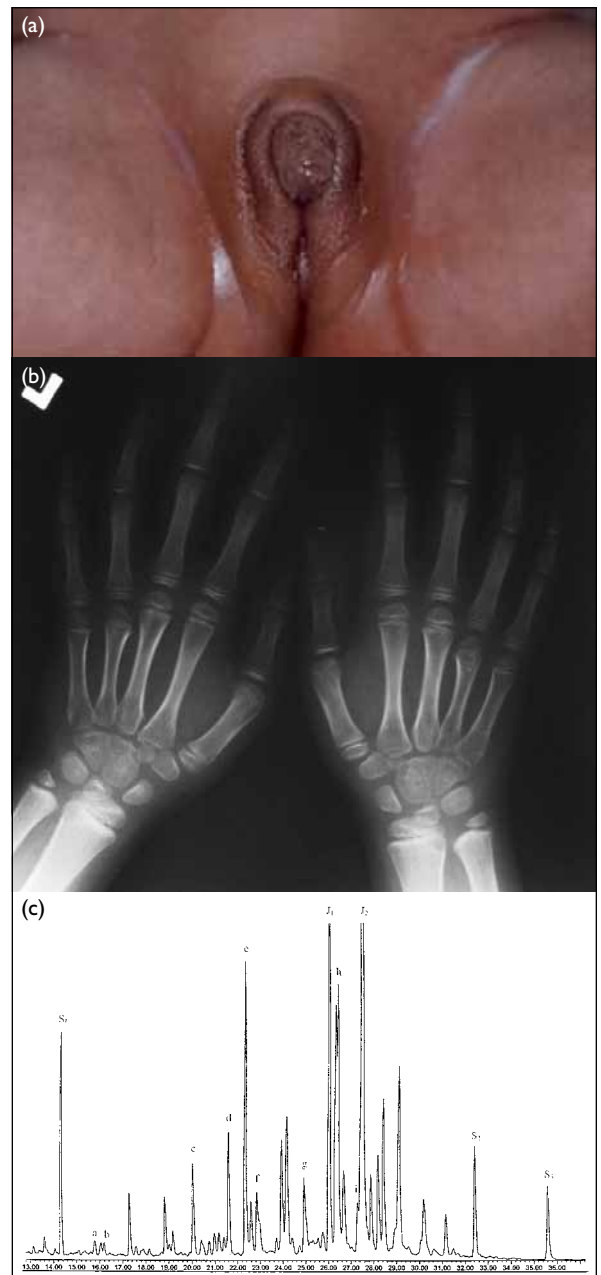


FIG. (a) External genitalia with clitoromegaly and complete labial fusions (virilisation) at birth. (b) Radiograph showing arachnodactyly. (c) Gas chromatogram of urinary steroid profiling of the patient

a, Androsterone; b, Aetiocolanalone; c, 17-hydroxypregnanolone; d, Pregnanediol; e, Pregnanetriol; f, Pregnenediol; g, 11-oxo-pregnanetriol; h, Tetrahydrocortisone; i, Tetrahydrocorticosterone; S1-3, Internal standards; J1-2, Impurity peaks

not increase after ACTH stimulation, suggesting primary adrenal insufficiency. The renin activity was slightly increased and her aldosterone was elevated. The mineralocorticoid synthesis pathway appeared to be well compensated for, probably due to residual POR activity. The basal levels of LH, FSH and oestradiol were compatible with levels expected

during the prepubertal stage of development. After gonadotropin stimulation, she had a predominant rise in FSH. An ultrasonogram of her pelvis showed normal ovaries with no cysts. Her fasting total cholesterol was 3.9 mmol/L.

Urinary steroid profiling showed excretion of pregnenediol (a metabolite of pregnenolone), pregnanediol (a metabolite of progesterone), tetrahydrocorticosterone (a metabolite of corticosterone), 17-hydroxypregnanolone, pregnanetriol and 11-oxo-pregnanetriol were increased (all three are metabolites of 17-OHP). Androgen metabolites were either present at low levels or undetectable. Cortisol metabolites were present in moderate quantities. These findings are compatible with POR deficiency. The moderate quantities of cortisol metabolites found in this sample may have been residues of recent hydrocortisone therapy or due to partial cortisol insufficiency (Fig c).

Discussion

To our knowledge, this is the first reported case of cytochrome POR deficiency in Hong Kong. Such deficiency is a recently established autosomal recessive disease caused by mutations in the *POR* gene,^{1,2} which is located on chromosome 7q11.2, and shows ubiquitous expression.³ P450 oxidoreductase is a flavoprotein which catalyses electron transfer from reduced nicotinamide adenine dinucleotide phosphate (NADPH) to all microsomal cytochrome P450 enzymes, including the enzymes lanosterol 14 α -demethylase (CYP51), 17 α -hydroxylase and 17,20 lyase (P450C17), 21-hydroxylase (P450C21) and aromatase (CYP19).^{4,6} Affected patients are born with ambiguous genitalia associated with defects in steroidogenesis, often, but not invariably, associated with other congenital abnormalities especially skeletal malformations.^{1,2}

In girls with POR deficiency, like our patient, both prenatal androgen excess and postnatal androgen deficiency may be found. At birth ambiguous genitalia and virilisation are present but the virilisation does not progress after birth, due to low or normal androgen concentrations as a result of P450C17 deficiency. Despite a partial deficiency of P450C17 which catalyses the biosynthesis of dehydroepiandrosterone (DHEA) and androstenedione, precursors of the active androgens testosterone and 5 α -dihydrotestosterone, virilisation of the genitalia occurs in affected girls. The deficiency of P450 aromatase leads to an accumulation of androgens from the foetal adrenals because androstenedione and testosterone, derived from maternal DHEA, are converted to 5 α -dihydrotestosterone instead of being aromatised to oestrone and oestradiol in the placenta. This causes virilisation of the affected female foetus and the

TABLE. Summary of blood hormone data

Blood hormone data*	Time (minutes)			Reference range/level
	0	30	60	
Adrenal function (ACTH stimulation test)				
ACTH (pmol/L)	43.4	-	-	<10.1
Cortisol (nmol/L)	366	368	376	-
Progesterone (nmol/L)	63.7	77.4	83.8	<1.5
17-OHP (nmol/L)	96.5	107.0	101.3	<3.0
DHEA-S (μ mol/L)	<0.5	<0.5	<0.5	<3.0
Renin (ng/mL/h)	4.20	-	-	0.97-4.18
Aldosterone (pmol/L)	927	-	-	<444
Testosterone (nmol/L)	<0.3	-	-	<0.3
Gonadal function (LHRH stimulation test)				
LH (IU/L)	<0.1	2.3	2.4	<0.5
FSH (IU/L)	0.9	6.5	8.9	0.4-3.0
Oestradiol (pmol/L)	48	-	-	22-99

* ACTH denotes adrenocorticotropin, 17-OHP 17-hydroxypregesterone, DHEA-S dehydroepiandrosterone-sulphate, LHRH luteinising hormone-releasing hormone, LH luteinising hormone, and FSH follicle-stimulating hormone

mother during pregnancy.⁶⁻⁸

Besides atypical genitalia, impaired steroidogenesis may lead to adrenal failure.⁸ Our patient went into adrenal crises with hypoglycaemia and dehydration at 4 and 5 years of age after episodes of gastroenteritis. Hence, hydrocortisone should be prescribed, especially during stress, to avoid adrenal crises.

Poor pubertal development, associated with ovarian cysts, has been reported in girls with POR deficiency.^{1,7,8} This can be explained by the deficiency of CYP19.⁸ Our patient was still in the prepubertal stage and her pubertal development should be monitored for any gonadal dysfunction.

As many other P450 enzymes are affected, patients may have other congenital abnormalities collectively referred to as ABS.⁹ This is characterised by craniofacial dysmorphism and skeletal features, most notably craniosynostosis and radiohumeral synostosis. It can occur with and without abnormal genitalia in both sexes. Antley-Bixler syndrome with abnormal external genitalia and impaired steroidogenesis is caused by POR deficiency. Such syndrome without abnormal genitalia appears to be an autosomal dominant disorder and can be caused by mutations of the *FGFR2* gene.^{6,10,11} The pathophysiology underlying the skeletal abnormalities remains unclear; it has been suggested that deficiency of CYP51 may lead to impairment of sterol biosynthesis which is linked to limb morphogenesis and development.^{1,2}

The R457H missense mutation found in our patient is a global founder¹² and severe mutation

causing the ABS-phenotype and severe decrease in both 17 α -hydroxylase and 17,20 lyase activities of P450C17.^{1,7,8,11} Some POR mutations are mild, presenting with a normal phenotype and polycystic ovarian syndrome.¹ Although P450C17 activities provide excellent genotype/phenotype correlations,^{6,11} the impact of POR mutants on different P450s has to be tested individually rather than inferred from the P450C17 assays. Recent studies have shown a differential interaction of specific POR mutations with different electron-accepting P450 enzymes.¹³ Further research into this aspect may explain the complex pathogenesis of POR deficiency.

Conclusion

P450 oxidoreductase deficiency is a rare condition with variable clinical manifestations.^{2,8,11} Affected

patients may present with ambiguous genitalia associated with impaired steroidogenesis. The elevated 17-OHP levels (mostly only mild) may lead to the diagnosis of congenital adrenal hyperplasia caused by P450C21 deficiency. Unlike P450C21 deficiency, testosterone concentrations are not elevated after birth in POR deficiency. Meanwhile, transient maternal virilisation during pregnancy may suggest an aromatase deficiency. The presence of these clinical manifestations, with or without features suggestive of ABS, should alert clinicians to a possible diagnosis of POR deficiency. Endocrine studies may show a combined P450C21 and P450C17 deficiency. Urinary steroid profiling appears to be particularly useful, because it invariably shows the combined enzymatic defect characteristic of POR deficiency.^{7,8,14} The diagnosis of POR deficiency can be confirmed by molecular analysis of the *POR* gene.

References

1. Flück CE, Tajima T, Pandey AV, et al. Mutant P450 oxidoreductase causes disordered steroidogenesis with and without Antley-Bixler syndrome. *Nat Genet* 2004;36:228-30.
2. Miller WL. P450 oxidoreductase deficiency: a new disorder of steroidogenesis with multiple clinical manifestations. *Trends Endocrinol Metab* 2004;15:311-5.
3. Yamano S, Aoyama T, McBride OW, Hardwick JP, Gelboin HV, Gonzalez FJ. Human NADPH-P450 oxidoreductase: complementary DNA cloning, sequence and vaccinia virus-mediated expression and localization of the *CYPOR* gene to chromosome 7. *Mol Pharmacol* 1989;36:83-8.
4. Hanukoglu I. Steroidogenic enzymes: structure, function, and role in regulation of steroid hormone biosynthesis. *Proceedings of the First International Symposium on A Molecular View of Steroid Biosynthesis and Metabolism, Jerusalem, Israel, 14-17 October 1991. J Steroid Biochem Mol Biol* 1992;43:779-804.
5. Wang M, Roberts DL, Paschke R, Shea TM, Masters BS, Kim JJ. Three-dimensional structure of NADPH-cytochrome P450 reductase: prototype for FMN- and FAD-containing enzymes. *Proc Natl Acad Sci USA* 1997;94:8411-6.
6. Flück CE, Miller WL. P450 oxidoreductase deficiency: a new form of congenital adrenal hyperplasia. *Curr Opin Pediatr* 2006;18:435-41.
7. Arlt W, Walker EA, Draper N, et al. Congenital adrenal hyperplasia caused by mutant P450 oxidoreductase and human androgen synthesis: analytical study. *Lancet* 2004;363:2128-35.
8. Fukami M, Horikawa R, Nagai T, et al. Cytochrome P450 oxidoreductase gene mutations and Antley-Bixler syndrome with abnormal genitalia and/or impaired steroidogenesis: molecular and clinical studies in 10 patients. *J Clin Endocrinol Metab* 2005;90:414-26.
9. Rumball KM, Pang E, Letts RM. Musculoskeletal manifestations of the Antley-Bixler syndrome. *J Pediatr Orthop B* 1999;8:139-43.
10. Chun K, Siegel-Bartelt J, Chitayat D, Phillips J, Ray PN. *FCFR2* mutation associated with clinical manifestations consistent with Antley-Bixler syndrome. *Am J Med Genet* 1998;77:219-24.
11. Huang N, Pandey AV, Agrawal V, et al. Diversity and function of mutations in p450 oxidoreductase in patients with Antley-Bixler syndrome and disordered steroidogenesis. *Am J Hum Genet* 2005;76:729-49.
12. Adachi M, Asakura Y, Matsuo M, Yamamoto T, Hanaki K, Arlt W. POR R457H is a global founder mutation causing Antley-Bixler syndrome with autosomal recessive trait. *Am J Med Genet A* 2006;140:633-5.
13. Dhir V, Ivison HE, Krone N, et al. Differential inhibition of CYP17A1 and CYP21A2 activities by the P450 oxidoreductase mutant A287P. *Mol Endocrinol* 2007;21:1958-68.
14. Fukami M, Hasegawa T, Horikawa R, et al. Cytochrome P450 oxidoreductase deficiency in three patients initially regarded as having 21-hydroxylase deficiency and/or aromatase deficiency: diagnostic value of urine steroid hormone analysis. *Pediatr Res* 2006;59:276-80.