

# Unusual traumatic triceps tendon avulsion rupture: a word of caution

Alexander PH Chan 陳伯顯  
CK Lo 盧春光  
HY Lam 林海恩  
KY Fung 馮貴游

Triceps tendon rupture is a rare condition. The usual mechanism of injury is a fall on an outstretched hand, although direct contact injuries have also been reported to cause this injury. A 67-year-old woman presented with injuries caused by direct impact to her right elbow after a fall. X-rays of the elbow demonstrated the cardinal clinical 'gap' and 'flake' signs. It is necessary to be aware of this injury and perform a careful examination at the time of the initial presentation, as the signs of this injury are usually subtle. Most reported primary repairs have been performed with non-absorbable transosseous sutures. In this case report, we show how using suture anchors for reattachment is a technically feasible alternative operative method providing a good surgical outcome.

## Introduction

Rupture of the triceps tendon is a rare injury comprising approximately 2% of all tendon injuries and less than 1% of all tendon ruptures related to the upper extremity.<sup>1,2</sup> The most common form is an avulsion from the osseous tendon insertion; intramuscular injury at the myotendinous junction occurs less often.<sup>3</sup> Few cases of this injury have been reported in the literature.<sup>4,5</sup> As a result, there is no well-established treatment protocol.

## Case report

In July 2008, a 67-year-old woman, with a 6-year history of diabetes mellitus managed with oral hypoglycaemic agents, fell on her right side, suffering a direct blow to her elbow. Prior to retirement 10 years earlier she had worked first as a farmer, then later as a manual worker. A physical examination revealed severe tenderness and swelling over her posterior right elbow. Joint movements were significantly limited and a re-examination revealed that it was not possible to extend the elbow against gravity. There was a palpable depression just proximal to the olecranon (Fig 1a). Lateral X-rays showed a small piece of avulsed osseous material from the olecranon (the 'flake' sign) [Fig 1b], which is pathognomonic for this lesion.

## Surgical technique

A primary surgical repair of the triceps tendon rupture was performed. The patient was placed in the left lateral position with an arm support (Fig 1a). A curvilinear incision was made over the posterior elbow, the rupture site was debrided and a haematoma was removed. Two GII Quickanchor Plus (DePuy Mitek, Raynham, MA, US) suture anchorages with size 2 (5 metric) green Ethibond polyester sutures were inserted over the olecranon. The triceps tendon was repaired using the Krakow method, constituting a 4-strand suture. The triceps tendon stump was positioned at the original insertion into the olecranon to restore the original excursion length of the tendon. Under X-ray guidance, suture anchor sites were made at different levels, one proximal and one distal, in order to increase the tendon-to-bone contact surface for healing (Fig 2). Care was taken not to breach the elbow joint. The repair was put under tension and the suture knots secured with the elbow in full extension. Intra-operative elbow movement was stable from 0 to 100 degrees. The total operating time was 60 minutes.

## Postoperative management

The elbow was protected by a hinge brace for 6 weeks. Isometric exercises were started 2 weeks after the operation. The patient then underwent rehabilitation with progressive active flexion, 0-30° for 2 weeks, 0-60° for 2 weeks, followed by 0-90° for the next 2 weeks. The patient's elbow had returned to the preoperative level of function by 3 months post-

### Key words

Elbow; Muscle skeletal; Rehabilitation;  
Rupture; Tendon injuries

*Hong Kong Med J 2009;15:294-6*

Department of Orthopaedics and  
Traumatology, Alice Ho Miu Ling  
Nethersole Hospital, Tai Po, Hong Kong

APH Chan, MB, BS, MRCS(Ed)

CK Lo, FHKAM (Orthopaedic Surgery)

HY Lam, FHKAM (Orthopaedic Surgery)

KY Fung, FHKAM (Orthopaedic Surgery)

Correspondence to: Dr APH Chan

E-mail: aphchan@gmail.com

surgery. The range of movement improved from being initially 10°-80° to 3°-130°, with full extension power. There were no complications.

## Discussion

The diagnosis of acute triceps tendon rupture is difficult and is easily missed when not suspected. The common differential diagnoses of elbow injuries include a sprain, radial head fracture, olecranon bursitis and fractures around the elbow joint.<sup>4</sup> In many of the reported cases of triceps tendon rupture,<sup>4,6,7</sup> the palpable defect and triceps weakness were not noted initially because of swelling, ecchymoses and pain caused by a direct fall onto the elbow. The clinical signs might be more easily detected after a fall on the outstretched hand.

The tiny avulsed flecks of bone (the 'flake' sign) are easily missed on X-rays.<sup>4</sup> The injury is therefore best managed when the clinician has a high index of suspicion and performs a careful examination at the time of injury. Radiological examinations, including ultrasonography and magnetic resonance imaging, are useful for diagnosing and assessing the extent of injury.<sup>4,6</sup>

This injury has been seen in professional football players<sup>8</sup> and weight lifters.<sup>9,10</sup> The most common mechanism of injury is a deceleration stress superimposed upon a contracted triceps muscle, with or without a concomitant blow to the posterior aspect of the elbow.<sup>11</sup> Substantial force is usually required to rupture the triceps tendon in a healthy adult, but many local and systemic diseases that alter the structural integrity of the tendon can lead to spontaneous rupture of the tendon following trivial trauma.<sup>4</sup>

Systemic causes such as chronic renal failure with secondary hyperparathyroidism, hypocalcaemic tetany, rheumatoid arthritis, osteogenesis imperfecta, anabolic steroid use, and, possibly, insulin-independent diabetes have been reported.<sup>4,12</sup> Local factors associated with triceps disruption include local steroid injections, attritional changes from degenerative arthritis, and olecranon bursitis.<sup>4</sup> These were not identified in our patient.

Acute anatomic repair of complete injuries gives predictably good results. Conservative management is usually reserved for partial injuries with little functional compromise and for those patients who are unfit for surgery.<sup>4,5</sup> Reported successful repairs of acute and complete triceps tendon ruptures include most common open transosseous suture techniques using non-absorbable sutures in the olecranon as described by Tsourvakas et al<sup>12</sup> and Levy,<sup>13</sup> K-wires reinforced with a cerclage wire,<sup>7</sup> and, rarely, bone suture anchors.<sup>14</sup> Patients undergoing operative repairs with the aforesaid methods usually recover

## 因創傷引致罕見的三頭肌肌腱撕裂

三頭肌肌腱撕裂很罕見。受傷原因往往是患者跌倒時手部伸展開，也有病例是因直接碰撞以致受傷。本文報告一名67歲女性因跌倒而撞擊右手肘引致受傷。X光照片顯示主要的臨床症狀為出現縫隙及白點斷口。由於病徵不明顯，須要知悉這種病及在初步診斷時仔細觀察。文獻記載一般基本醫治方法為使用不可吸收線進行經骨縫合術。本文討論使用釘入錨釘法作縫合術是一種技術上可行的手術，並有良好的手術預後。

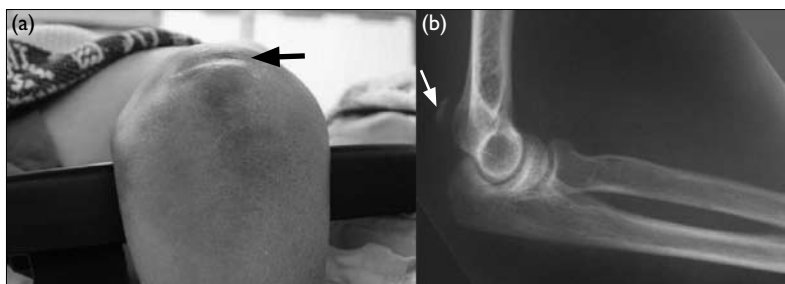


FIG 1. (a) Preoperative photograph shows the 'gap' sign just proximal to the olecranon at the insertion of triceps tendon (black arrow). (b) Lateral radiograph of the injured elbow showing the 'flake' fracture avulsed from the olecranon (white arrow)

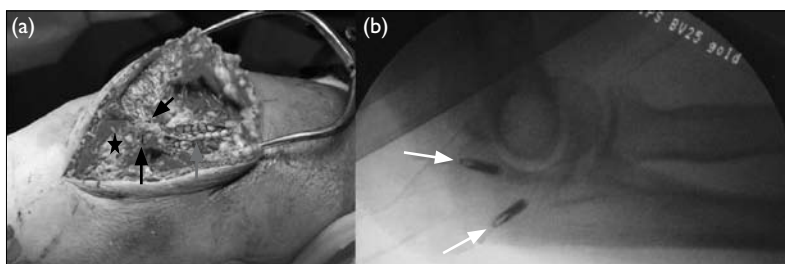


FIG 2. (a) Intra-operative photograph: the triceps tendon (grey arrow) detached from the olecranon distally (black star), was reattached back to the bone using two suture anchors (black arrows) proximally. (b) Intra-operative X-ray screening shows the suture anchors (white arrows) well inserted into the olecranon without breaching the intra-articular surface

with good function after a period of immobilisation followed by active strengthening exercise. We used suture anchorage for reinsertion of the tendon because this method can shorten the surgical time and provide solid fixation, enabling faster rehabilitation. When compared with the use of conventional 2-strand transosseous sutures, our method can provide extra suture strength by using 4 strands and provides more contact surface for tendon-to-bone healing.

van Riet et al<sup>4</sup> have reported good outcomes in 13 primary repairs of triceps tendon rupture. Where a patient has presented late with a triceps tendon rupture with considerable local tissue loss, surgical options include a wide variety of

graft reconstructions, such as use of the palmaris longus and Achilles tendons, an Anconeus slide, or even a semitendinosus or latissimus dorsi flap.<sup>4</sup> Augmentation using an artificial polyester mesh has also been reported as a means of repairing an old rupture.<sup>15</sup>

## Conclusion

Avulsion of the triceps tendon is a rare injury. It can

occur after direct or indirect trauma and usually occurs at the osseo-tendinous junction. A high index of suspicion, physical examination seeking a palpable gap, and search for a 'flake' fracture on lateral radiographs will help make the diagnosis. Early recognition of these injuries and prompt intervention are the cornerstones of a successful outcome. Surgical repair of complete ruptures generally produces good functional results. We recommend a primary repair using bone suture anchors.

## References

1. Anzel SH, Convey KW, Weiner AD, Lipscomb PR. Disruption of muscles and tendons; an analysis of 1,014 cases. *Surgery* 1959;45:406-14.
2. McMaster PE. Tendon and muscle ruptures. Clinical and experimental studies on the causes and location of subcutaneous ruptures. *J Bone Joint Surg Am* 1933;15:705-22.
3. Aso K, Torisu T. Muscle belly tear of the triceps. *Am J Sports Med* 1984;12:485-7.
4. van Riet RP, Morrey BF, Ho E, O'Driscoll SW. Surgical treatment of distal triceps ruptures. *J Bone Joint Surg Am* 2003;85-A:1961-7.
5. Vidal AF, Drakos MC, Allen AA. Biceps tendon and triceps tendon injuries. *Clin Sports Med* 2004;23:707-22, xi.
6. Sharma SC, Singh R, Goel T, Singh H. Missed diagnosis of triceps tendon rupture: a case report and review of literature. *J Orthop Surg (Hong Kong)* 2005;13:307-9.
7. Rajasekhar C, Kakarlapudi TK, Bhamra MS. Avulsion of the triceps tendon. *Emerg Med J* 2002;19:271-2.
8. Mair SD, Isbell WM, Gill TJ, Schlegel TF, Hawkins RJ. Triceps tendon ruptures in professional football players. *Am J Sports Med* 2004;32:431-4.
9. Harris PC, Atkinson D, Moorehead JD. Bilateral partial rupture of triceps tendon: case report and quantitative assessment of recovery. *Am J Sports Med* 2004;32:787-92.
10. Sollender JL, Rayan GM, Barden GA. Triceps tendon rupture in weight lifters. *J Shoulder Elbow Surg* 1998;7:151-3.
11. Farrar EL 3rd, Lippert FG 3rd. Avulsion of the triceps tendon. *Clin Orthop Relat Res* 1981;(161):242-6.
12. Tsourvakas S, Gouvalas K, Gimtsas C, Tsianias N, Founta P, Ameridis N. Bilateral and simultaneous rupture of the triceps tendons in chronic renal failure and secondary hyperparathyroidism. *Arch Orthop Trauma Surg* 2004;124:278-80.
13. Levy M. Repair of triceps tendon avulsions or ruptures. *J Bone Joint Surg Br* 1987;69:115.
14. Pina A, Garcia I, Sabater M. Traumatic avulsion of the triceps brachii. *J Orthop Trauma* 2002;16:273-6.
15. Sai S, Fujii K, Chino H, Inoue J, Ishizaka J. Old rupture of the triceps tendon with unique pathology: a case report. *J Orthop Sci* 2004;9:654-6.