

# A rare cause of nephrotic syndrome: lipoprotein glomerulopathy

CY Cheung 張志遠  
Angel OK Chan 陳安琪  
YH Chan 陳耀恆  
KC Lee 李景中  
Gordon PT Chan 陳百濤  
Gene TC Lau 劉子展  
CC Shek 石志忠  
KF Chau 周嘉歡  
CS Li 李俊生

Lipoprotein glomerulopathy is a rare kidney disease in which lipoprotein thrombi are seen in the glomerular capillaries. Most of these patients are found in Japan and East Asian countries. The presenting symptoms include proteinuria, an abnormal plasma lipoprotein profile that resembles type III hyperlipoproteinaemia, and a marked increase in serum apolipoprotein E concentration. Previous studies have suggested that lipoprotein glomerulopathy might be related to *APOE* gene mutation. No effective therapeutic regimen has been established for lipoprotein glomerulopathy. We report the first case of biopsy-proven lipoprotein glomerulopathy in Hong Kong in a patient who presented with nephrotic syndrome and dyslipidaemia. DNA analysis revealed apolipoprotein E Kyoto together with a novel apolipoprotein E mutation, apolipoprotein E (Asp230Tyr) Hong Kong. There was significant improvement in the clinical parameters and resolution of symptoms after the introduction of statins. Further studies will be needed to clarify the role of apolipoprotein E Hong Kong and its interaction with apolipoprotein E Kyoto in the pathogenesis of lipoprotein glomerulopathy.

## Introduction

Lipoprotein glomerulopathy (LPG) is a rare kidney disease, characterised by lipoprotein thrombi in the glomeruli, an abnormal plasma lipoprotein profile that resembles type III hyperlipoproteinaemia, and a marked increase in serum apolipoprotein E (apoE) concentration. Since first described by Saito et al in 1989,<sup>1</sup> it has been reported in approximately 65 patients, most of them in Japan and other East Asian countries. Very few cases have been reported in the United States and Europe.<sup>2,3</sup>

Human apoE mediates tissue uptake of triglyceride-rich lipoproteins through both the low-density lipoprotein (LDL) receptor and the LDL-receptor-related protein pathways. Genetic variations at the apoE gene locus code for three different major isoforms designated E2, E3, and E4. The wild-type allele is apoE3, while apoE2 (Arg158Cys) and apoE4 (Cys112Arg) are less common. Lipoprotein glomerulopathy was subsequently found to be due to several mutations of the *APOE* gene.<sup>2</sup>

There have been no controlled studies examining different therapeutic approaches for LPG. Only case reports have discussed the efficacy of various agents. We report the first case of biopsy-proven LPG in Hong Kong with a novel apoE mutation.

### Key words

Apolipoproteins E; DNA mutational analysis; Hyperlipoproteinemias; Kidney glomerulus; Lipoproteins

*Hong Kong Med J* 2009;15:57-60

## Case report

A 35-year-old Chinese man was referred to our unit for evaluation of proteinuria in May 2007. He had enjoyed good past health but developed ankle swelling and frothy urine in April 2007. He had no family history of renal disease and had not taken any herbs or non-steroidal anti-inflammatory drugs recently.

On examination he was found to have proteinuria, hypertension, and dyslipidaemia. His body weight was 76 kg and blood pressure was 148/90 mm Hg. Urinalysis found proteinuria (4+) and microscopic haematuria (trace). He had neither xanthoma nor any corneal arcus. There was mild ankle oedema. Laboratory investigations showed: haemoglobin 150 g/L, white cell count  $6.3 \times 10^9$ /L, platelet count  $210 \times 10^9$ /L, erythrocyte sedimentation rate 23 mm/h, serum potassium 4.4 mmol/L, urea 4.9 mmol/L, creatinine 72  $\mu$ mol/L, and albumin 23 g/L. The liver enzymes, C3 and C4, were normal. The autoimmune markers, including rheumatoid factor and anti-nuclear antibody, were negative. His total cholesterol (TC) level was 9.3 mmol/L and triglyceride (TG) level was 4.7 mmol/L. The 24-hour urine total protein (UTP) was 5.3 g/day. An ultrasound revealed normal-sized kidneys.

## Pathological findings

An ultrasound-guided percutaneous renal biopsy was performed and two cores of renal

Queen Elizabeth Hospital, 30 Gascoigne Road, Kowloon, Hong Kong;  
Department of Medicine

CY Cheung, FHKCP, FHKAM (Medicine)

YH Chan, FHKCP, FHKAM (Medicine)

KF Chau, FHKCP, FHKAM (Medicine)

CS Li, FRCP, FHKAM (Medicine)

Department of Pathology

AOK Chan, MB, ChB, FHKCPATH

KC Lee, MB, BS, FHKCPATH

GTC Lau, MPhil

CC Shek, MB, BS, FRCPATH

Department of Pathology, Alice Ho Miu

Ling Nethersole Hospital, Tai Po, Hong

Kong

GPT Chan, MB, BS, FHKCPATH

Correspondence to: Dr CY Cheung  
E-mail: simoncycheung@gmail.com

## 腎病症候群的一個罕見成因： 脂蛋白腎小球病

脂蛋白腎小球病是一種罕見腎病，脂蛋白血栓見於腎小球毛細血管內。大部份個案都發生在日本及東亞國家。病徵包括蛋白尿、好像高乳糜粒血症III型的異常血漿脂蛋白，以及血清載脂蛋白E水平明顯增加。過往的研究顯示脂蛋白腎小球病可能與APOE基因突變有關，暫時沒有一個有效的治療方法。我們報告香港首宗腎活檢證實的脂蛋白腎小球病，患者有腎病症候群和血脂異常。DNA分析發現載脂蛋白E京都型和載脂蛋白E (Asp230Tyr) 香港型（一種新的載脂蛋白E突變）。施以他汀類藥物後，病人的臨床數據有好轉，症狀也得到緩解。有須要進行更多研究，確定載脂蛋白E香港型與載脂蛋白E京都型在引發脂蛋白腎小球病中的角色。

tissue were obtained. There were 26 glomeruli in the biopsy, three of which were completely sclerotic. The remaining 23 showed distended glomerular capillaries, complex remodelling of glomerular capillary walls and mesangiolysis. The distended capillaries contained slightly basophilic stringy acellular material that showed very pale staining on periodic acid-Schiff, periodic acid-silver methenamine, and trichrome staining compatible with lipoprotein thrombi. Five of these 23 glomeruli also featured segmental sclerosis with frequent hyalinosis and rare adhesions. There were scattered foci of mild tubular atrophy, interstitial fibrosis, and mild interstitial infiltrate in the vicinity of completely sclerotic glomeruli. Hyaline arteriosclerosis was found in some arterioles. The interlobular arteries were unremarkable. A direct immunofluorescence study showed an incidental finding of mesangial immunoglobulin A (IgA) deposit. There were fairly extensive fibrin deposits in the capillary wall and mesangium as well. C3 and IgM were noted in sclerotic segments. Stains for IgG and C1q were negative. The lipoprotein thrombi were Oil-Red-O positive. Ultrastructurally, they showed a fine granular concentric laminated appearance mixed with minute empty vacuoles. The histological diagnosis was LPG with a minor component of IgA nephropathy (Fig 1). Both the complex remodelling of the capillary basement membrane and the presence of focal segmental glomerulosclerosis could have contributed to the development of severe proteinuria. The IgA nephropathy was treated as an incidental finding as the morphological pattern was typical of LPG.

### Mutational analyses of the APOE gene

The patient gave an informed, written consent for genetic testing. His family members were in mainland China so were unavailable for the study. Genomic DNA was extracted from peripheral whole blood using a QIAamp DNA blood kit according to

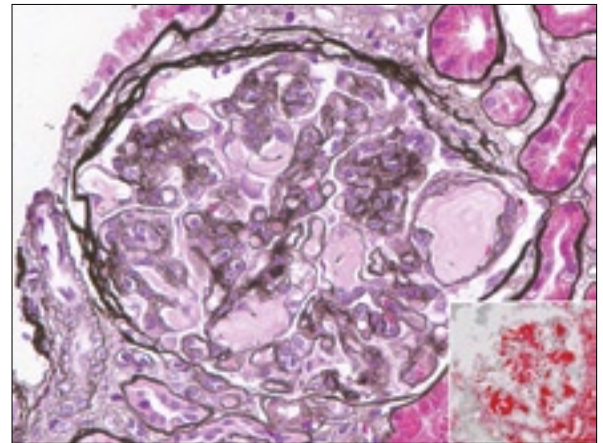


FIG 1. Stereotypical appearance of glomeruli in lipoprotein glomerulopathy with lipoprotein thrombi, complex remodelling of capillary walls and mesangiolysis (periodic acid-silver methenamine stain)

Inset showing positive Oil-Red-O staining in the lipoprotein thrombi

the manufacturer's instructions (Qiagen, Hilden, Germany). Exons 2 to 4 and the flanking introns of the APOE gene were amplified using polymerase chain reaction followed by direct DNA sequencing. The patient was found to have the apoE3/E3 genotype. He was also heterozygous for the Kyoto mutation Arg25Cys. In addition, a heterozygous novel missense mutation was identified with a base substitution 688G>T, changing GAC to TAC, leading to the substitution of aspartic acid at residue 230 with tyrosine, ie D230Y (Fig 2). This base change was not found in the APOE genes of 50 healthy control subjects who underwent restriction enzyme analysis using RsaI, suggesting that D230Y is a mutation rather than polymorphism.

### Clinical course

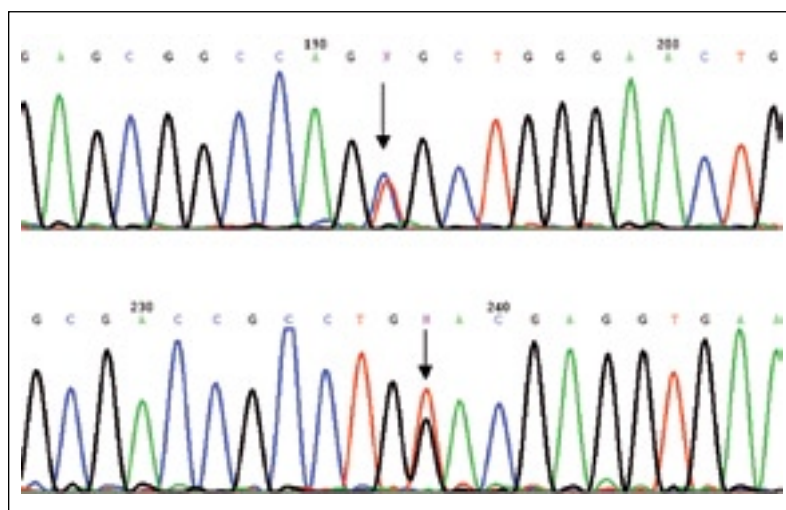
The patient was treated with simvastatin 20 mg and valsartan 40 mg daily. There was marked improvement in his lipoprotein profile and levels of proteinuria after 6 weeks of treatment: his TC was 3.5 mmol/L, LDL cholesterol was 1.2 mmol/L, high-density lipoprotein cholesterol was 0.9 mmol/L, and TG was 3.0 mmol/L. The 24-hour UTP was 1.4 g/day and his serum albumin and creatinine were 42 g/L and 70 µmol/L respectively. Six months later, his UTP further decreased to 0.8 g/day. His TC was 3.2 mmol/L, LDL cholesterol was 1.2 mmol/L, high-density lipoprotein cholesterol was 1.1 mmol/L, and his TG was 1.5 mmol/L.

### Discussion

We have described a patient who presented with nephrotic syndrome, a clinical feature commonly

encountered in nephrology. Nephrotic syndrome may occur in association with a wide variety of primary and systemic diseases. Minimal change disease is the predominant cause in children. In adults, approximately 30% have a systemic disease such as diabetes mellitus, systemic lupus erythematosus, or amyloidosis; the remaining cases are usually due to primary renal disorders such as minimal change disease, focal segmental glomerulosclerosis, and membranous nephropathy. In most cases, a renal biopsy is required to establish the diagnosis.

Our patient is the first case of biopsy-proven LPG in Hong Kong. Although a component of IgA nephropathy was also found, its contribution to the symptoms in our patient is difficult to judge. There is still no effective treatment for IgA nephropathy. The dramatic resolution of symptoms and proteinuria after the introduction of simvastatin and valsartan suggests IgA nephropathy is unlikely to have made any significant contribution to the symptomatology in our patient. Lipoprotein glomerulopathy has no specific biochemical markers and the apoE concentration can be highly variable.<sup>3,4</sup> Moreover, an apoE quantitation service was not available in Hong Kong. As a result, a renal biopsy demonstrating the presence of lipoprotein thrombi was essential for making the diagnosis. Once a histopathological diagnosis of LPG has been made, analysis of the *APOE* gene can be performed to seek mutations. At present, several apoE mutations, including apoE Sendai (Arg145Pro),<sup>5</sup> apoE Kyoto (Arg25Cys),<sup>6</sup> apoE Tokyo (Leu141 to Lys 143del),<sup>7</sup> apoE1 (Gln156-Gly173→0),<sup>8</sup> apoE Chicago (Arg147Pro),<sup>9</sup> apoE Okayama (Arg150Gly),<sup>10</sup> and apoE Tsukuba (Arg114Cys)<sup>4</sup> have been discovered in patients with LPG. The Kyoto mutation, first seen in Japanese patients, has recently been reported in European Americans.<sup>11</sup> In both populations, carriers of this mutation may be asymptomatic. It would, therefore, be interesting to study the genotype-phenotype correlation in our patient's family members but, unfortunately, they were not available for biochemical and genetic studies. It has been postulated that the Kyoto mutation reduces the clearance of apoE from the circulation and that a "second hit" is required for LPG to develop.<sup>6,11</sup> In our patient, the Kyoto mutation together with the novel mutation Asp230Tyr of the *APOE* gene we identified, named 'apoE Hong Kong' after our city, may have a cumulative effect and result in phenotypic expression as LPG. In patients with LPG, most apoE mutations are found around the LDL-receptor-binding domain and they show type III hyperlipoproteinaemia in their lipoprotein profile. In some apoE mutations causing LPG, such as apoE Kyoto and apoE Hong Kong, as in our patient, the mutation sites are beyond the receptor-binding site. This means that these mutations are not involved in the mechanisms of familial type III hyperlipoproteinaemia with its marked hypertriglyceridaemia and systemic



**FIG 2. Electropherograms of exons 3 and 4 of the *APOE* gene**  
The upper panel shows the mutation 73C>T, or Arg25Cys in the sense direction. The lower panel shows the heterozygous Asp230Tyr mutation in the sense direction. The mutation sites are indicated by arrows and denoted by the letter N

lipidosis, but are directly injurious to the glomeruli. In fact, apoE Kyoto shows increased binding capacity to endothelial cells.<sup>12</sup> Despite the variety of mutation sites, the crucial transformation in the apoE molecule may form similar aggregated deposits of lipoproteins with high affinity for, or low clearance in, glomeruli.

Chen et al<sup>3</sup> found that Chinese LPG patients may have different clinical and pathological features from the population described by Saito et al.<sup>2</sup> In the largest published series of Chinese patients with biopsy-proven LPG,<sup>13</sup> the apoE level was significantly lower than that in the patients reported by Saito et al,<sup>2</sup> and none of the Chinese patients with LPG had mutant forms of apoE. They postulated that other factors might be involved in the pathogenesis of LPG. A recent study on a Chinese family, however, revealed the presence of apoE Guangzhou (Arg 150 Pro) in four LPG patients and one asymptomatic family member.<sup>14</sup>

There have been no randomised, controlled studies examining the different therapeutic approaches for LPG. The efficacy of different therapeutic agents has only been discussed in case reports. The efficacy of lipid-lowering agents is controversial because they do not seem to decrease urinary protein excretion, despite achieving optimal lipid levels. Recent case reports have shown that intensive therapy with lipid-lowering agents, including fibrates, resulted in clinical remission with histological resolution.<sup>15</sup> The effects of statins remain controversial. In our patient, statins were used from the beginning and there was a significant improvement in both his lipid profile and proteinuria levels. Currently there is no evidence that angiotensin

converting enzyme inhibitors (ACEI) and/or angiotensin II receptor blockers (ARB) are effective in LPG. Nevertheless, considering their effectiveness in other forms of proteinuric chronic kidney disease, it is still reasonable to use ACEI or ARB both for blood pressure control and to slow progression of the renal disease in those with persistent proteinuria.

In conclusion, we have described a novel apoE mutation, apoE (Asp230Tyr) Hong Kong, together with apoE Kyoto in a Chinese patient with biopsy-proven LPG. Further investigation is needed to clarify the mechanism by which apoE deposition in glomerular capillaries is induced by the interaction between apoE Hong Kong and apoE Kyoto.

## References

1. Saito T, Sato H, Kudo K, et al. Lipoprotein glomerulopathy: glomerular lipoprotein thrombi in a patient with hyperlipoproteinemia. *Am J Kidney Dis* 1989;13:148-53.
2. Saito T, Matsunaga A, Oikawa S. Impact of lipoprotein glomerulopathy on the relationship between lipids and renal diseases. *Am J Kidney Dis* 2006;47:199-211.
3. Chen HP, Liu ZH, Gong RJ, et al. Lipoprotein glomerulopathy: clinical features and pathological characteristics in Chinese. *Chin Med J (Engl)* 2004;117:1513-7.
4. Hagiwara M, Yamagata K, Matsunaga T, et al. A novel apolipoprotein E mutation, ApoE Tsukuba (Arg 114 Cys), in lipoprotein glomerulopathy. *Nephrol Dial Transplant* 2008;23:381-4.
5. Oikawa S, Matsunaga A, Saito T, et al. Apolipoprotein E Sendai (arginine 145→proline): a new variant associated with lipoprotein glomerulopathy. *J Am Soc Nephrol* 1997;8:820-3.
6. Matsunaga A, Sasaki J, Komatsu T, et al. A novel apolipoprotein E mutation, E2 (Arg25Cys), in lipoprotein glomerulopathy. *Kidney Int* 1999;56:421-7.
7. Konishi K, Saruta T, Kuramochi S, et al. Association of a novel 3-amino acid deletion mutation of apolipoprotein E (Apo E Tokyo) with lipoprotein glomerulopathy. *Nephron* 1999;83:214-8.
8. Ando M, Sasaki J, Hua H, et al. A novel 18-amino acid deletion in apolipoprotein E associated with lipoprotein glomerulopathy. *Kidney Int* 1999;56:1317-23.
9. Sam R, Wu H, Yue L, et al. Lipoprotein glomerulopathy: a new apolipoprotein E mutation with enhanced glomerular binding. *Am J Kidney Dis* 2006;47:539-48.
10. Kinomura M, Sugiyama H, Saito T, et al. A novel variant apolipoprotein E Okayama in a patient with lipoprotein glomerulopathy. *Nephrol Dial Transplant* 2008;23:751-6.
11. Rovin BH, Roncone D, McKinley A, Nadasdy T, Korbet SM, Schwartz MM. APOE Kyoto mutation in European Americans with lipoprotein glomerulopathy. *N Engl J Med* 2007;357:2522-4.
12. Murano T, Matsumura R, Misawa Y, et al. Interaction of endothelial cells and triglyceride-rich lipoproteins with apolipoprotein E (Arg→Cys) from a patient with lipoprotein glomerulopathy. *Metabolism* 2002;51:201-5.
13. Zhang B, Liu ZH, Zeng CH, Zheng JM, Chen HP, Li LS. Clinicopathological and genetic characteristics in Chinese patients with lipoprotein glomerulopathy. *J Nephrol* 2008;21:110-7.
14. Luo B, Huang F, Liu Q, et al. Identification of apolipoprotein E Guangzhou (arginine 150 proline), a new variant associated with lipoprotein glomerulopathy. *Am J Nephrol* 2008;28:347-53.
15. Arai T, Yamashita S, Yamane M, et al. Disappearance of intraglomerular lipoprotein thrombi and marked improvement of nephrotic syndrome by bezafibrate treatment in a patient with lipoprotein glomerulopathy. *Atherosclerosis* 2003;169:293-9.