

## Cerebral venous thrombosis presenting as subarachnoid haemorrhage

A 34-year-old man, with good past health, presented with a 3-day history of a mild headache developing gradually over 3 days, followed by a generalised seizure leading to posterior dislocation of his right shoulder. He had another seizure just before attending the accident and emergency department of a regional public hospital. Cerebral computed tomography showed a subarachnoid haemorrhage over the right fronto-parietal sulci (Fig 1). The basal cisterns were preserved. Digital subtraction angiography failed to demonstrate the superior sagittal sinus (Fig 2). There was no cerebral aneurysm, cerebral arteriovenous malformation, nor dural arteriovenous fistula. Magnetic resonance imaging (MRI) showed obliteration of the superior sagittal sinus with hyperintensity in T1 and FLAIR (fluid-attenuated inversion recovery) images (Fig 3). No vascular abnormality was identified. He was treated first with intravenous heparin, then warfarin, and anticonvulsants. Immunological screening tests including those for anti-dsDNA, anti-neutrophilic cytoplasmic antibodies, antinuclear antibodies, anti-cardiolipin, anti-mitochondrial antibodies, and anti-smooth muscle antibodies were all negative. After 3 months of anticoagulant therapy, MRI demonstrated partial recanalisation of the superior sagittal sinus. Blood tests for protein C, protein S and anti-thrombin III deficiency performed on completion of a 6-month course of anticoagulants were all negative.

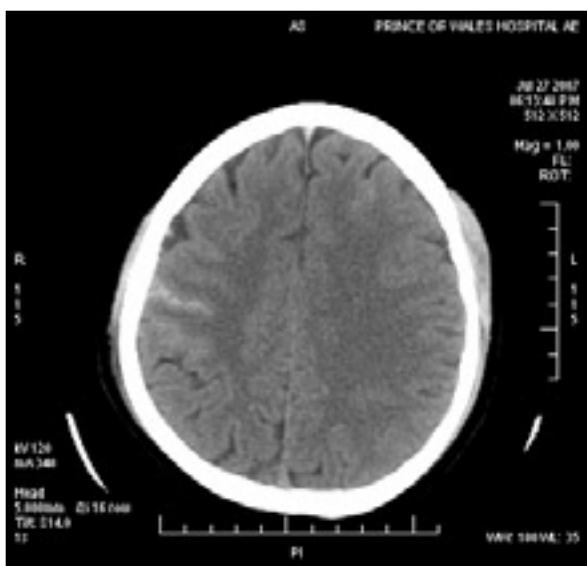


FIG 1. Computed tomography of the brain showing the convexity subarachnoid haemorrhage

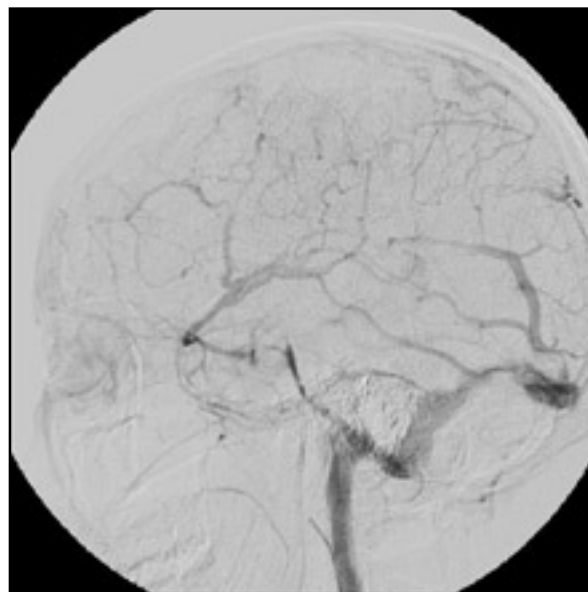


FIG 2. Digital subtraction angiography showing that the superior sagittal sinus was not opacified

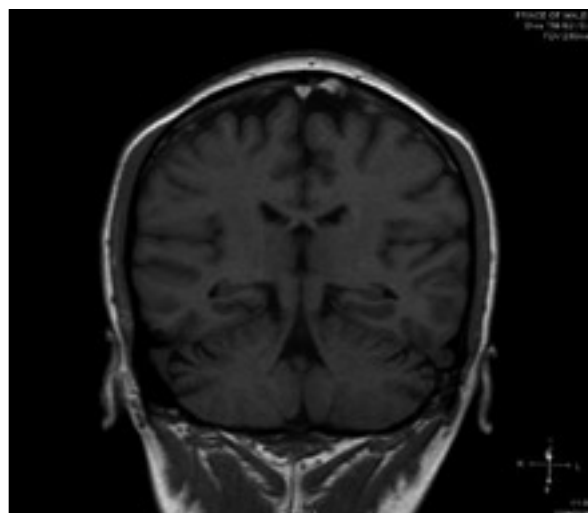


FIG 3. Magnetic resonance imaging (T1-weighted) showing hyperintensity in the superior sagittal sinus, signifying the subacute blood clot

### Discussion

Patients with cerebral venous thrombosis present with a wide spectrum of symptoms and signs.<sup>1-3</sup> Headache is the commonest presentation and though it is usually one of gradual onset, it can also

be sudden (reported in more than 10% of patients). Other presentations include focal deficits and impairment of consciousness. Forty percent of patients with a cerebral venous thrombosis can present with seizures. Making the diagnosis can be more difficult when the patient presents with a subarachnoid haemorrhage because it is rare for a subarachnoid haemorrhage to be associated with a cerebral venous thrombosis.<sup>4,5</sup> Nonetheless, the distribution of a subarachnoid haemorrhage from a superior sagittal sinus thrombosis is usually different from that of one with an arterial origin and has a characteristic pattern. The haemorrhage is usually limited to the sulci of the cerebral convexity, sparing the basal cisterns.<sup>4</sup>

The exact cause of subarachnoid haemorrhage in patients with cerebral venous thromboses remains unknown. It is postulated that the superior sagittal sinus thrombosis causes dilatation of the venous system and venous hypertension, leading to the dilatation, reversed blood flow and subsequent rupture of the adjacent fragile, thin-walled, valveless cortical veins of the involved sinus. This leads to the haemorrhage entering the subarachnoid space, resulting in evidence of a subarachnoid haemorrhage as seen in the computed tomographic scan of our

patient. Another postulation is that the superior sagittal sinus thrombosis causes a venous haemorrhagic infarct in which the blood enters the subarachnoid space. Nevertheless, the capacitance of the cortical veins explains why subarachnoid haemorrhage is an uncommon occurrence in patients with cerebral venous thromboses. Our case demonstrates that subarachnoid haemorrhage can be a presentation of cerebral venous thrombosis, and investigation of a possible cerebral venous thrombosis is thus advised in patients with spontaneous convexity subarachnoid haemorrhages.

**Nelson KL Lai**, MRCS (Ed)

**Joyce WY Hui**, FRCR

**George KC Wong**, FRCSEd (SN)

E-mail: georgewong@surgery.cuhk.edu.hk

**Simon CH Yu**, MD, FRCR

**David TF Sun**, FRCSEd (SN)

**WS Poon**, FRCS

Division of Neurosurgery

Prince of Wales Hospital

The Chinese University of Hong Kong

Shatin

Hong Kong

## References

1. Stam J. Thrombosis of the cerebral veins and sinuses. *N Engl J Med* 2005;352:1791-8.
2. Boussier MG, Ferro JM. Cerebral venous thrombosis: an update. *Lancet Neurol* 2007;6:162-70.
3. de Bruijn SF, Stam J, Kappelle LJ. Thunderclap headache as first symptom of cerebral venous sinus thrombosis: CVST Study Group. *Lancet* 1996;348:1623-5.
4. Oppenheim C, Domigo V, Gauvrit JY, et al. Subarachnoid hemorrhage as the initial presentation of dural sinus thrombosis. *AJNR Am J Neuroradiol* 2005;26:614-7.
5. Sztajzel R, Coeytaux A, Dehdashti AR, Delavelle J, Sinnreich M. Subarachnoid hemorrhage: a rare presentation of cerebral venous thrombosis. *Headache* 2001;41:889-92.