

Persistent sciatic artery complicated by aneurysm formation and thrombosis

HS Fung 馮漢盛
S Lau 柳洵
MK Chan 陳文光
KW Tang 鄧國穎
YL Cheung 張毓靈
Susan CH Chan 陳慈欽

A persistent sciatic artery is a rare embryological anomaly. We report a case of a persistent sciatic artery with aneurysm formation and thrombosis in a patient with rheumatoid arthritis/systemic lupus erythematosus overlap syndrome and Raynaud's phenomenon. The diagnosis and complete, accurate evaluation of the arterial anatomy of the lower limb were achieved using computed tomographic angiography.

Introduction

Persistent sciatic artery is a rare congenital anomaly occurring in approximately 0.05% of the population, based on angiographic studies.¹ The first description of a persistent sciatic artery was published by Green in the *Lancet* in 1832²; the first account of an aneurysm of this vessel, the rupture of which resulted in the patient's death, was reported by Fagge in 1864.³ A persistent sciatic artery is susceptible to atherosclerotic degeneration, resulting in aneurysmal dilatation, occlusive thrombosis, or thromboembolisation.

Case report

A 53-year-old woman with rheumatoid arthritis/systemic lupus erythematosus overlap syndrome and Raynaud's phenomenon, presented with an ischaemic ulcer on her right big toe. A physical examination found a palpable right femoral pulse but absent popliteal and posterior tibial pulses.

Computed tomographic (CT) angiography of the lower limbs was performed from the lower abdominal aorta to the feet, using a 64-slice multi-detector CT machine. The images showed a persistent posterior circulation arising from the right internal iliac artery in the right lower extremity and running inferiorly along the course of the sciatic nerve, consistent with a persistent sciatic artery. The right persistent sciatic artery continued inferiorly and gave rise to the right popliteal artery. There was a focal fusiform dilatation in the gluteal region suggestive of aneurysm formation. Absence of contrast enhancement of the right persistent sciatic artery and the aneurysm was suggestive of thrombosis (Fig 1). The right common and profunda femoral arteries were normal. The right superficial femoral artery was small in calibre and hypoplastic (Fig 2), coursing medially, tapering and bifurcated close to the level of the adductor canal. The right popliteal artery patency was maintained by collaterals from the right superficial femoral artery. The right lower limb trifurcation arteries were patent. The major arterial branches of the left lower limb were unremarkable with no evidence of a persistent sciatic artery on the left side (Fig 1).

The right lower limb ischaemia could be explained by the decrease in blood supply caused by the dual system (superficial femoral artery and persistent sciatic artery) secondary to thrombosis of the right persistent sciatic artery and aneurysm, further aggravated by Raynaud's phenomenon.

The ankle brachial index was 0.53 on the right side and 1.06 on the left side. A ligation of the persistent sciatic artery with a femoro-popliteal bypass to enable revascularisation was initially planned but during the preoperative assessment she was found to have atrial fibrillation. She was therefore put on warfarin and the surgery postponed. On subsequent follow-up, her big toe ulcer was found to have improved so the surgery was not considered necessary and she was maintained on warfarin.

Discussion

The sciatic artery is the axial artery of the lower limb and provides the blood supply during early stages of embryonic development. It normally regresses to form the proximal part of the inferior gluteal artery after the third month of embryonic life following the development of the femoral artery from the external iliac artery.⁴ Cases of persistent sciatic

Key words

Aneurysm; Angiography; Femoral artery;
Iliac artery; Popliteal artery

Hong Kong Med J 2008;14:492-4

Department of Radiology and Imaging,
Queen Elizabeth Hospital, 30 Gascoigne
Road, Hong Kong

HS Fung, MB, ChB, FRCR

S Lau, FRCR, FHKAM (Radiology)

MK Chan, FRCR, FHKAM (Radiology)

KW Tang, FRCR, FHKAM (Radiology)

YL Cheung, FRCR, FHKAM (Radiology)

SCH Chan, FRCR, FHKAM (Radiology)

Correspondence to: Dr HS Fung
E-mail: dicksonfunghs@gmail.com

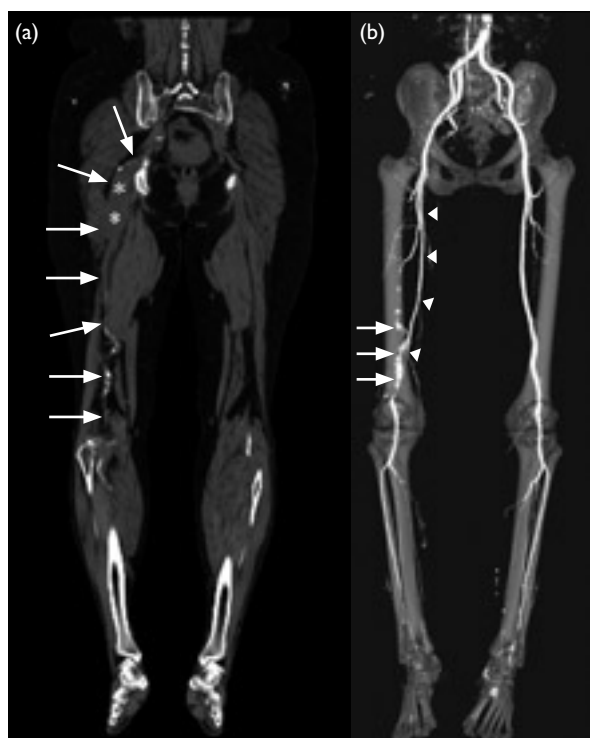

FIG 1. Computed tomographic angiography

(a) A coronal reformatted image showing the right persistent sciatic artery running along the course of the sciatic nerve and giving rise to the popliteal artery (white arrows). Atherosclerotic changes with intra-luminal calcifications are seen distally. A fusiform aneurysm (white *) was noted in the gluteal region. Absence of contrast enhancement was suggestive of thrombosis (b) A volume-rendered technique showing atherosclerotic changes in the distal right persistent sciatic artery (white arrows). The right persistent sciatic artery and aneurysm were not shown clearly due to thrombosis. The right superficial femoral artery (white arrowheads) was hypoplastic compared with the left side

artery are classified as complete or incomplete.⁵ In the incomplete type, the persistent sciatic artery is hypoplastic and the superficial femoral artery is the main blood supply for the lower limb. In the complete type, the persistent sciatic artery continues to the popliteal artery with little change in size and becomes the dominant supply for the lower limb while the superficial femoral artery is hypoplastic and provides only collaterals to the lower limb. Thus, our patient had the complete form of persistent sciatic artery.

Patients with persistent sciatic arteries may present with a pulsatile gluteal mass which may be painful, especially in the sitting position. Aneurysm formation occurs in approximately 46% of cases. The high incidence of aneurysm formation is probably related to repeated external trauma as the persistent sciatic artery is in a relatively vulnerable anatomic position.⁶ Other aetiological factors include atherosclerosis, hypertension, congenital lack of arterial elastic tissue, and infection.⁷ Other symptoms

持續性坐動脈併發動脈瘤及血栓的形成

持續性坐動脈是一種罕見的胚胎異常病。本文報告一名患有風濕性關節炎、系統性紅斑狼瘡、及雷諾現象的病人，出現持續性坐動脈併發動脈瘤及血栓的形成。使用電腦斷層血管攝影術成功作出診斷及為病人下肢作完整而準確的動脈解剖。

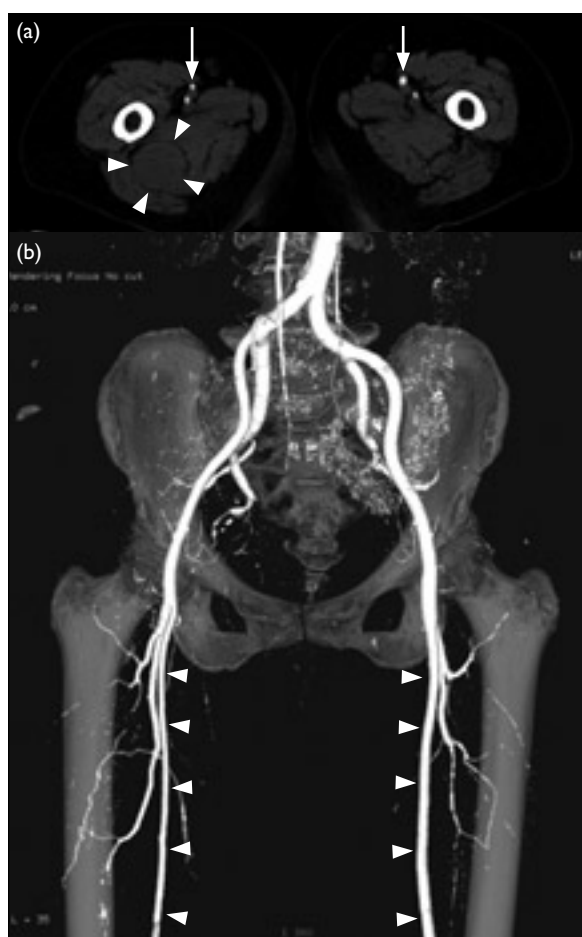


FIG 2. Computed tomographic angiography

(a) An axial image at gluteal and upper thigh level showing a thrombosed aneurysm of a right persistent sciatic artery (white arrowheads). The right superficial femoral artery was hypoplastic with a smaller calibre than the left superficial femoral artery (white arrows) (b) Thigh region showing a hypoplastic right superficial femoral artery in comparison to the left side (white arrowheads)

associated with a persistent sciatic artery aneurysm include sciatic neuropathy caused by sciatic nerve compression, and lower limb ischaemia caused by thrombosis or distal embolisation.^{3,8}

Before the development of CT angiography, conventional angiography was the primary imaging technique used to diagnose a persistent sciatic artery. The characteristic angiographic findings include

an enlargement of the internal iliac artery and/or a hypoplastic superficial femoral artery terminating as small branches in the distal thigh.⁹ It is often difficult, however, to visualise the popliteal and tibial vessels using conventional angiography and this can lead to the erroneous impression that occlusion is present. Failure to visualise the popliteal and tibial vessels can be related to slow flow in the dilated artery or failure to place the catheter tip proximal to the internal iliac orifice.¹⁰⁻¹²

Advances in multi-detector CT technology have given CT an increasing role in establishing the diagnosis of a persistent sciatic artery and clarifying its relationship to the surrounding nerves, vessels, and musculoskeletal structures, which aids surgical planning.^{13,14} Computed tomographic angiography can reveal aneurysm formation, the degree of intraluminal thrombosis, and associated venous anomalies. It can also demonstrate a totally occluded artery that cannot be seen on conventional angiography.

An asymptomatic persistent sciatic artery does not require operative management. It should, however, be monitored due to the high risk of thromboembolic complications. Surgery, an endovascular interventional procedure with coil and Gelfoam embolisation, or both, can be used to treat a persistent sciatic artery, depending on the clinical presentation and anatomy.^{10,15} In the complete type

of persistent sciatic artery aneurysm, as seen in our patient, options for revascularisation of the lower extremities include graft interposition, a femoro-popliteal bypass, and an iliac-persistent sciatic artery bypass. It is important to place the proximal and distal anastomosis where an adequate bypass graft flow can be achieved and to make sure that the graft course is placed where it will not be susceptible to thrombosis by compression. Femoro-popliteal bypass is the preferred method as it is free from the risk of graft compression.⁵ The superficial femoral artery is reportedly aplastic in 7.4% and hypoplastic in 46.8% in patients with persistent sciatic arteries.⁷ The femoral artery may not have an optimal graft inflow and bypass from the iliac artery should be considered in such cases.

Conclusion

A persistent sciatic artery is a rare congenital anomaly that can present with aneurysm formation or complications associated with an aneurysm. A complete evaluation of the peripheral arterial system of the lower limb is essential before embarking on a surgical or other type of interventional procedure. Our case illustrates how an accurate diagnosis and comprehensive evaluation of potential complications caused by a persistent sciatic artery may be achieved using multi-detector CT angiography.

References

1. de Boer MT, Evans JD, Mayor P, Guy AJ. An aneurysm at the back of a thigh: a rare presentation of a congenitally persistent sciatic artery. *Eur J Vasc Endovasc Surg* 2000;19:99-100.
2. Green PH. On a new variety of the femoral artery. *Lancet* 1832;1:730-1.
3. Fagge CH. Case of aneurysm, seated on an abnormal main artery of the lower limb. *Guy's Hosp Rep* 1864;10:151-9.
4. Mandell VS, Jaques PF, Delany DJ, Oberheuer V. Persistent sciatic artery: clinical, embryologic, and angiographic features. *AJR Am J Roentgenol* 1985;144:245-9.
5. Bower EB, Smullens SN, Parke WW. Clinical aspects of persistent sciatic artery: report of two cases and review of the literature. *Surgery* 1977;81:588-95.
6. Batchelor TJ, Vowden P. A persistent sciatic artery aneurysm with an associated internal iliac artery aneurysm. *Eur J Vasc Endovasc Surg* 2000;20:400-2.
7. Ikezawa T, Naiki K, Moriura S, Ikeda S, Hirai M. Aneurysm of bilateral persistent sciatic arteries with ischemic complications: case report and review of the world literature. *J Vasc Surg* 1994;20:96-103.
8. Freeman MP, Tisnado J, Cho SR. Persistent sciatic artery. Report of three cases and literature review. *Br J Radiol* 1986;59:217-23.
9. Morinaga K, Kuma H, Kuroki M, et al. Occluded persistent sciatic artery. *J Cardiovasc Surg (Torino)* 1985;26:82-5.
10. Vimla NS, Khanna SK, Lamba GS. Bilateral persistent sciatic artery with bilateral aneurysms: case report and review of the literature. *Can J Surg* 1981;24:535-7.
11. Wong J, Wellington JL, Jadick CH, Rasuli P, Waddell WG. Pulsatile buttock mass: report of two cases and a review of the literature. *Can J Surg* 1995;38:275-80.
12. Buckley JG, Levitt RG, Zuckerman DA. Hypoplastic superficial femoral artery associated with bilateral persistent sciatic arteries: a diagnostic pitfall. *Cardiovasc Intervent Radiol* 1992;15:240-3.
13. Shimono T, Nishimura K, Hayakawa K, Fukushima H, Matsuo H. Persistent sciatic artery: three-dimensional reconstructed CT (3D CT) image. *J Comput Assist Tomogr* 1995;19:669-71.
14. Jung AY, Lee W, Chung JW, et al. Role of computed tomographic angiography in the detection and comprehensive evaluation of persistent sciatic artery. *J Vasc Surg* 2005;42:678-83.
15. Maldini G, Teruya TH, Kamida C, Eklof B. Combined percutaneous endovascular and open surgical approach in the treatment of a persistent sciatic artery aneurysm presenting with acute limb-threatening ischemia—a case report and review of the literature. *Vasc Endovascular Surg* 2002;36:403-8.