

# Endovascular repair for abdominal aortic aneurysms: the first hundred cases

CME

Albert CW Ting 丁志偉  
Stephen WK Cheng 鄭永強  
P Ho 何 蓓  
YC Chan 陳耀志  
Jensen TC Poon 潘冬松  
WK Yiu 姚惠琪  
Grace CY Cheung 張頌恩

**Objective** To evaluate the early and mid-term results of the first 100 elective endovascular repairs for abdominal aortic aneurysms.

**Design** Retrospective analysis of prospectively collected data.

**Setting** University teaching hospital, Hong Kong.

**Patients** The first 100 patients with infrarenal abdominal aortic aneurysms who underwent elective endovascular repair.

**Main outcome measures** Peri-operative data, mortality and morbidities as well as the follow-up details were recorded. Cumulative data on endoleaks, clinical failures, secondary procedures, and survival were evaluated with Kaplan-Meier analyses.

**Results** There were 85 men and 15 women, with a mean age of 75 (range, 50-90) years. Failed implantations due to access difficulty occurred in two patients during the same period, giving a technical success rate of 98%. The mean aneurysm diameter was 6.2 cm. Access site injury requiring repair occurred in four (4%) of the patients, while wound problems were the most common complications (11%). The median hospital stay was 6 days, and there were two hospital deaths, giving a hospital mortality rate of 2%. During a mean follow-up of 36 (standard deviation, 24) months, there were three aneurysmal ruptures and four elective open conversions, with only one aneurysm-related death after hospital discharge. At 3 years, the cumulative rates of freedom from any endoleak, freedom from primary failure, freedom from secondary failure, freedom from secondary procedures, and survival were 60%, 84%, 89%, 88%, and 78%, respectively.

**Conclusions** The early and mid-term results of elective endovascular repair for abdominal aortic aneurysms appear promising. The procedure is effective in preventing aneurysm-related death in the mid-term. Nevertheless, the importance of constant surveillance cannot be over-emphasised, as clinical failures and ruptures are still a concern.

## Introduction

Endovascular aneurysm repair was introduced by Parodi et al<sup>1</sup> in 1991 as a less invasive therapeutic alternative to conventional open surgery. Since then, there have been refinements and improvements, with favourable early and mid-term results being reported for various commercially available devices.<sup>2-4</sup> In managing abdominal aortic aneurysms today, endovascular repair has become an acceptable alternative to open surgery. In 2003, it was estimated that in the United States, 42.7% of unruptured and 8.8% of ruptured abdominal aortic aneurysms were repaired through an endovascular approach.<sup>5</sup> As with any new procedure, there is a definite learning curve,<sup>6</sup> and there is always a concern that the favourable results reported in the literature may not be reproduced in local centres. We started our endovascular stent graft programme in July 1999, and the initial results of endovascular repair for abdominal aortic aneurysms were comparable to those of open surgery, with an acceptable mortality and morbidity.<sup>7</sup>

The aim of this study was to review the early and mid-term results of the first 100 elective endovascular repairs for infrarenal abdominal aortic aneurysms in our institution.

## Methods

Aortic endografting was introduced to the Division of Vascular Surgery, University of Hong

### Key words

Aortic aneurysm, abdominal; Aortic rupture; Treatment outcome; Vascular surgical procedures

*Hong Kong Med J* 2008;14:361-6

Division of Vascular Surgery, Department of Surgery, Queen Mary Hospital, Hong Kong

ACW Ting, MS, FRCS  
SWK Cheng, MS, FRCS  
P Ho, MB, BS, FRCS  
YC Chan, MD, FRCS  
JTC Poon, MB, BS, FRCS  
WK Yiu, MB, BS, MRCS  
GCY Cheung, BSc

Correspondence to: Prof SWK Cheng  
E-mail: wkcheng@hku.hk

## 腔內修復術治療腹主動脈瘤的首一百宗病例

目的	評估首一百宗以選擇性腔內修復術治療主動脈瘤的早期和中期療效。
設計	回顧分析以往收集到的前瞻性資料。
安排	香港一所大學教學醫院。
患者	患腎下型腹主動脈瘤並曾接受選擇性血管內修補手術的病人。
主要結果測量	記錄圍術期數據、死亡率和發病率、隨訪的詳細資料，並以Kaplan-Meier分析模型評估內漏、治療無效、二次手術以及存活的累積數據。
結果	患者對象為85男、15女，平均年齡75歲（介乎50至90歲）。同期有兩位病人因穿刺困難以致無法植入，致技術成功率為98%。腫瘤直徑平均為6.2 cm。四位患者(4%)因穿刺部位受傷而需作修補，而傷口問題是最常見的併發症(11%)。留院中位數為6天。有兩位病人在留院期內死亡，致院內死亡率2%。在平均36個月的隨訪期內（標準差：24個月），有三宗動脈瘤再破裂，四宗需施行選擇性開放手術，只有一個出院後的病人死亡是與動脈瘤有關的。術後3年，無內漏、無初次治療失效、無二次治療失效、無需接受二次手術，以及存活的累積比率順序分別為60%、84%、89%、88%和78%。
結論	選擇性腔內修復術治療主動脈瘤的早期和中期療效看來相當顯著，且能有效防止病者因動脈瘤而死亡。由於治療失效和腫瘤破裂仍然是令人憂慮的問題，持續監察的重要性實在不容忽視。

Kong in July 1999. Since then, all patients with infrarenal abdominal aortic aneurysms undergoing elective repair were considered for possible endografting. The aortic neck (length and angulation), the size of the common iliac arteries (landing zones), and the adequacy of the access arteries (lumen diameter and tortuosity) were evaluated by computed tomography. Those who refused or were judged unsuitable for endograft repair underwent conventional repair of their aneurysms. Demographics, operative details, complications, and follow-up data were recorded prospectively.

Using bilateral groin incisions, endograft implantation was performed in the operating room by a team of vascular surgeons, and recourse to image guidance of a mobile C-arm Philips BV-29 (Philips Medical System, The Netherlands) or an OEC 9800 (General Electric Company, Fairfield, CT) system. Embolisation of one internal iliac artery was performed at the same setting if necessary. Postoperatively, patients were assessed regularly with clinical examinations and follow-up computed tomographies, performed 1 month postoperatively as well as every 6 months (in the first 2 years) and at least yearly thereafter. Further endovascular interventions

TABLE 1. Demographics and co-morbidities in patients having endovascular stent graft repairs

Demographics	Value* (n=100)
Age (years)	75±7 (50-90)
Sex (male:female)	85:15
Size of aneurysms (cm)	6.2±0.8 (4.6-8.8)
Smoking	49
ASA Class <sup>†</sup>	
II	45
III	54
IV	1
Co-morbidities	
Cardiac disease	55
Hypertension	72
Respiratory disease	31
Renal impairment (creatinine, >120 µmol/L)	42
Cerebral vascular accident	10
Diabetes mellitus	13

\* Data are shown as No. or mean±standard deviation (range)

† ASA denotes American Society of Anesthesiologists

were performed when appropriate.

Demographics, operative details, and complications were noted. Cumulative data on endoleaks, clinical failures, secondary procedures as defined by the reporting standards,<sup>8</sup> as well as survival, were evaluated by Kaplan-Meier analyses.

## Results

Between July 1999 and November 2007, 148 successful endovascular stent graft repairs were performed for patients with abdominal aorto-iliac aneurysms. The first 100 consecutive elective endovascular repairs for infrarenal abdominal aortic aneurysms formed the basis of this report. During this period, there were two abandoned procedures as a result of access difficulties, giving a technical success rate of 98%. One of the two patients subsequently underwent elective open repair, while the other was treated conservatively with follow-up ultrasound surveillance. During the same period, 88 abdominal aortic aneurysms were repaired by the conventional open method (47%). Demographics, size of aneurysms, and patient co-morbidities are shown in Table 1. Operative details and postoperative complications are shown in Table 2.

In the initial phase of our experience (the first 54 cases), all the procedures were performed under general anaesthesia. Subsequently, we started using more local/regional anaesthesia. Overall, 20% of the operations were performed under local anaesthesia. Management in the Intensive Care Unit (ICU) was routine initially, and gradually changed to apply only

TABLE 2. Peri-operative details and complications in the patients undergoing endovascular stent graft repairs

Peri-operative details	Value* (n=100)
<b>Anaesthesia</b>	
General	78
Local	20
Regional	2
Duration of operation (min)	208±68 (85-480)
Duration of image intensifier (min)	25±14 (6-88)
Contrast (mL)	145±54 (30-300)
Blood loss (mL)	335±310 (50-2000)
Need for transfusion	8
Need for stay in Intensive Care Unit	31
Duration of hospitalisation (days)	9±10 (2-93)
<b>Graft used†</b>	
AneuRx	23
Talent	12
Zenith	60
Excluder	5
<b>Complications</b>	
Access vessel injury	4
Cardiac	8
Respiratory	3
Renal	7
Wound complication	11
Graft limb thrombosis	2

\* Data are shown as No. or mean±standard deviation (range)  
 † AneuRx (Medtronic AVE Inc, Santa Rosa, CA); Talent (Medtronic AVE Inc, Santa Rosa, CA); Zenith (Cook, Bloomington, IN); Excluder (WL Gore, Flagstaff, AZ)

to selective cases. Intensive Care Unit stay was not required in the last 40 patients in this cohort. An aorto-uni-iliac device with a femoro-femoral bypass was performed in three patients, during the early part of the experience.

There were two hospital deaths. A 75-year-old man with longstanding hypertension who underwent endografting died suddenly on postoperative day 4; postmortem examination revealed a type A thoracic aortic dissection with cardiac tamponade. Another 80-year-old man with multiple medical co-morbidities, including chronic renal impairment (creatinine, approximately 200 µmol/L), received endovascular repair for a 7-cm aneurysm. He developed acute-on-chronic renal failure after the procedure and had a prolonged hospital stay and renal replacement therapy. He died suddenly as a result of a ruptured thoracic aortic aneurysm 3 months after the endograft procedure. There were four access site injuries attributed to the sizable devices used for repair. Wound problems—including infection, seroma, and haematoma—were the most commonly encountered

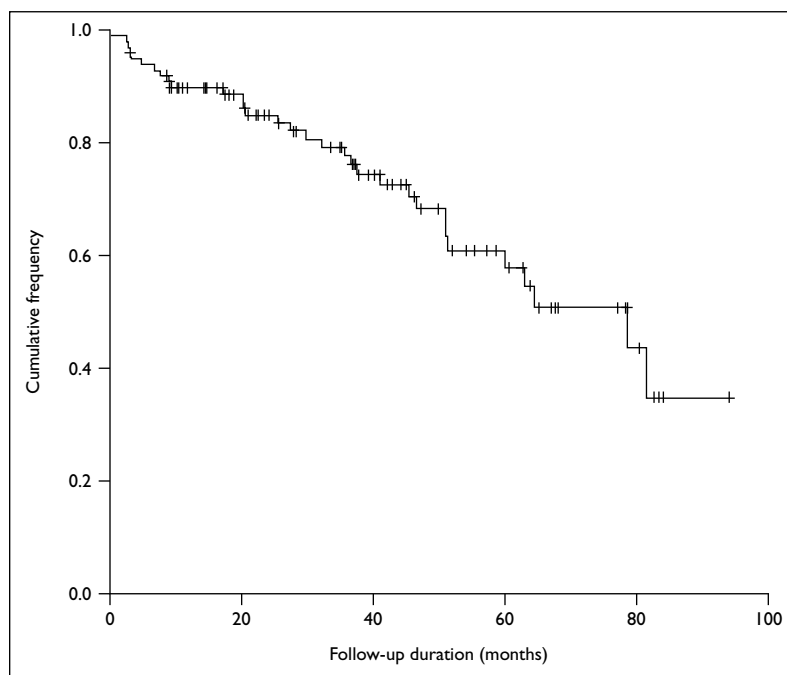


FIG 1. Cumulative survival of the 100 patients undergoing elective endovascular repair of infrarenal abdominal aortic aneurysms

complications (11%).

During a mean follow-up of 36 (standard deviation, 24; range, 0-94) months, the size of the aneurysms was observed to decrease by 5 mm or more in 40 patients, while significant increase in size was also noted in 10 (including two with ruptures). No significant change in sac size was noted in the other 50 patients (including the two patients who died in hospital). There were three aneurysm ruptures; one due to a dislodged stent graft with a type Ia endoleak, the other due to a type II endoleak from lumbar branches with associated increasing sac size that failed endovascular intervention, while the third was an enlarging aneurysm sac despite no identifiable endoleak. Only one of these patients died (an 83-year-old woman whose aneurysm ruptured and was treated conservatively because of her poor pre-morbid condition). Four patients underwent elective open conversions (two for dislodged proximal stent grafts and the other two for increasing sac size with endoleak that was not identified on angiogram in one and no identifiable endoleak in the other); all of them survived.

**Survival**

Thirty-two patients died during the period of this study. Apart from the two hospital mortalities, there was only one aneurysm-related death, namely the 83-year-old woman whose aneurysm ruptured. The other patients died of unrelated causes (malignancies, cardiac diseases, and respiratory problems being

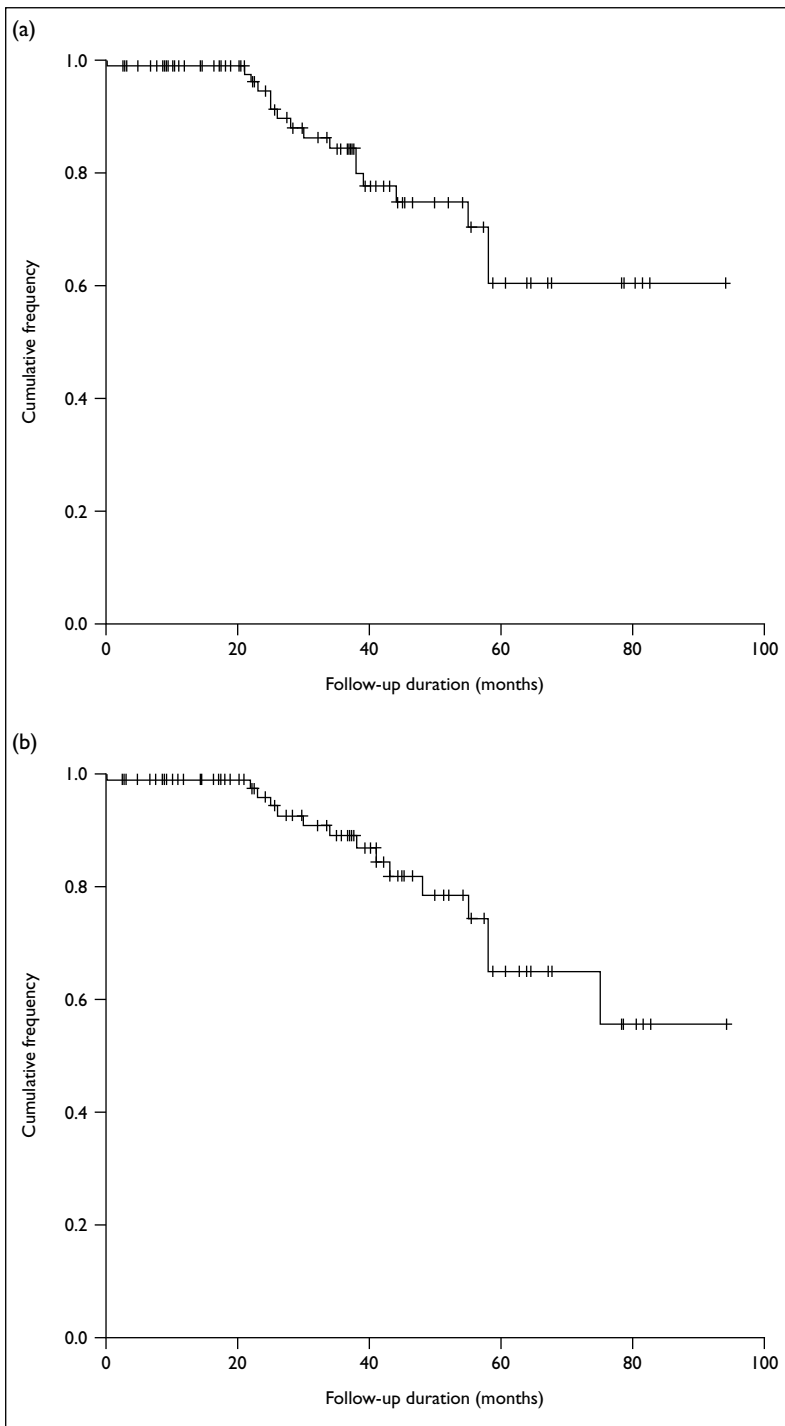


FIG 2. Cumulative freedom from (a) primary failure and (b) secondary failure in the 100 patients undergoing elective endovascular repair of infrarenal abdominal aortic aneurysms

the common cause of death). The cumulative 3-year survival rate was 78% (Fig 1).

**Endoleak**

Endoleak was a common observation; 39 patients experienced one at some point during the follow-up period, giving a cumulative freedom from any

endoleak of 60% at 3 years. However, most of the endoleaks (80%) were early, detected intra-operatively or at the 1-month computed tomography. All except five were type II, two were type Ia, one was type Ib, and two were type III. All patients with non-type II endoleaks underwent secondary interventions.

**Clinical failures and secondary intervention**

Apart from two hospital mortalities, there were three other patients whose aneurysms ruptured. There were 10 in whom the aneurysm sac size increased 5 mm or more (including two patients with ruptures). There were two proximal and one distal stent graft migrations, two type Ia, one type Ib, and two type III endoleaks; for all of these patients, secondary interventions were performed. The cumulative freedom from primary failure and secondary failure at 3 years were 84% and 89%, respectively (Fig 2). Secondary intervention (excluding diagnostic angiograms) was performed in 13 patients, and included six open conversions (two for ruptures), three proximal aortic cuff deployments, four distal limb extensions, two angiographic embolisations for endoleaks, and clipping of the inferior mesenteric artery in another two. The cumulative freedom from secondary interventions was 88% at 3 years (Fig 3).

**Discussion**

The early results of endovascular repair for abdominal aortic aneurysms appear satisfactory, with a 98% successful endograft deployment rate and an operative mortality of only 2%. The goal of elective aneurysm repair is to prevent aneurysm rupture and aneurysm-related death. Endovascular repair appears to have excellent efficacy in the mid-term, as judged by the fact that after a mean follow-up of 36 months, there was only one aneurysm-related death (ruptured aneurysm) after discharge, although there were two other aneurysmal ruptures in this series. Freedom from secondary procedures was 88% at 3 years, which is comparable to rates published in the world literature.<sup>9</sup> In the recent report from the EUROSTAR collaborators,<sup>9</sup> the cumulative incidence of secondary interventions was 12% at 3 years in those treated with the currently available stent grafts, which was markedly superior to rates reported with older-generation stent grafts. Nevertheless, this figure is still significant and the need for regular follow-up and imaging surveillance is an imperative.

Endoleak is always a concern after endovascular repair of aneurysms. Although some regard endoleaks as failure to exclude the aneurysm that risks further growth and rupture,<sup>10</sup> the clinical significance of endoleaks and their impact on the natural history of an aneurysm remains uncertain.<sup>11,12</sup> The degree of endoleak in our study was significant, with a cumulative

freedom from any endoleak of 60% at 3 years. This appears higher than that reported from Massachusetts General Hospital, where they encountered a rate of 26.1% in their group of 873 patients who underwent endovascular stent graft repair for abdominal aortic aneurysms.<sup>13</sup> Nevertheless, as the vast majority in our series were type II, the freedom from primary clinical failure or reintervention was actually comparable to their cohort.<sup>13</sup> During our early experience, endoleak was managed aggressively with angiography and intervention even in those that were type II, regardless of the aneurysm sac size. With recent reports on the safety of a more conservative approach with selective interventions in type II endoleaks,<sup>14,15</sup> we were also more selective in the later part of our experience. Thus, intervention for type II endoleak was only considered if there was an enlarging sac. Our approach appears to be safe as there were only three aneurysm ruptures in this series—one from proximal stent dislodgement, one from a type II endoleak that failed endovascular intervention, and the other from an enlarging sac with no identifiable endoleak.

At 3 years, in our series the cumulative survival was only 78%. This was similar to that from the Massachusetts General Hospital,<sup>13</sup> where a 3-year cumulative survival of 72.9% was reported, and at 5 years the figure decreased to 52.1%. Such an outcome underscores the observation that truly long-term results in patients receiving endovascular stent graft repair for abdominal aortic aneurysms may not be of paramount importance. This was particularly likely in many elderly patients and those who are medically frail due to multiple co-morbidities.<sup>13</sup>

As with any new surgical procedure, there is a definite learning curve associated with aortic endografting.<sup>6</sup> With increasing experience as well as technical advances, further improvements in peri-operative results are anticipated. In particular, with better patient selection and the introduction of more flexible devices that have lower profiles, access site complications can probably be reduced further. Most of our patients had multiple co-morbidities; more than half (55%) were classified as American Society of Anesthesiologists Class III and IV. Although the EVAR II trial<sup>16</sup> showed no survival benefit from operating on high-risk patients, we believe it is a worthwhile option for those who would otherwise be denied of any surgical treatment. In our patients, the duration of hospital stay was longer than that in western counterparts. This was very likely due to the unique, local, medical charge system, whereby patients only pay a minimal amount for their hospitalisation. Another reason could be cultural, whereby Chinese patients prefer to stay in hospital until they perceive themselves to be completely well.

During the study period, there were several refinements in the procedures. The choice of stent graft changed to those with suprarenal stent fixation.

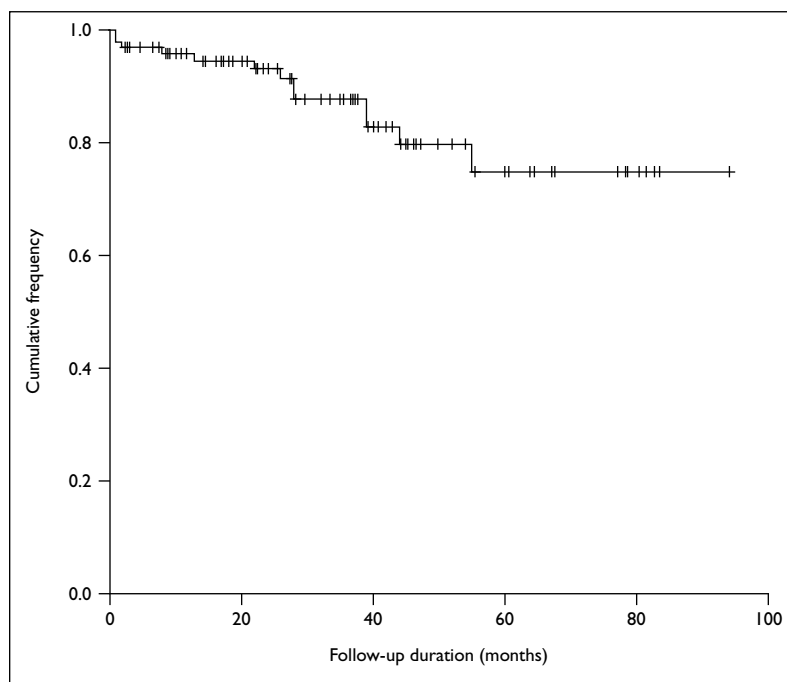


FIG 3. Cumulative freedom from secondary intervention in the 100 patients undergoing elective endovascular repair of infrarenal abdominal aortic aneurysms

For the last 40 patients in our cohort, only grafts with this type of fixation were used. In the early report by Connors et al,<sup>17</sup> an alarmingly high rate of device migration of 5 mm or more (20.4% at 2 years and 42.1% at 3 years) was noted with AneuRx endograft (Medtronic AVE Inc, Santa Rosa, CA, US), which does not have suprarenal stent fixation. Suprarenal stent fixation may prevent migration especially if there is aortic neck angulation.<sup>18,19</sup> In the further study by the same group,<sup>18</sup> Zenith endografts (Cook, Bloomington, IN, US) that have suprarenal stent fixation, were noted to have significantly less stent migration that exceeded 10 mm or lead to clinical events than with the AneuRx endograft was used (2.4% vs 28% at 4 years). Apart from having barb-enhanced suprarenal stent fixation, it also has the additional advantage of allowing an adequate seal in ecstatic common iliac arteries with a diameter of up to 20 mm.<sup>20</sup> Besides the choice of graft, aorto-uni-iliac device insertion was seldom practised in the elective setting. Other changes included increasing use of locoregional anaesthesia, and ICU admission became non-mandatory.

All the procedures were performed in the operating room by a group of vascular surgeons. As shown by Chang et al,<sup>21</sup> favourable results can be achieved in an endovascular stent graft programme solely operated by vascular surgeons with prior endovascular experience. Open vascular access via groin incisions and other adjunctive vascular procedures (such as repair of damaged access vessels or reimplantation of internal iliac artery)

may be necessary. Thus, a sterile, well-equipped, and appropriately staffed environment (such as the operating room) is most suitable for the procedure. With the use of various hybrid techniques and de-branching procedures, this setting also allows extension of the procedures to treat lesions in other anatomical locations such as the paravisceral aorta or aortic arch.<sup>22,23</sup>

## Conclusions

Endovascular repair for abdominal aortic aneurysms

appears to be a promising procedure that facilitates treatment of patients with multiple co-morbidities. The resulting mortality and morbidity were acceptable and comparable to international standards. The peri-operative results should continue to improve with advances in technology and experience. Nonetheless, there is a need for close follow-up surveillance, due to the considerable risk of clinical failure requiring secondary intervention, and ruptures still occur. Furthermore, the long-term efficacy of endovascular treatment in preventing aneurysm rupture remains unproven.

## References

- Parodi JC, Palmaz JC, Barone HD. Transfemoral intraluminal graft implantation for abdominal aortic aneurysms. *Ann Vasc Surg* 1991;5:491-9.
- Greenberg RK, Lawrence-Brown M, Bhandari G, et al. An update of the Zenith endovascular graft for abdominal aortic aneurysms: initial implantation and mid-term follow-up data. *J Vasc Surg* 2001;33(2 Suppl):157S-164S.
- Criado FJ, Wilson EP, Fairman RM, Abul-Khoudoud O, Wellons E. Update on the Talent aortic stent graft: a preliminary report from United States phase I and II trials. *J Vasc Surg* 2001;33(2 Suppl):146S-149S.
- Zarins CK, White RA, Moll FL, et al. The AneuRx stent graft: four-year results and world wide experience 2000. *J Vasc Surg* 2001;33(2 Suppl):135S-145S.
- Cowan JA Jr, Dimick JB, Henke PK, Rectenwald J, Stanley JC, Upchurch GR Jr. Epidemiology of aortic aneurysm repair in the United States from 1993 to 2003. *Ann NY Acad Sci* 2006;1085:1-10.
- Buth J, Laheij RJ. Early complications and endoleaks after endovascular abdominal aortic aneurysm repair: report of a multicenter study. *J Vasc Surg* 2000;31:134-46.
- Ting AC, Cheng SW, Ho P. Endovascular repair for abdominal aortic aneurysms: initial experience of an endograft programme. *Asian J Surg* 2003;26:17-21.
- Chaikof EL, Blankensteijn JD, Harris PL, et al. Reporting standards for endovascular aortic aneurysm repair. *J Vasc Surg* 2002;35:1048-60.
- Hobo R, Buth J; EUROSTAR collaborators. Secondary interventions following endovascular abdominal aortic aneurysm repair using current endografts. A EUROSTAR report. *J Vasc Surg* 2006;43:896-902.
- Schurink GW, Aarts NJ, van Bockel JH. Endoleak after stentgraft treatment of abdominal aortic aneurysm: a meta-analysis of clinical studies. *Br J Surg* 1999;86:581-7.
- Resch T, Ivancev K, Lindh M, et al. Persistent collateral perfusion of abdominal aortic aneurysm after endovascular repair does not lead to progressive change in aneurysm diameter. *J Vasc Surg* 1998;28:242-9.
- Zarins CK, White RA, Hodgson KJ, Schwarten D, Fogarty TJ. Endoleak as a predictor of outcome after endovascular aneurysm repair: AneuRx multicenter clinical trial. *J Vasc Surg* 2000;32:90-107.
- Brewster DC, Jones JE, Chung TK, et al. Long-term outcomes after endovascular abdominal aortic aneurysm repair: the first decade. *Ann Surg* 2006;244:426-38.
- Silverberg D, Baril DT, Ellozy SH, et al. An 8-year experience with type II endoleaks: natural history suggests selective intervention is a safe approach. *J Vasc Surg* 2006;44:453-9.
- Steinmetz E, Rubin BG, Sanchez LA, et al. Type II endoleak after endovascular abdominal aortic aneurysm repair: a conservative approach with selective intervention is safe and cost-effective. *J Vasc Surg* 2004;39:306-13.
- EVAR trial participants. Endovascular aneurysm repair and outcome in patients unfit for open repair of abdominal aortic aneurysm (EVAR trial 2): randomised controlled trial. *Lancet* 2005;365:2187-92.
- Conners MS 3rd, Sternbergh WC 3rd, Carter G, Tonnessen BH, Yoselevitz M, Money SR. Endograft migration one to four years after endovascular abdominal aortic aneurysm repair with the AneuRx device: a cautionary note. *J Vasc Surg* 2002;36:476-84.
- Tonnessen BH, Sternbergh WC 3rd, Money SR. Mid- and long-term device migration after endovascular abdominal aortic aneurysm repair: a comparison of AneuRx and Zenith endografts. *J Vasc Surg* 2005;42:392-401.
- Robbins M, Kritpracha B, Beebe HG, Criado FJ, Daoud Y, Comerota AJ. Suprarenal endograft fixation avoids adverse outcomes associated with aortic neck angulation. *Ann Vasc Surg* 2005;19:172-7.
- Timaran CH, Lipsitz EC, Veith FJ, et al. Endovascular aortic aneurysm repair with the Zenith endograft in patients with ectatic iliac arteries. *Ann Vasc Surg* 2005;19:161-6.
- Chang JK, Calligaro KD, Dougherty MJ. Initial experience with endovascular aortic aneurysm repair without cardiologists or radiologists—do vascular surgeons really need them? *Vasc Endovascular Surg* 2004;38:413-6.
- Gawenda M, Aleksic M, Heckenkamp J, Reichert V, Gossmann A, Brunkwall J. Hybrid-procedures for the treatment of thoracoabdominal aortic aneurysms and dissections. *Eur J Vasc Endovasc Surg* 2007;33:71-7.
- Antona C, Vanelli P, Petullà M, et al. Hybrid technique for total arch repair: aortic neck reshaping for endovascular-graft fixation. *Ann Thorac Surg* 2007;83:1158-61.