

# Bilateral cervical spondylolysis in a young Chinese woman presenting with a neck injury

Annie CW Tam 譚枝慧

John LY Leung 梁禮賢

KY Lau 劉錦英

PK Yee 俞柏堅

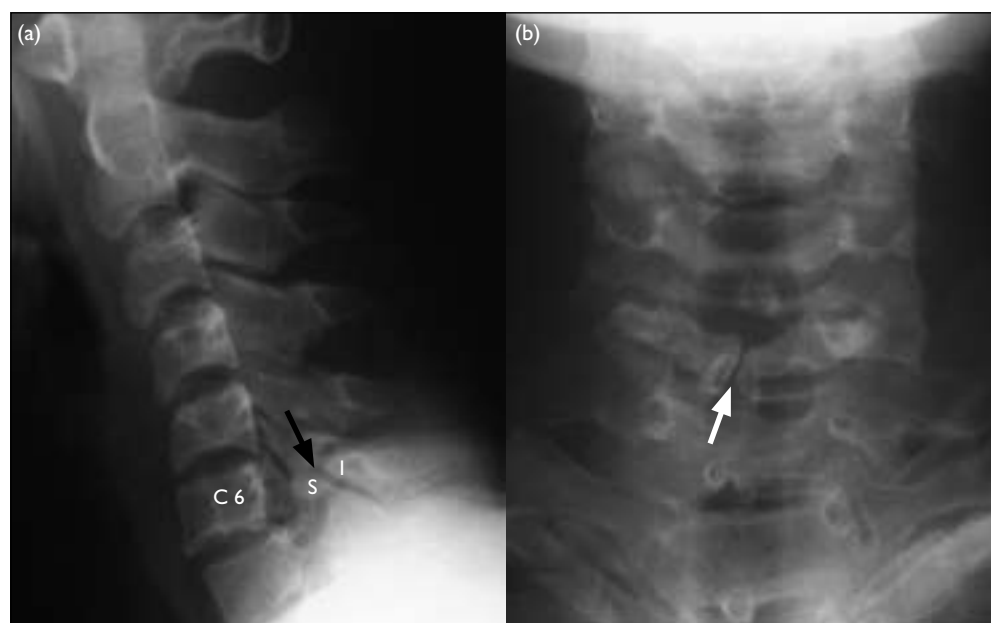
Cervical spondylolysis is an uncommon entity. It is important to recognise its characteristic radiological features and differentiate it from acute cervical fractures or dislocations in patients with neck injuries. We report the relevant clinical and radiological findings seen in a young Chinese woman managed in our hospital after a neck injury who was ultimately diagnosed with bilateral cervical spondylolysis with spondylolisthesis at C6.

## Introduction

Cervical spondylolysis is an uncommon entity. It was first described by Perlman and Hawes in 1951.<sup>1</sup> To the best of our knowledge, the anomaly has never been reported in a Chinese patient. On conventional radiographic images the anomaly can mimic acute cervical fracture or dislocation, especially in a patient admitted for the management of a neck injury. Recognition of the characteristic radiological features on plain radiographs and computed tomography (CT) enables a precise diagnosis. We report the clinical and radiological findings seen in a young Chinese woman who was managed in our hospital after a neck injury and later diagnosed with bilateral C6 cervical spondylolysis with spondylolisthesis.

## Case report

A 19-year-old Chinese woman with good past health was brought to the casualty unit in September 2007 after being involved in a road traffic accident. She was the front seat passenger of a private car that crashed head-on into a minibus. The car's left-side mirror flew off and hit the patient's left forehead and she had head and neck pain after the accident. A physical examination revealed mild tenderness over her forehead and the left side of her neck. There were no focal neurological signs and she had full range of movement in her neck. Nonetheless, a lateral radiograph of the cervical spine showed a cleft between the superior and inferior facets of the articular pillar of C6 and grade I spondylolisthesis at C6 anteriorly with respect to C7 (Fig 1a). A frontal radiograph showed spina bifida occulta at



### Key words

Spondylolisthesis; Spondylolysis;  
Tomography, X-ray computed

*Hong Kong Med J* 2008;14:324-6

Pamela Youde Nethersole Eastern  
Hospital, Chai Wan, Hong Kong:  
Department of Radiology  
ACW Tam, MB, ChB  
JLY Leung, MB, BS, FRCS  
KY Lau, FRCS, DABRad (DR)  
Department of Orthopaedics and  
Traumatology  
PK Yee, MB, ChB, MRCS

Correspondence to: Dr ACW Tam  
E-mail: tamcw2@ha.org.hk

FIG 1. (a) Lateral radiograph of cervical spine showed a cleft between the superior (S) and inferior (I) facets of the articular pillar of C6 (black arrow) and grade I anterolisthesis of C6. (b) Frontal radiograph showed spina bifida occulta of C6 (white arrow)

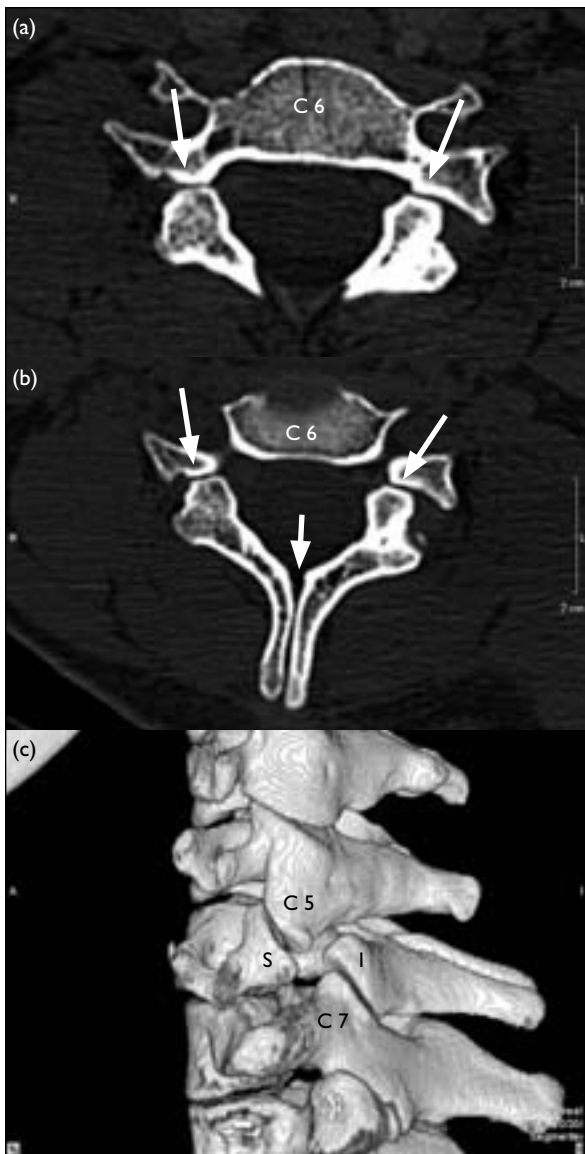


FIG 2. (a, b) Axial computed tomographic (CT) images of C6 vertebra revealed well-corticated cleft between bilateral C6 facets (long arrows) and spina bifida of C6 (short arrow). (c) Three-dimensional reconstructed CT image of the cervical spine showed a triangular configuration of the superior (S) and inferior (I) facet fragments on either side of the spondylolytic defect giving the 'bow tie' appearance. There was mild posterior displacement of the dorsal triangular pillar fragment and compensatory hyperplasia of the articular pillars at the levels above and below the defect

C6 (Fig 1b).

A multi-detector CT scan of the cervical spine was performed. It revealed well-corticated clefts between bilateral C6 facets (Fig 2a). Spina bifida at C6 was demonstrated (Fig 2b). Reconstructed images showed a triangular configuration of the pillar fragments on either side of the spondylolytic defect, giving a 'bow tie' appearance (Fig 2c). There was a 3-mm anterior displacement of the C6 vertebra in relation to C7. Mild posterior displacement of the

## 一名患有雙側頸椎骨脫離並呈現頸傷的華裔年輕女性

頸椎骨脫離屬於一種不常見的症候群，因此確認此病的影像學特徵很重要，並且當病人有頸傷時，懂得將此病與急性頸椎骨折或頸椎骨折脫位分辨出來。本文報告一名呈現頸傷的華裔年輕女性，最終被發現患有雙側頸椎骨脫離，並在C6位置呈脊椎前移。

dorsal triangular pillar fragment and compensatory hyperplasia of the articular pillars at the levels above and below the defects were also found (Fig 2c). No spinal stenosis was noted. No prevertebral or paravertebral soft tissue densities suggesting haematomas were seen. The diagnosis of bilateral cervical spondylolysis was then confirmed.

The patient was managed conservatively and discharged upon subsequent symptomatic improvement.

## Discussion

Forsberg et al<sup>2</sup> defined cervical spondylolysis as a "corticated cleft between the superior and inferior articular facets of the articular pillar, the cervical equivalent of the pars interarticularis in the lumbar spine". Many authors believe the anomaly is congenital or due to faulty ossification within the single ossification centre of the articular mass.<sup>2-9</sup> There is only one reported association with other congenital anomalies, in a patient with Rubinstein-Taybi syndrome.

The age at presentation of patients with cervical spondylolysis ranges from 8 to 81 years and it is diagnosed more frequently in men.<sup>2-4</sup> It is commonly diagnosed after a minor neck injury. The symptoms vary from mild non-specific neck pain, neck stiffness, to radioculopathy. Some cases are asymptomatic and most patients do not have neurological deficits. The anomaly can be unilateral or bilateral and is most commonly seen at C6, followed by C4. A single level defect is most commonly seen, but a simultaneous involvement of three levels has also been reported.<sup>9</sup>

Characteristic radiological features include a well-corticated cleft between the facets, a triangular configuration of the pillar fragments similar to a cleft bow tie, posterior displacement of the dorsal triangular pillar fragment, hypoplasia of the ipsilateral pedicle, spina bifida and compensatory hyper- or hypo-plasia of the articular pillars at the adjacent levels.<sup>2</sup> The spondylolisthesis is usually grade I and less than 3 mm.<sup>8</sup>

In cervical spondylolysis plain films often suggest the diagnosis; recognition of characteristic

features on CT scanning will give a definite diagnosis. Computed tomographic scans can clearly differentiate cervical spondylolysis from acute articular mass fractures, in which irregular unmarginated fracture fragments and soft tissue swelling should be evident.<sup>7</sup> The traditional 'bow tie' or 'bat wing' appearances of overriding locked facets in unilateral facet dislocation observed on lateral radiographs can mimic spondylolysis. Familiarity with spondylolysis enables the correct observation that the inferior facet is not displaced relative to the superior facet and that the appearance is in fact due to a corticated defect dividing the articular mass, giving a triangular configuration of ventral and dorsal fragments. The articular pillar defect can be difficult to identify on magnetic resonance imaging (MRI). In one report, the defects were seen in only one out of three cases on MRI; it was the absence of the spinous process on sagittal sequences that pointed to the anomaly.<sup>10</sup> Magnetic resonance imaging is more useful, when clinically necessary, for evaluating the spinal cord, not the osseous anatomy.<sup>4</sup>

The rarity of this condition means the natural course of cervical spondylolysis has not been well described. Most reported cases have been managed conservatively. Surgery is considered when there is instability or when conservative therapy fails.<sup>11</sup> Mofidi et al<sup>12</sup> found a direct statistical association between

the presence of instability diagnosed by the lateral C-spine radiograph or after flexion/extension views and the presence of neurological abnormalities. They advocated performing controlled dynamic views to further assess the stability of cervical spondylolysis in the absence of radiological signs of cervical spinal instability on plain radiographs and neurological deficits and in the presence of active head control. The cervical spine is considered to be unstable when all the anterior or posterior elements are destroyed or unable to function; measured as more than 3.5 mm of horizontal displacement in one vertebra in relation to subjacent vertebrae or more than 11 degrees of anterior tilt compared with subjacent vertebrae in lateral cervical radiographs or dynamic flexion/extension radiographs. Computed tomography, which has good spatial resolution and the ability to create a 3-dimensional reconstruction, can delineate the extent of bony injury. Magnetic resonance imaging is useful for assessing the condition of the spinal cord as well as the presence of paravertebral soft tissue injury, bony oedema and associated disc herniation around the involved segment.

In conclusion, cervical spondylolysis has characteristic radiological features. Recognition of the anomaly and differentiating it from acute cervical fracture or dislocation is important in patients with recent neck injuries.

## References

1. Perlman R, Hawes LE. Cervical spondylolisthesis. *J Bone Joint Surg Am* 1951;33A:1012-3.
2. Forsberg DA, Martinez S, Vogler JB 3rd, Wiener MD. Cervical spondylolysis: imaging findings in 12 patients. *AJR Am J Roentgenol* 1990;154:751-5.
3. Poggi JJ, Martinez S, Hardaker WT Jr, Richardson WJ. Cervical spondylolysis. *J Spinal Disord* 1992;5:349-56.
4. Hinton AM, Harris MB, King AG. Cervical spondylolysis. Report of two cases. *Spine* 1993;18:1369-72.
5. Schwartz JM. Case 36: bilateral cervical spondylolysis of C6. *Radiology* 2001;220:191-4.
6. Robson MJ, Brown LM, Sharrard WJ. Cervical spondylolisthesis and other skeletal abnormalities of Rubinstein-Taybi syndrome. *J Bone Joint Surg Br* 1980;62:297-9.
7. Charlton OP, Gehwesler JA, Morgan CL, Martinez S, Daffuer RH. Spondylolysis and spondylolisthesis of the cervical spine. *Skeletal Radiol* 1978;3:79-84.
8. Jeyapalan K, Chauda SV. Case report 868. *Skeletal Radiol* 1994;23:580-2.
9. Yochum TR, Carton JT, Barry MS. Cervical spondylolysis: three levels of simultaneous involvement. *J Manipulative Physiol Ther* 1995;18:411-5.
10. Redla S, Sikdar T, Saifuddin A, Taylor BA. Imaging features of cervical spondylolysis—with emphasis on MR appearances. *Clin Radiol* 1999;54:815-20.
11. Goupille P, Fouquet B, Cotty P, Valat JP. Cervical spondylolysis [letter]. *AJR Am J Roentgenol* 1991;157:1127-8.
12. Mofidi A, Tansey C, Mahapatra SR, Mirza HA, Eisenstein SM. Cervical spondylolysis, radiologic pointers of stability and acute traumatic as opposed to chronic spondylolysis. *J Spinal Disord Tech* 2007;20:473-9.