

Multimodal computed tomography evaluation before thrombolysis in acute ischaemic stroke

Thomas W Leung 梁慧康
Wynnie WM Lam 林慧雯
Simon CH Yu 余俊豪
Cecilia SF Leung 梁淑芳
Yannie OY Soo 蘇藹欣
Lawrence KS Wong 黃家星

Currently, when stroke patients are offered thrombolytic therapy, their ischaemic stroke subtypes are usually unknown. Given the risk of haemorrhage that accompanies thrombolytic therapy, unselective (or indiscriminating) use of recombinant tissue plasminogen activator in patients without large-artery thromboemboli is potentially hazardous. Advances in computed tomography techniques have enabled the stroke pathophysiology to be quickly delineated by multimodal computed tomography without compromise in time for recombinant tissue plasminogen activator administration. Through description of the investigation of a typical stroke patient, we report how this technique is feasible in a regional hospital and may guide judicious use of recombinant tissue plasminogen activator.

Introduction

Stroke is a leading cause of death and the most common cause of adult disability in developed countries.¹ A North American multi-centre trial showed that strictly monitored treatment with intravenous recombinant tissue plasminogen activator (rtPA) within 3 hours of the onset of an ischaemic stroke improved clinical outcomes at 3 months.² A critical determinant of therapeutic success is prompt initiation of the therapy. In order to achieve a short 'door-to-needle' time, only a non-contrast brain computed tomography (CT) to exclude intracerebral haemorrhage (ICH) was required before commencing rtPA therapy.

Nonetheless, rtPA treatment is not without risk. In the trial described above, the incidence of ICH was 6.4% in the group receiving rtPA compared to 0.6% in the controls.² Moreover, bleeding at other sites is also possible. The established beneficial effect of rtPA is lysis of fresh thromboemboli in large cerebral arteries. Ischaemic strokes caused by other mechanisms, like occlusive small vessel disease, large artery steno-occlusion without thrombosis, arterial dissection, cerebral vasospasm and haemodynamic insufficiency, are not therapeutic targets for rtPA. With its attendant haemorrhagic risk, indiscriminate use of rtPA for all stroke subtypes is potentially hazardous.³

Adjunctive neuroimaging, notably multimodal CT or magnetic resonance (MR) imaging, has been advocated to elucidate the stroke pathophysiology and thus differentiate the stroke subtype prior to thrombolysis.⁴ Multimodal CT studies, which comprise non-contrast CT, perfusion CT and CT angiography, may identify salvageable brain tissue and occlusions of large arteries that might be amenable to reperfusion therapy.

A major concern limiting use of these additional investigations is the possible delay in commencing rtPA administration. Nevertheless, with modern equipment, perfusion CT and CT angiography can now be performed rapidly at the same time as plain brain imaging. We report how a multimodal CT study, now incorporated into a fast-track stroke assessment protocol in a regional hospital, can quickly elucidate the stroke pathophysiology and guide rtPA therapy without loss of time.

Key words

Cerebral hemorrhage; Thrombolytic therapy; Tissue plasminogen activator; Tomography, X-ray computed

Hong Kong Med J 2008;14:236-9

Case report

In February 2007, an 80-year-old woman had a witnessed fall at home at 10:30 am. She had been independent in daily living and was on treatment for diabetes mellitus and hypertension. She arrived at the accident and emergency department (A&E) at 11:07 am. Her blood pressure was 173/74 mm Hg and Hemostix reading was 14 mmol/L. Her electrocardiogram showed atrial fibrillation with a ventricular rate of 64/min. She was mute, failed to follow any simple commands, and her right limbs were grossly weak and flaccid. The provisional diagnosis was acute stroke.

A neurologist assessed her within 20 minutes of presentation. The presence of global aphasia, right-sided eye deviation, and a dense right hemiplegia was compatible with a stroke affecting the dominant hemisphere. Her National Institute of Health Stroke Score was 11. An urgent platelet count and a coagulation profile were requested.

Prince of Wales Hospital, The Chinese University of Hong Kong, Shatin, Hong Kong;
Division of Neurology, Department of Medicine and Therapeutics
TW Leung, FHKAM (Medicine)
CSF Leung, RN
YOY Soo, MRCP
LKS Wong, MD
Department of Radiology and Organ Imaging
WWM Lam, FRCR
SCH Yu, FRCR

Correspondence to: Dr TW Leung
E-mail: drtleung@cuhk.edu.hk

A non-contrast brain CT showed neither an acute ICH nor signs of early infarction. The differentiation of the grey-white matter and 'insular ribbon' were preserved; the sulci were not effaced; the 'dense' or 'dot' middle cerebral artery (MCA) sign was absent (Fig 1a) [door-to-CT brain interpretation time, 46 minutes]. Computed tomographic angiography showed a total occlusion at M1 segment of the left MCA (Fig 1b). A dynamic perfusion CT study (by a 64-detector CT, General Electronics, Milwaukee, US) outlined an extensive ischaemic penumbra over the left MCA territory, characterised by a prolonged mean transit time (Fig 1c) and a diminished blood flow (Fig 1d). The absence of collateral flow to distal MCA branches suggested that the occlusion was acute. The total scanning time for the multimodal CT study was 6 minutes.

A 4-cm subcutaneous haematoma was noted in the patient's right groin, possibly related to an elective coronary angiogram performed 2 weeks previously. Intravenous administration of rtPA was therefore contra-indicated. The alternative route, intra-arterial administration, was chosen instead.

應用溶栓療法治療急性缺血性腦卒中前以多模電腦體層攝影作評估

以溶栓療法治理中風，醫生是無法知悉病人所出現的缺血性腦卒中所屬的類型。基於溶栓療法過程中有可能併發溢血，假如不加選擇，對腦大動脈並無形成血栓的病人一律施用重組組織型纖溶酶原啟動劑，有可能造成損害。電腦體層攝影技術的提升，能迅速呈現患者中風的病理生理學特徵，但又不曾延誤對適合的病人施用重組組織型纖溶酶原啟動劑。本文描述了對一位典型中風病人的調查研究，展示了這種技術在地區醫院的可行性，以及可指引醫護人員明智而審慎地應用重組組織型纖溶酶原啟動劑。

Occlusion of M1 left MCA was confirmed by digital subtraction angiography (Fig 2a). There was no evidence of Willisian or leptomeningeal collateral flow to the affected hemisphere. Recombinant tissue plasminogen activator was delivered at 1 mg/min through a micro-catheter perched adjacent to the MCA clot.

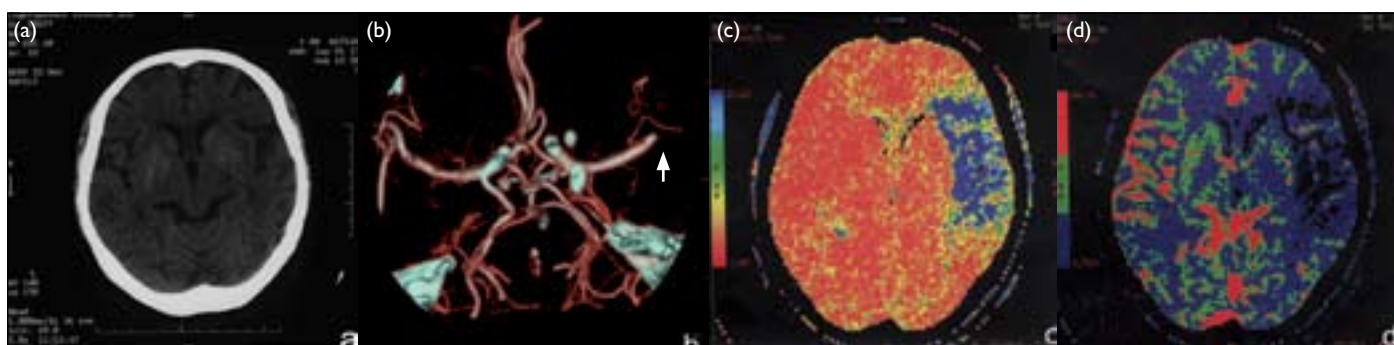


FIG 1. Images of multimodal computed tomography (CT)

Non-contrast brain CT obtained 75 minutes after onset of symptom showed no acute haematoma or signs of early infarction (Fig 1a). Three-dimensional CT angiogram revealed a complete occlusion at M1 segment of the left middle cerebral artery (MCA; Fig 1b, white arrow). Transverse perfusion CT scans obtained at the level of basal ganglia revealed marked malperfusion over the left MCA territory, characterised by a prolonged mean transit time (blue discolouration in Fig 1c); and a diminished blood flow (black discolouration in Fig 1d)

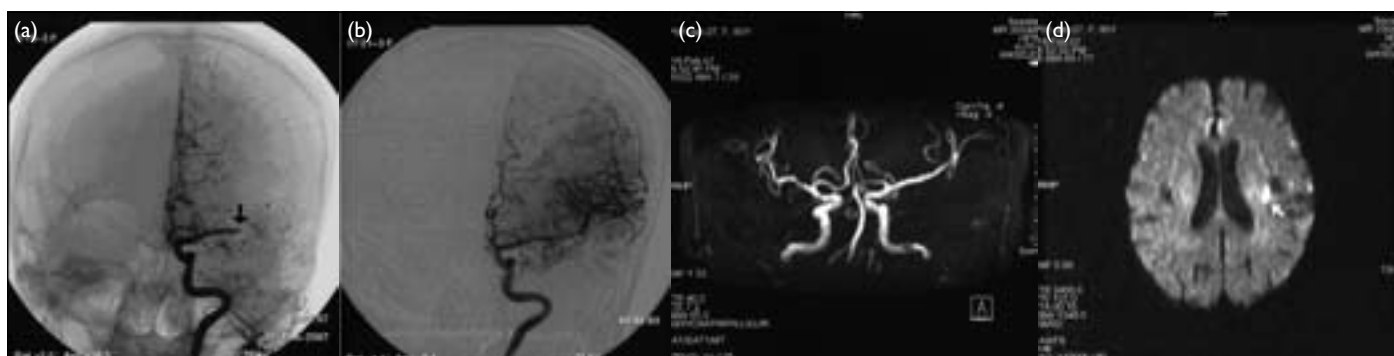


FIG 2. The left middle cerebral artery (MCA) occlusion in digital subtraction angiography (Fig 2a, black arrow) strongly resembled the computed tomographic angiogram. Re-canalisation followed intra-arterial thrombolysis (Fig 2b). On day 4, the left MCA was 'patent' on the magnetic resonance angiogram (Fig 2c). The final infarct shown in diffusion-weighted magnetic resonance imaging was much smaller than the ischaemic penumbra before thrombolysis (Fig 2d, white arrow)

The left MCA totally recanalised after 7 mg of rtPA, ie one seventh of the intravenous dosage (0.9 mg/kg) [Fig 2b]. The door-to-recanalisation time was 2 hours and 55 minutes. The symptom-to-recanalisation time was 3 hours and 32 minutes. No haemorrhagic complications developed.

The patient's hemiparesis and aphasia resolved in 2 days. On day 4, the recanalised MCA was seen to be 'patent' on an MR angiogram (Fig 2c). A small subcortical infarct was apparent over the left parietal lobe on diffusion-weighted MR imaging (Fig 2d). Fraxiparine, followed by warfarin, were given as secondary stroke prophylaxis. Upon discharge on day 5, the patient had no clinical neurological deficits. On day 30, her modified Rankin score was 0, indicating a full functional recovery.

Discussion

Currently, fewer than 1% of Hong Kong patients with ischaemic strokes receive thrombolytic therapy. Apart from delayed presentation, one major hurdle is the difficulty selecting suitable patients. Brain CT is often the only imaging test used before commencement of rtPA but is insensitive for detecting early, acute, or small cortical or subcortical infarcts, especially in the posterior fossa.⁵ The size and location of the acute infarct, the intracranial vessel status, cerebral haemodynamic status and the culprit vascular occlusion are determined mostly by guesswork before thrombolysis. In fact, more than one fourth of all patients who are eligible for rtPA according to the recommendations of the American Heart Association and American Academy of Neurology^{6,7} do not have large-artery occlusions and would have a 5 to 10% risk of haemorrhage if given intravenous thrombolysis.³ Furthermore, conditions that can masquerade strokes, such as complicated migraine, unwitnessed seizures, and functional deficits, are difficult to distinguish from stroke when one depends on the clinical examination and a brain CT alone. This lack of diagnostic specificity may deter physicians from offering rtPA because of the risk of inducing haemorrhage.

As shown by the case described above, multimodal CT can promptly elucidate stroke pathophysiology and may guide judicious use of rtPA. Although no prospective data have confirmed the value of multimodal imaging for stratification before thrombolysis, caution should be exercised when considering use of rtPA in patients without a large-artery occlusion and a relevant ischaemic penumbra as they may gain little benefit from thrombolytic therapy.

The recommended 'door-to-CT' time (ie from A&E arrival to CT brain interpretation) is 45 minutes.⁸ Multimodal CT offers rapid data acquisition and can

be performed with conventional CT equipment. The short scanning time (6 minutes in our protocol) effectively balances the trade-off between time and diagnostic specificity. The wide access to CT equipment and expertise in regional hospitals also favours use of multimodal CT as a first-line, 'one-stop' evaluation in acute stroke. The disadvantages of multimodal CT are use of iodine contrast and increased radiation. Compared with standard CT, multimodal MR imaging yields high-quality images of the brain. Magnetic resonance diffusion-weighted imaging is also more sensitive for identifying acute infarcts. Nonetheless, the prolonged scanning time needed for MR imaging (20 minutes or more) and the restricted service available in regional hospitals limits use of MR imaging as a frontline assessment tool. In addition, degraded MR images caused by movement artefacts are common in acutely ill stroke patients.

Currently, two types of perfusion CT techniques are available. In whole brain perfusion CT, the ischaemic core is represented by hypoattenuation on cerebral blood volume maps.⁹ This technique has the advantage of whole brain coverage, however, it cannot measure cerebral blood flow or mean transit time. Dynamic perfusion CT, on the other hand, can provide absolute measurements of cerebral blood flow, mean transit time, and cerebral blood volume. Yet, at present, this technique only covers two to four brain slices and visualisation of the pertinent vascular territory requires accurate localisation of the infarct. Both of these perfusion CT techniques are highly sensitive and specific for detecting cerebral ischaemia^{10,11} and may differentiate regions of reversible ischaemia from the infarct core.¹²

Helical CT angiography is feasible on all CT scanners with spiral capability, and can rapidly and non-invasively depict arterial occlusions or stenosis in both the intracranial and extracranial vasculature.^{13,14} It has high diagnostic accuracy for large-vessel intracranial occlusions when compared with ultrasound and digital subtraction angiography.¹⁵ Although CT angiography yields only static images, the haemodynamic or functional status can be inferred using indirect parameters such as visibility of leptomeningeal collaterals. Besides, CT angiography also effectively predicts treatment outcomes and guides further reperfusion therapy. For instance, in an occlusion of the terminal internal carotid artery, a poor early recanalisation rate (<10%) with intravenous rtPA therapy¹⁶ may prompt preparation for rescue intra-arterial thrombolysis.

So far, no prospective study has examined stroke outcomes when multimodal imaging is used for stratification of suitable subjects before thrombolysis. Further study of this nature is warranted. A multimodal CT study can quickly elucidate stroke pathophysiology and may guide judicious use of rtPA.

References

1. Murray CJ, Lopez AD. Global mortality, disability, and the contribution of risk factors: Global Burden of Disease Study. *Lancet* 1997;349:1436-42.
2. Tissue plasminogen activator for acute ischemic stroke. The National Institute of Neurological Disorders and Stroke rt-PA Stroke Study Group. *N Engl J Med* 1995;333:1581-7.
3. Caplan LR, Mohr JP, Kistler JP, Koroshetz W. Should thrombolytic therapy be the first-line treatment for acute ischemic stroke? Thrombolysis—not a panacea for ischemic stroke. *N Engl J Med* 1997;337:1309-13.
4. Adams HP Jr, del Zoppo G, Alberts MJ, et al. Guidelines for the early management of adults with ischemic stroke: a guideline from the American Heart Association/American Stroke Association Stroke Council, Clinical Cardiology Council, Cardiovascular Radiology and Intervention Council, and the Atherosclerotic Peripheral Vascular Disease and Quality of Care Outcomes in Research Interdisciplinary Working Groups: the American Academy of Neurology affirms the value of this guideline as an educational tool for neurologists. *Stroke* 2007;38:1655-711.
5. Mullins ME, Schaefer PW, Sorensen AG, et al. CT and conventional and diffusion-weighted MR imaging in acute stroke: study in 691 patients at presentation to the emergency department. *Radiology* 2002;224:353-60.
6. Adams HP Jr, Brott TG, Furlan AJ, et al. Guidelines for Thrombolytic Therapy for Acute Stroke: a Supplement to the Guidelines for the Management of Patients with Acute Ischemic Stroke. A statement for healthcare professionals from a Special Writing Group of the Stroke Council, American Heart Association. *Stroke* 1996;27:1711-8.
7. Practice advisory: thrombolytic therapy for ischemic stroke—summary statement. Report of the Quality Standards Subcommittee of the American Academy of Neurology. *Neurology* 1996;47:835-9.
8. Alberts MJ, Latchaw RE, Selman WR, et al. Recommendations for comprehensive stroke centers: a consensus statement from the Brain Attack Coalition. *Stroke* 2005;36:1597-616.
9. Ezzeddine MA, Lev MH, McDonald CT, et al. CT angiography with the whole brain perfused blood volume imaging: added clinical value in the assessment of acute stroke. *Stroke* 2002;33:959-66.
10. Kloska SP, Nabavi DG, Gaus C, et al. Acute stroke assessment with CT: do we need multimodal evaluation? *Radiology* 2004;233:79-86.
11. Wintermark M, Fischbein NJ, Smith WS, Ko NU, Quist M, Dillon WP. Accuracy of dynamic perfusion CT with deconvolution in detecting acute hemispheric stroke. *AJNR Am J Neuroradiol* 2005;26:104-12.
12. Klotz E, König M. Perfusion measurements of the brain: using dynamic CT for the quantitative assessment of cerebral ischemia in acute stroke. *Eur J Radiol* 1999;30:170-84.
13. Wintermark M, Reichhart M, Thiran JP, et al. Prognostic accuracy of cerebral blood flow measurement by perfusion computed tomography, at the time of emergency room admission, in acute stroke patients. *Ann Neurol* 2002;51:417-32.
14. Esteban JM, Cervera V. Perfusion CT and angio CT in the assessment of acute stroke. *Neuroradiology* 2004;46:705-15.
15. Verro P, Tanenbaum LN, Borden NM, Sen S, Eshkar N. CT angiography in acute ischemic stroke: preliminary results. *Stroke* 2002;33:276-8.
16. Alexandrov AV. Use of ultrasound in acute stroke. *International Journal of Stroke* 2006;1(Suppl 2):15S.