

Gadolinium-enhanced magnetic resonance angiography in renal artery stenosis: comparison with digital subtraction angiography

YM Law
KH Tay
YU Gan
FK Cheah
BS Tan

Objectives To evaluate the accuracy of gadolinium-enhanced magnetic resonance angiography in assessing renal artery stenosis compared to catheter digital subtraction angiography.

Design Retrospective study.

Setting Singapore General Hospital.

Patients Records of patients who underwent magnetic resonance angiography as well as digital subtraction angiography for assessment of renal artery stenosis from January 2003 to December 2005 were reviewed.

Results There were 27 patients (14 male, 13 female) with a mean age of 62 (range, 44-77) years. There were 10 patients with renal transplants; their native renal arteries were not evaluated. Each of the two experienced interventional and body magnetic resonance radiologists, who were blinded to the results, reviewed the digital subtraction angiography and magnetic resonance angiography images respectively. Digital subtraction angiography was used as the standard of reference. A total of 39 renal arteries from these 27 patients were evaluated. One of the arteries was previously stented and could not be assessed with magnetic resonance angiography due to severe artefacts. Of the remaining 38 renal arteries, two were graded as normal, seven as having mild stenosis (<50%), eight as having moderate stenosis ($\geq 50\%$ but <75%), and 21 as having severe stenosis ($\geq 75\%$). Magnetic resonance angiography and digital subtraction angiography were concordant in 89% of the arteries; magnetic resonance angiography overestimated the degree of stenosis in 8% and underestimated it in 3% of them. In the evaluation of clinically significant renal artery stenosis ($\geq 50\%$) with magnetic resonance angiography, the overall sensitivity, specificity, positive predictive value, and negative predictive value were 97%, 67%, 90%, and 86% respectively. The sensitivity and specificity of magnetic resonance angiography in transplant renal artery stenosis was 100%.

Conclusion Our experience suggested that gadolinium-enhanced magnetic resonance angiography is a sensitive non-invasive modality useful in the assessment of clinically significant renal artery stenosis.

Key words

Angiography, digital subtraction;
Gadolinium; Magnetic resonance
angiography; Renal artery obstruction;
Sensitivity and specificity

Hong Kong Med J 2008;14:136-41

Department of Diagnostic Radiology,
Singapore General Hospital, Outram
Road, Singapore 169608
YM Law, MB, BS, FRCR
KH Tay, MB, BS, FRCR
YU Gan, MB, ChB, FRCR
FK Cheah, MB, ChB, FRCR
BS Tan, MB, BS, FRCR

Correspondence to: Dr YM Law
E-mail: yanmee@hotmail.com,
law.yan.mee@sgh.com.sg

Introduction

Renal artery stenosis (RAS) is a well-recognised cause of hypertension. Renovascular disease is also an uncommon but important cause of progressive renal insufficiency.¹ In renal transplant patients, RAS is also a cause of refractory hypertension and allograft dysfunction.² Repair of RAS has been shown to improve control of hypertension and preserve renal function. This may be achieved via several means such as percutaneous renal artery angioplasty, percutaneous renal artery stenting, or surgical revascularisation.³

Clinicians rely on the history to identify patients at higher risk of RAS as the cause of hypertension. Once patients are identified as being at higher risk of RAS, investigations can be carried out to verify the clinical suspicion. Accurate identification of patients with

correctable renovascular hypertension can be difficult using conventional non-invasive imaging techniques such as doppler ultrasonography and radio-nuclide renography; these provide only indirect evidence of RAS.⁴

Magnetic resonance angiography (MRA), computed tomographic angiography (CTA), and conventional catheter angiography allow direct visualisation of the renal arteries. Computed tomographic angiography and catheter angiography require exposure to ionising radiation. Moreover, for the purpose of screening, conventional angiography is too invasive a procedure to be performed on all patients suspected to have renovascular hypertension. Magnetic resonance angiography is non-invasive and allows direct visualisation of the renal arteries without use of iodinated contrast material or ionising radiation. Several studies have described techniques of non-enhanced and gadolinium-enhanced MRA for evaluating the renal arteries in suspected RAS.^{5,6} We set out to evaluate the reliability of three-dimensional (3D) gadolinium-enhanced MRA performed in our institution as a means of assessing RAS in both native and transplant renal arteries, and compare the results with conventional catheter digital subtraction angiography (DSA).

Methods

This was a retrospective review of patients who underwent MRA and catheter angiography of the renal arteries from January 2003 to December 2005 in our institution. The records were retrieved from our department's radiology information system. The findings in 27 consecutive patients (14 male, 13 female) with a mean age of 62 (range, 44-77) years were analysed. All patients underwent both MRA and DSA. A total of 39 renal arteries, which were adequately imaged, were evaluated. There were 10 patients with renal transplants; their native renal arteries were not evaluated. Our Institutional Review Board approved the conduct of this study.

Magnetic resonance angiography of the renal arteries was performed using 1.5T MR systems (Magnetom Vision [January 2003-September 2004] and Magnetom Avanto [September 2004 to December 2005]; Siemens Medical Solutions, Erlangen, Germany). An anteroposterior phased-array surface coil (torso array coil) was used. We used sagittal, coronal, and axial localising pulse sequences, followed by image acquisition in the coronal plane. FLASH 3D gradient echo sequence was employed. The following imaging parameters were used: repetition time 3.22 ms; echo time 1.16 ms; flip angle 25°; field of view 400 mm; matrix size 256 x 512; slice thickness 1.2 mm. The volume was centred at the level of the native renal arteries or transplant renal arteries.

For gadolinium administration, an intravenous

釷顯影劑增強的磁共振血管造影在腎動脈狹窄診治中的作用：與數字減影血管造影的比較

- 目的** 比較在診斷腎動脈狹窄時，釷顯影劑增強的磁共振血管造影與導管數字減影血管造影的準確程度。
- 設計** 回顧研究。
- 安排** 新加坡中央醫院。
- 患者** 檢視曾接受釷顯影劑增強的磁共振血管造影或導管數字減影血管造影以診斷腎動脈狹窄的病人的病歷。
- 結果** 27位病人（14男、13女）的平均年齡為62歲（介乎44至77歲）。其中10位曾接受腎臟移植，其自體腎動脈無法評估。兩位富經驗、分別為介入性和身體性放射科醫生在不知結果的情況下，以數字減影血管造影為參考標準，各自檢視釷顯影劑增強的磁共振血管造影與數字減影血管造影的影像。兩人共檢視了27位病人的39個腎動脈影像。其中一條腎動脈曾接受支架治療，但因大部分屬人工製品，結果無法以磁共振血管造影評估。餘下38個腎動脈影像，兩個獲評級為正常，7個屬輕度狹窄（<50%），8個中度狹窄（≥50%但<75%），21個嚴重狹窄（≥75%）。在89%腎動脈影像中，兩種技術所得結果一致。在8%中磁共振血管造影高估了狹窄的程度，在3%中則低估了狹窄的程度。在利用磁共振血管造影評估具臨床意義的腎動脈狹窄中（≥50%），整體的敏感度、特異度、陽性預測值、陰性預測值按序分別為97%、67%、90%和86%，而在評估移植腎動脈狹窄中應用磁共振血管造影的敏感度和特異度同為100%。
- 結論** 釷顯影劑增強的磁共振血管造影是一種敏感而不具侵入性的方式，對評估具臨床意義的腎動脈狹窄具有價值。

cannula was placed in an antecubital arm vein and connected to a long extension tubing. We used approximately 20-25 mL (0.2 mmol/kg) of gadodiamide (Omniscan 0.5 mmol/mL; Amersham Health, Cork, Ireland). The contrast material was injected with an automatic injector (Medrad, Pittsburgh, PA) at 2 mL/sec, followed by a 20 mL saline flush. All patients were required to hold their breath during image acquisition. Image reconstruction was performed using both maximal intensity projection (MIP) and reformatting techniques.

Catheter angiography was performed through a femoral artery puncture using a modified Seldinger technique. A Flush Aortogram was performed with 30 mL of Omnipaque 350 at 15 mL/sec or with CO₂ via a 5-Fr angiographic catheter. All images were obtained using DSA. Routine anterior-posterior projections were obtained. Additional selective studies were performed by selective catheterization of the renal arteries with a 5-Fr angiographic catheter.

The DSA images were reviewed by an

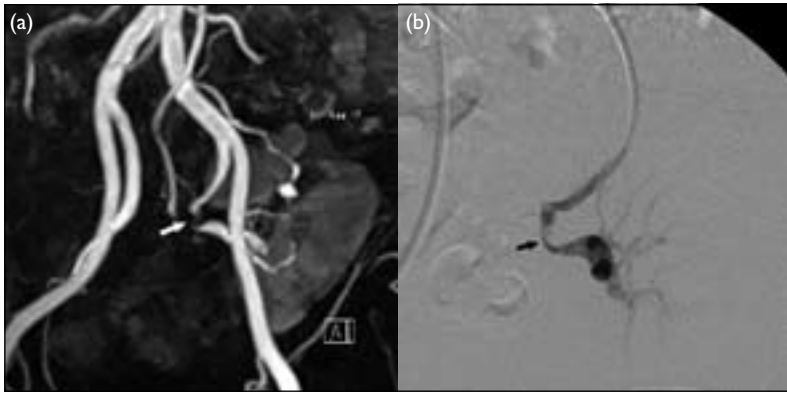


FIG 1. (a) Magnetic resonance angiography of transplant renal artery showing severe stenosis at the mid segment (white arrow); (b) corresponding digital subtraction angiography confirming the severe stenosis (black arrow)

TABLE 1. Sensitivity, specificity, as well as positive and negative predictive values for the detection of significant renal artery stenosis

Magnetic resonance angiography	Digital subtraction angiography		%
	Significant	Not significant	
Significant	28	3	90
Not significant	1	6	86
%	97	67	-

interventional radiologist blinded to the MRA images, and the MRA images were reviewed by a body magnetic resonance radiologist blinded to the DSA images. Digital subtraction angiography was used as the standard of reference. Images were analysed for the number of renal arteries present and the presence or absence of stenosis. The stenoses were graded by visual inspection. The obstructive lesions were assessed according to the most severe reduction of arterial diameter and compared with the most normal-appearing segment proximal or distal to the area of stenosis as: mild (<50%), moderate (≥50% but <75%), and severe (≥75%). The sensitivity, specificity, positive and negative predictive values were then calculated.

Results

Magnetic resonance angiography demonstrated all 44 vessels in the 27 patients; 34 were native renal arteries and 10 were transplant renal arteries. Unfortunately, one of the renal arteries was previously stented and could not be assessed for stenosis using MRA due to severe artefacts. Conventional catheter angiography demonstrated 39 renal arteries. Five renal arteries were not selectively cannulated on catheter angiography and could not be optimally assessed. The latter were therefore excluded from the study, making a total of 39 renal arteries from 27 patients.

Clinically significant stenosis was defined as

≥50% stenosis. Patients with normal vessels or mild stenosis (<50% maximal stenosis) generally do not require radiological or surgical intervention, whereas those with clinically significant stenosis (≥50% maximal stenosis) may be appropriate candidates for intervention. Therefore, the analysis of these patients was based on whether they had clinically significant disease.

Among the 38 renal arteries evaluated with gadolinium-enhanced MRA, seven had mild stenosis (<50%), 10 had moderate stenosis (≥50% but <75%), and 21 had severe stenosis (≥75%). As such, 31 of the demonstrated renal arteries were deemed to have clinically significant renal artery stenoses according to MRA.

Conventional catheter angiography demonstrated 39 renal arteries; 38 arteries had MRA correlation (1 stented artery was excluded from MRA). Among the 38 renal arteries with MRA correlation, two arteries were normal, seven had mild stenosis (<50%), eight had moderate stenosis (≥50% but <75%), and 21 had severe stenosis (≥75%). Thus, 29 renal arteries were evaluated to have clinically significant stenosis on DSA. Severe stenosis within the stent was detected in the stented renal artery.

The results were analysed; MRA findings were compared with DSA results as the standard of reference. Among the 29 renal arteries with clinically significant stenoses noted on DSA, 28 were also demonstrated by MRA, which therefore yielded 28 true-positive and one false-negative results. Among the nine renal arteries without clinically significant RAS on DSA, MRA was concordant in six of the arteries. There were therefore six true-negative and three false-positive results, based on MRA. The two techniques—MRA and DSA—were concordant in 89% of instances; MRA overestimated the degree of stenosis in 8% and underestimated it in 3% of the arteries.

Among the 10 transplant renal arteries assessed with both MRA and DSA for the presence of clinically significant RAS, MRA results yielded seven true positives and three true negatives; there being no false positives or false negatives. The sensitivity and specificity of gadolinium-enhanced MRA in evaluating clinically significant RAS (≥50%) in transplant renal arteries in our series was therefore 100% (Fig 1).

The overall sensitivity and specificity of gadolinium-enhanced MRA in evaluating clinically significant RAS in our series were 97% and 67% respectively. The positive predictive value was 90% and the negative predictive value was 86% (Table 1).

Discussion

Renovascular hypertension is a relatively uncommon but important cause of refractory hypertension.

In patients with renal transplants, if not identified, transplant RAS leads to loss of the precious allograft. Once RAS is diagnosed, percutaneous transluminal angioplasty and stent placement is an alternative therapeutic option to standard medical therapy.⁷ Catheter angiography is the gold standard for diagnosing RAS, but is invasive and the patient is exposed to ionising radiation.⁸

Magnetic resonance angiography assessment of RAS has been performed using different sequences, including phase-contrast and time-of-flight sequences.⁹ However, the latter sequences suffer from poorer resolution and flow-related artefacts. Studies from De Cobelli et al¹⁰ and Loubeyre et al¹¹ showed that although phase-contrast MRA images may produce impressive images, there are numerous problems including long acquisition time and an unacceptable rate of inconclusive studies.

This problem is minimised by the use of gadolinium-enhanced gradient-echo pulse sequences that derive signal from the T1-shortening effect of gadolinium and is independent of blood flow dynamics.¹² In studies by Johnson et al¹³ and the meta-analysis by Tan et al,⁹ gadolinium-enhanced MRA significantly increases the sensitivity and specificity of detecting RAS, as compared to non-enhanced MRA techniques.

Gadolinium-enhanced breath-hold MRA has been described for renal artery imaging and has resulted in significantly improved signal-to-noise and contrast-to-noise ratios.¹² In our study, MRA diagnosed 28 of 29 clinically significant ($\geq 50\%$) renal artery stenoses, with a sensitivity of 97%, and compares favourably with similar studies by Bakker et al¹⁴ and Thornton et al,¹⁵ who reported sensitivities of 97% and 100% respectively. Similarly, our results were also concordant with the meta-analysis by Tan et al,⁹ who reported a sensitivity of 97% for gadolinium-enhanced MRA (Table 2).

In the assessment of clinically significant transplant RAS, our study reported excellent sensitivity and specificity; 100% among the 10 transplant renal arteries we assessed. Thus, our results compared favourably with published studies by Johnson et al¹³ and Luk et al,¹⁶ who reported sensitivities of 67% and 88% and specificities of 88% and 100% respectively, for gadolinium-enhanced MRA used to detect transplant RAS.

In our series, MRA made three false-positive diagnoses of clinically significant RAS in three patients. Two of these were graded as moderate stenosis according to MRA with approximately 50% stenosis, but were shown on DSA to have only mild stenosis (about 40%). The discrepancy in assessment of stenosis of these two vessels by MRA and DSA was approximately 10%. The remaining patient with a false-positive stenosis was clearly identified as moderately

TABLE 2. Comparison of the results of the present study with other published studies

Studies	No. of renal arteries studied	Sensitivity	Specificity
De Cobelli et al ¹⁰	105	100%	97%
Thornton et al ¹⁵	85	100%	98%
Bakker et al ¹⁴	83	97%	92%
Tan et al ⁹	993	97%	93%
The present study (overall)	38	97%	67%
Johnson et al ^{13*}	11	67%	88%
Luk et al ^{16*}	9	88%	100%
The present study (transplant)	10	100%	100%

* These studies consisted of only transplant renal arteries

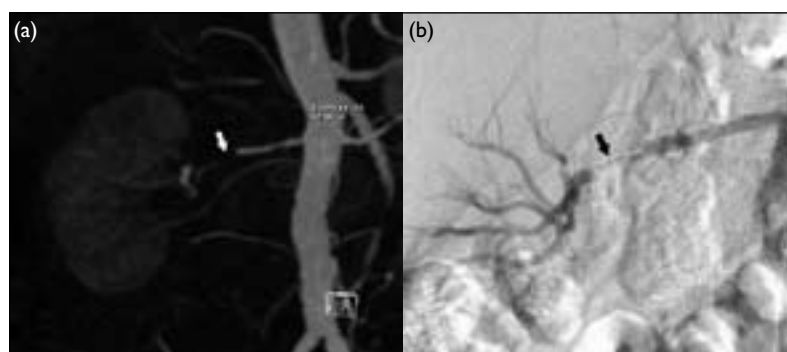


FIG 2. (a) Magnetic resonance angiography of stented renal artery demonstrating susceptibility artefacts at the stented segment (white arrow); (b) corresponding digital subtraction angiography showing severe stenosis within the stent (black arrow)

severe by MRA but had mild stenosis only (30%) by DSA. We were unable to explain this discordance.

One stented renal artery was excluded from the analysis as presence of an endovascular stent made it impossible to evaluate the MRA, owing to susceptibility artefacts from the stent. Catheter angiography performed on this vessel demonstrated severe stenosis within the stent (Fig 2). This patient subsequently underwent angioplasty of the affected segment. In previously stented vessels, DSA, therefore, remains superior to MRA. While new stent designs may eventually overcome this limitation, at present they are not routinely used.

There was a high prevalence (76%) for significant RAS in our study cohort, which had already been screened. In our institution, all patients with clinical suspicion of renovascular hypertension are screened by doppler sonography. Patients with positive findings on doppler sonography are then referred for further imaging with CTA or MRA to assess for RAS. Patients with a high clinical suspicion of RAS but who have equivocal findings on doppler sonography are also further investigated with CTA or MRA.

Our MRA images were acquired in the coronal plane with breath-hold technique. Breath holding

allows visualisation of a greater length of the renal artery as compared to non-breath holding, which only allows visualisation of the proximal 33% of the renal artery.^{12,15} In our study, we were able to see the renal arteries as far as the renal hilar areas. The intraparenchymal branches were not seen reliably, which is more likely a limitation of spatial resolution rather than motion artefacts. Among our study subjects, no fibromuscular dysplasia was detected by MRA or DSA. The limitations of MRA in assessing RAS in fibromuscular dysplasia are well established. They relate to the distal involvement of renal arteries and the intrarenal branches, and consequential limitations in spatial resolution, parenchymal overlay, and motion artefacts in the distal branches of the renal artery.

Magnetic resonance angiography is a non-invasive and accurate diagnostic method for suspected renovascular hypertension in native and transplant renal arteries. The multi-planar capability of MRA allows the radiologists to orientate the renal vessels in a plane most optimal for visualisation, especially in transplant renal vessels. The 3D MIP and volume-rendered technique post-processing allow projection in almost any plane, which has important implications in both diagnostic and interventional procedures in renal transplant patients as transplant kidneys may have variable orientations. In our institution, the morphology and orientation of the transplanted kidney and vessels shown on MRA are used as references for planning the approach during interventional procedures. In MRA, the renal vein is routinely demonstrated, potentially allowing the presence of renal vein stenosis or occlusion to be detected. Additional information about the morphology of the kidneys (such as allograft infarction) can also be provided by MRA.

Although MRA has high sensitivity, it has an inherent tendency to overestimate the severity of stenosis. In our series, it overestimated the degree of RAS by 8%. Although this leads to unnecessary catheter angiography, it should be stressed that MRA is only a screening tool to identify potentially treatable hypertension, in which specificity is therefore secondary to sensitivity.

Recent technical developments in MRA have resulted in increased accuracy for the detection of RAS by combining conventional 3D gadolinium-enhanced MRA with functional magnetic resonance imaging (MRI) studies, such as 3D phase-contrast MRA (PC MRA) and magnetic resonance renography. Not only does this combined MRA protocol provide important information on the morphology and location of the stenosis, it also allows estimation of its haemodynamic severity.¹⁷ The presence of turbulent flow in severe stenosis can be measured on PC MRA. A recent tricentre study has shown the synergistic

value of a combined morphologic and functional grading of RAS by combining 3D contrast-enhanced MRA and phase-contrast flow measurements.¹⁸ Magnetic resonance renography, which is being intensively evaluated at the moment, makes use of the combined administration of gadolinium chelates and an angiotensin-converting enzyme inhibitor such as captopril, to provide information on glomerular filtration. In the presence of significant RAS, there is decreased filtration and increased accumulation of contrast in the kidneys, which can then be visualised by 3D gradient echo imaging. In stented vessels, the use of functional MRI studies proximal and distal to the stent has the potential to overcome the limitations of MRA in assessing patency of stented vessels.

We recognise several limitations in our series. We did not precisely measure each stenosis, rather, we used subjective assessment to identify and quantify RAS. Such subjective assessment was also used by De Cobelli et al¹⁰ and several other groups and we believe it more accurately reflects day-to-day practice.¹⁵

Although we graded the stenoses into those <50%, ≥50 but <75%, and ≥75%, analysis of the results was based on the presence of clinically significant stenoses. This is a common and accepted method of grading vascular stenosis described in published literature.^{19,20} We believe that identifying clinically significant RAS (≥50%) more accurately reflects day-to-day practice, as catheter angiography will always be warranted for further evaluation and intervention in such patients. Our small sample size was also a limitation, resulting in our reported specificity of 67%. In patients with renal impairment, gadolinium has to be used with caution; recent reports have strongly correlated the development of nephrogenic systemic fibrosis after exposure to gadolinium-containing MRI contrast agents.²¹

In conclusion, gadolinium-enhanced MRA is a technique of choice in assessing RAS due to its high sensitivity, especially in assessing transplant RAS. It allows direct visualisation of the renal arteries without ionising radiation. This reduces the number of potentially harmful, invasive procedures. With developments in techniques, contrast-enhanced MRA not only allows accurate assessment of the vascular anatomy, it also has the potential of providing important haemodynamic flow information, which is less operator-dependent than doppler sonography. In the imaging of renal transplants, MRI allows a comprehensive examination of the entire transplant, including the arterial and venous systems, parenchyma and the peritransplant region in a single study, without the use of iodinated contrast. Patients evaluated to have clinically significant RAS on MRA may then proceed to catheter angiography with a view to a therapeutic intervention.

References

1. Dean RH. Renovascular hypertension: an overview. In: Rutherford RB, editor. *Vascular surgery*. 3rd ed. Philadelphia: Saunders; 1989:1211-8.
2. Gedroyc WM, Reidy JF, Saxton HM. Arteriography of renal transplantation. *Clin Radiol* 1987;38:239-43.
3. Weibull H, Bergqvist D, Bergentz SE, Jonsson K, Hulthén L, Manhem P. Percutaneous transluminal renal angioplasty versus surgical reconstruction of atherosclerotic renal artery stenosis: a prospective randomized study. *J Vasc Surg* 1993;18:841-52.
4. Bude RO, Rubin JM. Detection of renal artery stenosis with Doppler sonography: it is more complicated than originally thought. *Radiology* 1995;196:612-3.
5. Prince MR. Gadolinium-enhanced MR aortography. *Radiology* 1994;191:155-64.
6. Hany TF, Debatin JF, Leung DA, Pfammatter T. Evaluation of the aortoiliac and renal arteries: comparison of the breath-hold, contrast-enhanced, three-dimensional MR angiography with conventional catheter angiography. *Radiology* 1997;204:357-62.
7. Rodriguez-Lopez JA, Werner A, Ray LI, et al. Renal artery stenosis treated with stent deployment: indications, technique, and outcome for 108 patients. *J Vasc Surg* 1999;29:617-24.
8. Waugh JR, Sacharias N. Arteriographic complications in the DSA era. *Radiology* 1992;182:243-6.
9. Tan KT, van Beek EJ, Brown PW, van Delden OM, Tijssen J, Ramsay LE. Magnetic resonance angiography for the diagnosis of renal artery stenosis: a meta-analysis. *Clin Radiol* 2002;57:617-24.
10. De Cobelli F, Vanzulli A, Sironi S, et al. Renal artery stenosis: evaluation with breath-hold, three-dimensional, dynamic, gadolinium-enhanced versus three-dimensional, phase-contrast MR angiography. *Radiology* 1997;205:689-95.
11. Loubeyre P, Trolliet P, Cahen R, Grozel F, Labeeuw M, Minh VA. MR angiography of renal artery stenosis: value of the combination of three-dimensional time-of-flight and three-dimensional phase-contrast MR angiography sequences. *AJR Am J Roentgenol* 1996;167:489-94.
12. Thornton J, O'Callaghan, Walshe J, O'Brien E, Varghese JC, Lee MJ. Comparison of digital subtraction angiography with gadolinium-enhanced magnetic resonance angiography in the diagnosis of renal artery stenosis. *Eur Radiol* 1999;9:930-4.
13. Johnson DB, Lerner CA, Prince MR, et al. Gadolinium-enhanced magnetic resonance angiography of renal transplants. *Magn Reson Imaging* 1997;15:13-20.
14. Bakker J, Beek FJ, Beutler JJ, et al. Renal artery stenosis and accessory renal arteries: accuracy of detection and visualisation with gadolinium-enhanced breath-hold MR angiography. *Radiology* 1998;207:497-504.
15. Thornton MJ, Thornton F, O'Callaghan J, et al. Evaluation of dynamic gadolinium-enhanced breath-hold MR angiography in the diagnosis of renal artery stenosis. *AJR Am J Roentgenol* 1999;173:1279-83.
16. Luk SH, Chan JH, Kwan TH, Tsui WC, Cheung YK, Yuen MK. Breath-hold 3D gadolinium-enhanced subtraction MRA in the detection of transplant renal artery stenosis. *Clin Radiol* 1999;54:651-4.
17. Schoenberg SO, Rieger JR, Michaely HJ, Rupprecht H, Samtleben W, Reiser MF. Functional magnetic resonance imaging in renal artery stenosis. *Abdom Imaging* 2006;31:200-12.
18. Schoenberg SO, Knopp MV, Londy F, et al. Morphologic and functional magnetic resonance imaging of renal artery stenosis: a multireader tricenter study. *J Am Soc Nephrol* 2002;13:158-69.
19. Fain FB, King BF, Breen JF, Kruger DG, Riederer SJ. High-spatial-resolution contrast-enhanced MR angiography of the renal arteries: a prospective comparison with digital subtraction angiography. *Radiology* 2001;218:481-90.
20. Korst MB, Joosten FB, Postma CT, Jager GJ, Krabbe JK, Barentsz JO. Accuracy of normal-dose contrast-enhanced MR angiography in assessing renal artery stenosis and accessory renal arteries. *AJR Am J Roentgenol* 2000;174:629-34.
21. Public health advisory on gadolinium containing contrast agents for magnetic resonance imaging (MRI). FDA website: http://www.fda.gov/cder/drug/advisory/gadolinium_agents.htm. Accessed Jun 05.