

Late-onset postpartum eclampsia: still a diagnostic dilemma?

VM Santos

FG Corrêa

FRD Modesto

PR Moutella

Eclampsia is still a major cause of perinatal morbidity and mortality in developing countries but postpartum eclampsia has rarely been described. We present a case in which a 22-year-old Brazilian woman without a typical history of pre-eclampsia presented with eclampsia after the fourth postpartum day. The clinical diagnosis was corroborated by angiography and magnetic resonance imaging of the brain. The findings of nine similar cases reported in the literature are reviewed to compare data and highlight possible diagnostic pitfalls when managing this condition.

Introduction

Although prenatal care has significantly reduced the rate of eclampsia in western countries, it remains a major cause of maternal and foetal death.¹ Pre-eclampsia is the new onset of arterial hypertension ($\geq 140/90$ mm Hg) and proteinuria after 20 weeks of pregnancy, and eclampsia is the occurrence of convulsions in women with clinical evidence of pre-eclampsia.

In late postpartum eclampsia (LPE) the onset of convulsions occurs more than 48 hours, but less than 4 weeks, after delivery.^{2,3} Late postpartum eclampsia may occur without any pre-eclamptic prodromes, including proteinuria⁴⁻⁸; however, adequate evaluation and reporting of pre-eclamptic symptoms, such as headaches and visual changes, can lower the number of pregnancy-related deaths.⁹ The delayed onset and the atypical presentation may lead to misdiagnosis in LPE. Lack of caretaker attention can constitute another serious, but potentially reversible obstacle to the characterisation of the impending eclampsia.

Very often, the differential diagnosis of seizure-related puerperal conditions must involve early medical, neurological, and central nervous system (CNS) imaging evaluation.

Case report

On 24 September 2005, a 22-year-old healthy Brazilian woman (gravida 2, para 2) had a vaginal delivery, at 37 weeks of pregnancy, of an infant that died of respiratory complications. Her obstetric history, including her previous pregnancy 2 years before, was unremarkable and neither proteinuria nor arterial hypertension was detected. Her family history was also unremarkable. Her postpartum course was uneventful and she had no oedema, proteinuria, or hypertension until the fourth day when she developed severe occipital and frontal headaches and blurred vision. On the next day, she was managed in another hospital for a generalised tonic-clonic seizure and had two similar seizures, treated with 10 mg of diazepam intravenously before being transferred to our emergency department. On admission, the patient's body mass index was normal, Glasgow Coma Scale score was 15, blood pressure 160/90 mm Hg, pulse 66 beats/min, respiratory rate 20 breaths/min, and temperature 37°C (98.6°F). Her neck was supple and non-tender, and her pupils were equal and reactive to light. Cardiovascular, respiratory, and abdominal examinations revealed no abnormalities. The ophthalmologic examination and laboratory results, including a urinalysis, complete blood count, serum electrolytes, liver function tests, coagulation profile and cerebrospinal fluid (CSF) examination, were normal. The fluid-attenuated inversion recovery images of the magnetic resonance imaging showed small foci of high signal intensity in the cortical and sub-cortical white matter bilaterally, mainly in the parieto-occipital and frontal regions (Fig a), with a normal venous system. Digital angiography (Fig b) only revealed small and diffuse cerebral vascular lesions giving a 'rosary bead' appearance, predominantly in the distal vessels. The patient was admitted to the internal medicine service and remained stable, with a high blood pressure (170/110 mm Hg), which was successfully controlled with a short course of hydrochlorothiazide and captopril, but did not require long-term antihypertensive drugs. She had no further seizure activity and was discharged home without further neurological sequelae.

Key words

Cerebrovascular disorders; Eclampsia;
Magnetic resonance imaging; Postpartum
period; Pregnancy

Hong Kong Med J 2008;14:60-3

Department of Internal Medicine, Armed
Forces Hospital, Brasília-DF
VM Santos, MD, PhD
FG Corrêa, MD
PR Moutella, MD
Brazilian Federation of Gynecology and
Obstetrics
FRD Modesto, MD

Correspondence to: Dr VM Santos
E-mail: vitorinomodesto@gmail.com

遲發型產後子癇仍然是診斷的難題？

在發展中國家，子癇仍然是圍產期發病和致死的主要原因，但產後子癇卻少有聽聞。本病例報告描述一位22歲巴西女性產後第四天出現子癇，她過往並無先兆子癇的發病紀錄。我們利用血管造影和腦部磁力共振成像來確定臨床診斷結果。報告又比較文獻有記載的九個類同病例的數據，並指出在處理這種情況時可能出現的錯誤診斷。

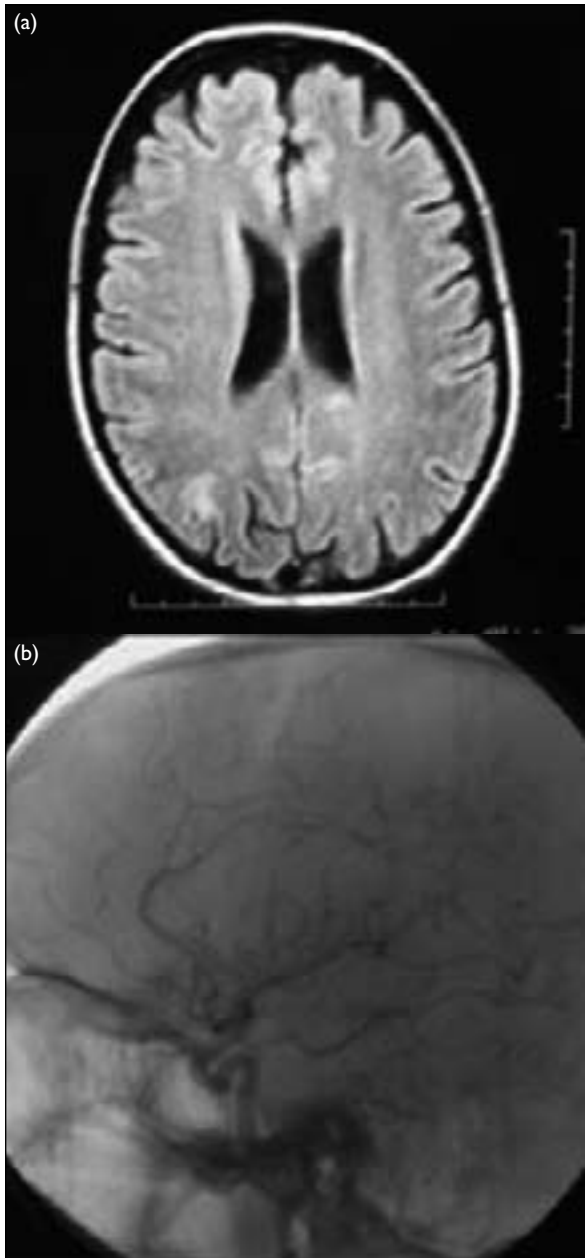


FIG. (a) Magnetic resonance image showing small foci of high signal intensity in the cortical and subcortical white matter bilaterally, mainly in the parieto-occipital and frontal regions. (b) Digital brain angiography showing small rosary bead-like changes

weeks with a median of 38.5 (range, 37-41) weeks. Four (40%) patients were delivered by caesarean section. One of the 10 live born infants died of respiratory failure. There was no maternal mortality. The mean postpartum day of eclampsia onset was 7.6 (SD, 2.2) and median 8.5 (range, 4-11). None of the patients presented with typical pre-eclamptic prodromes. Headache was the commonest symptom (90%) of impending eclampsia, and one patient had backache associated with Guillain-Barré syndrome.⁵ Minor or major visual changes (scotomata, blurred vision, or blindness) were present in 60% of the cases. Samples of CSF were obtained in seven of the cases, and in four (57%) of them the cell count and protein levels were elevated. Magnetic resonance imaging disclosed cerebral changes in 6/10 (60%) of the patients, while computed tomography and arteriography showed abnormalities in 2/6 (33%) of the cases. Occipital and parietal CNS changes were found in 7/7 and 6/7 (100% and 86%, respectively) of the cases; and frontal 3/7 (43%), cerebellar 2/7 (29%), and temporal 1/7 (14%) changes were less frequent findings (Table).

In our patient, the LPE occurred in the fourth day, and was not heralded by a typical pre-eclamptic prodrome. The laboratory tests, including CSF data, were unremarkable. On the imaging study, the CNS changes were more prominent in the parieto-occipital regions and the subcortical white matter, while the angiography study revealed a classical rosary bead-like appearance, which is indicative of diffuse cerebral vasospasm.^{3,10,11} Reversible posterior leukoencephalopathy syndrome has been associated with LPE^{12,13}; however, this condition could not be characterised on diffusion-weighted imaging and a diffusion coefficient map in this patient.

Initially, we focused on conditions that may cause headache, visual changes, and late postpartum seizures that could mimic LPE.² Differential diagnoses of postpartum headache and visual changes followed by convulsions include: drug withdrawal, encephalitis and meningitis, epilepsy, metabolic disturbances, space-occupying lesions, vasculitis, venous thrombosis and stroke,¹⁴ and side-effects of epidural analgesia.¹⁵ Epidural analgesia may contribute to the diagnostic dilemma, if followed by early or late postpartum seizures, headache, and visual changes.¹⁵

Discussion

We performed a retrospective analysis of the clinical, laboratory, and imaging findings from nine similar reports published in the last 6 years,^{4,8} and included the present case in our analysis. The patients' mean age was 27.2 (standard deviation [SD], 5.5; median, 28; range, 18-38) years. Four (40%) of the patients were nulliparous. Three women had a history of abortions and, in a sole case, pre-eclampsia had occurred during a previous pregnancy. Gestational age was reported in six of the cases, giving a mean age of 38.6 (SD, 1.3)

TABLE. Comparative data from 10 patients with late postpartum eclampsia (LPE)*

Author, year	Age (years)	Gestation	Parity	History	Prodrome	LPE date	Partum†
Veltkamp et al, ⁴ 2000	28	41 weeks	G4P2A2	Abortions (n=2)	None	Day 9	Normal
Veltkamp et al, ⁴ 2000	38	No data	G1P1A0	Unremarkable	None	Day 9	Surgical
Dziewas et al, ⁵ 2002	18	39 weeks	G1P1A0	Unremarkable	None	Day 6	Normal
Dziewas et al, ⁵ 2002	22	38 weeks	G2P2A0	Unremarkable	None	Day 8	Surgical
Dziewas et al, ⁵ 2002	30	39 weeks	G1P1A0	Unremarkable	None	Day 11	Surgical
Martin and Sidman, ⁶ 2003	31	No data	G6P3A3	Abortions (n=3)	None	Day 9	Normal
Martin and Sidman, ⁶ 2003	28	No data	G5P3A2	Abortions (n=2)	None	Day 5	Normal
Mathew et al, ⁷ 2003	28	No data	G1P1A0	Unremarkable	None	Day 6	Normal
Munjuluri et al, ⁸ 2005	27	38 weeks	G2P2A0	Pre-eclampsia	None	Day 9	Surgical
Santos et al, 2008 (present case)	22	37 weeks	G2P2A0	Unremarkable	None	Day 4	Normal

* CNS denotes central nervous system, CSF cerebrospinal fluid, and MRI magnetic resonance imaging

† Surgical: caesarean

It may be difficult to establish the origin of postpartum seizures in cases with or without evidence of antepartum or postpartum pre-eclampsia. It is noteworthy that among 151 patients presenting with delayed postpartum pre-eclampsia, 24 (16%) developed eclampsia.¹⁶

Cerebrovascular disorders (aneurysms, arteriovenous malformations, infarctions, and haemorrhages) occurring during the postpartum period may constitute pitfalls in the diagnosis of LPE¹⁷; however, we did not see evidence of any of these conditions on the computed tomography with and without contrast, nor with the magnetic resonance imaging and angiography studies, and the investigations for a thrombophilic state were unremarkable.

Our patient had not been given any type of analgesia, and the medical, neurological, laboratory, imaging, and follow-up evaluations failed to find any other aetiology for her seizures, making LPE the most likely diagnosis. Nevertheless, another possible

concern could be spontaneous postpartum cerebral angiopathy, because there is an overlap between this condition and LPE.¹⁸

This report aims to highlight underreporting of LPE due to misdiagnosis. It is worth noting that a review of 23 cases of LPE found that six patients sought care for symptoms of typical pre-eclampsia, but the diagnosis was missed by those physicians managing them.⁹ Nonetheless, LPE is difficult to prevent in the absence of a typical prodrome. Despite being considered a rare event, its incidence is increasing.^{14,19} Although delivery is usually the ultimate measure in the management of patients with pre-eclampsia, it does not eliminate the possibility of this serious complication.¹⁶

The occurrence of LPE without typical pre-eclampsia emphasises the need to be aware of the possibility of this diagnosis, even in a pregnant patient with no hypertension or proteinuria,²⁰ when headaches and/or visual changes develop during the postpartum period.

References

- Kaplan PW. Neurologic aspects of eclampsia. *Neurol Clin* 2004;22:841-61.
- Lubarsky SL, Barton JR, Friedman SA, Nasreddine S, Ramadan MK, Sibai BM. Late postpartum eclampsia revisited. *Obstet Gynecol* 1994;83:502-5.
- Felz MW, Barnes DB, Figueroa RE. Late postpartum eclampsia 16 days after delivery: case report with clinical, radiologic, and pathophysiologic correlations. *J Am Board Fam Pract* 2000;13:39-46.
- Veltkamp R, Kupsch A, Polasek J, Yousry TA, Pfister HW. Late onset postpartum eclampsia without pre-eclamptic prodromi: clinical and neuroradiological presentation in two patients. *J Neurol Neurosurg Psychiatry* 2000;69:824-7.
- Dziewas R, Stögbauer F, Freund M, et al. Late onset postpartum eclampsia: a rare and difficult diagnosis. *J Neurol* 2002;249:1287-91.
- Martin J, Sidman R. Late postpartum eclampsia: a common presentation of an uncommon diagnosis. *J Emerg Med* 2003;25:387-90.
- Mathew R, Raj RS, Sudha P. Late postpartum eclampsia without prodroma. *Neurol India* 2003;51:539-40.
- Munjuluri N, Lipman M, Valentine A, Hardman P, Maclean AB. Postpartum eclampsia of late onset. *BMJ* 2005;331:1070-1.
- Chames MC, Livingston JC, Ivester TS, Barton JR, Sibai BM.

Pain	Visual changes	CSF changes (with abnormalities)	CNS changes	MRI	Angiography
Head	Yes	↑ cells ↑ protein	Frontal, temporal, parietal, occipital	Change	Change
Head	Yes	↑ cells ↑ protein	Frontal, parietal, occipital, cerebellar	Change	Normal
Head	No	↑ cells ↑ protein	Parietal, occipital, cerebellar	Normal	Normal
None	Yes	No data	Occipital	Change	Normal
Back	No	↑ cells ↑ protein	Parietal, occipital (Guillain-Barré syndrome)	Change	Normal
Head	No	Normal	No data	Normal	No data
Head	No	Normal	No data	Normal	No data
Head	Yes	No data	No data	Normal	No data
Head	Yes	No data	Parietal, occipital	Change	No data
Head	Yes	Normal	Frontal, parietal	Change	Change

Late postpartum eclampsia: a preventable disease? *Am J Obst Gynecol* 2002;186:1174-7.

10. Raps EC, Galetta SL, Broderick M, Atlas SW. Delayed peripartum vasculopathy: cerebral eclampsia revisited. *Ann Neurol* 1993;33:222-5.

11. Bartynski WS, Sanghvi A. Neuroimaging of delayed eclampsia. Report of 3 cases and review of the literature. *J Comput Assist Tomogr* 2003;27:699-713.

12. Na SJ, Hong JM, Park JH, Chung TS, Lee KY. A case of reversible postpartum cytotoxic edema in preeclampsia. *J Neurol Sci* 2004;221:83-7.

13. Pizon AF, Wolfson AB. Postpartum focal neurologic deficits: posterior leukoencephalopathy syndrome. *J Emerg Med* 2005;29:163-6.

14. Sibai BM. Diagnosis, prevention, and management of eclampsia. *Obstet Gynecol* 2005;105:402-10.

15. Akerman N, Hall W. A case of late postpartum seizures after epidural analgesia. *Int J Obstet Anesth* 2005;14:163-6.

16. Matthys LA, Coppage KH, Lambers DS, Barton JR, Sibai BM. Delayed postpartum preeclampsia: an experience of 151 cases. *Am J Obstet Gynecol* 2004;190:1464-6.

17. Witlin AG, Mattar F, Sibai BM. Postpartum stroke: a twenty-year experience. *Am J Obstet Gynecol* 2000;183:83-8.

18. Williams TL, Lukovits TG, Harris BT, Harker Rhodes C. A fatal case of postpartum cerebral angiopathy with literature review. *Arch Gynecol Obstet* 2007;275:67-77.

19. Graeber B, Vanderwal T, Stiller RJ, Werdmann MJ. Late postpartum eclampsia as an obstetric complication seen in the ED. *Am J Emerg Med* 2005;23:168-70.

20. Stella CL, Sibai BM. Preeclampsia: diagnosis and management of the atypical presentation. *J Matern Fetal Neonatal Med* 2006;19:381-6.