

# Perforation of the gall bladder following typhoid fever—induced ileal perforation

Vaibhav Saxena  
Somprakas Basu  
CLN Sharma

Gall bladder perforation is a potentially life-threatening condition. Spontaneous perforation is infrequent and rarely seen in the absence of gallstones but gall bladder perforation is an occasional complication of typhoid fever. If such perforations are not treated in time, mortality rates are very high. We report a case of gall bladder perforation complicating typhoid fever following enteric perforation of the ileum necessitating sequential laparotomies during the same admission.

## Introduction

Gall bladder perforation is an uncommon but dreaded complication. Spontaneous perforation in calculus cholecystitis is infrequent and even rarer in the absence of gallstones, but occasionally occurs following typhoid fever.<sup>1</sup> Surgical complications of typhoid fever more commonly involve the gut than the gall bladder and are commoner than those of paratyphoid fever.<sup>2</sup> When the two complications co-exist, the morbidity and mortality rates rise steeply, especially if they are not detected and treated in time. We report a rare complication: perforation of the gall bladder following ileal perforation in a patient with typhoid fever.

## Case report

A 15-year-old boy presented in July 2006 with a 5-day history of abdominal pain and distension, constipation, bilious vomiting, and a 2-week history of fever. He denied any history of jaundice, alcoholism, or drug abuse. On examination, he was in shock with tachycardia, a low volume pulse, and hypotension. His abdomen was distended, tender, and rigid with absent bowel sounds. An abdominal X-ray revealed free gas under the right dome of the diaphragm and abdominal ultrasound showed dilated bowel loops and ascites. A provisional diagnosis of peritonitis due to typhoid perforation of the small intestine, with septic shock, was made. In this part of India, the incidence of typhoid fever is quite high among people in lower socio-economic groups and it often presents with surgical complications during the second or third week of illness during late summer and the monsoon months. It is so common during these months that when a patient, usually young, presents with perforation peritonitis preceded by 1 to 2 weeks of fever, the clinical diagnosis is typhoid unless proven otherwise. After resuscitation with fluids, suction and broad-spectrum antibiotics, an exploratory laparotomy was carried out. Multiple perforations of 1 x 1 cm were found on the antimesenteric border of the terminal ileum within 3 feet of the ileo-caecal junction. The rest of the small bowel wall was inflamed and a huge amount of free fluid with pus flakes was present in the peritoneal cavity. Most of the other viscera showed inflammatory exudates on the serosal surface. Peritoneal fluid was collected for culture/sensitivity and the diseased bowel segment was resected with an end-to-end ileo-ileal anastomosis. The Widal test was positive for *Salmonella typhi* and the peritoneal fluid culture showed *Escherichia coli* infection. On the third postoperative day, the patient developed progressive pain and distension of the abdomen, paralytic ileus, fever, and tachycardia and on the fourth postoperative day, bilious/enteric fluid drained from the wound. An exploratory laparotomy was planned to manage what was thought to be an anastomosis leak but could not be performed until the seventh postoperative day for purely logistic reasons. The anaesthetic team decided to manage the patient for 24 to 48 hours in the intensive care unit (ICU), intending to intervene if there was no improvement within 24 hours because his severe sepsis made him a poor surgical risk. At the same time, the patient's relatives lacked the financial means to pay the operating theatre and ICU charges. They were initially unwilling to consent to the second surgery because of the patient's poor condition and their economic constraints. They went home and managed to make arrangements to pay the fees over the next 2 days. On surgical exploration, frank bilious fluid was found in the peritoneal cavity and the gall bladder

### Key words

Gallbladder diseases; Ileal diseases;  
Intestinal perforation; Typhoid fever

*Hong Kong Med J* 2007;13:475-7

Department of General Surgery, Institute  
of Medical Sciences, Banaras Hindu  
University  
Varanasi, India  
V Saxena, MB, BS  
S Basu, MS  
CLN Sharma, MS, FAIS

Correspondence to: Dr S Basu  
E-mail: sombasu@hotmail.com

## 傷寒引發的回腸穿孔併發膽囊穿孔

膽囊穿孔有可能致命。自發穿孔並不常見，在沒有膽石的情況下出現更是非常罕有，但傷寒間或引起膽囊穿孔併發症。假如這些穿孔情況不及時處理，會造成極高死亡率。本病例報告中的病人在入院時診斷為膽囊穿孔，是傷寒引致回腸穿孔的併發症，須接受多次剖腹手術。

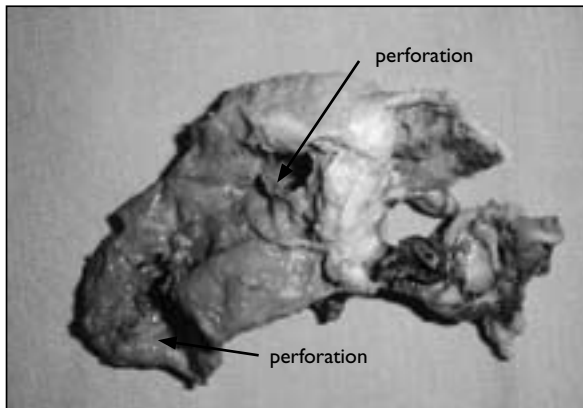


FIG. Excised gall bladder showing multiple perforations

showed multiple perforations. The anastomosis was sound but the bowel wall was congested. No new perforation was found in the bowel. Bile was taken for culture/sensitivity, a cholecystectomy performed and the abdomen closed after a thorough toilet. No stones were found in the peritoneal cavity, nor could any be palpated in the common bile duct. Macroscopically the resected gall bladder specimen showed red congested walls, patchy areas of gangrene and multiple perforations (Fig). A histological examination showed oedema, necrosis, and extensive infiltration with polymorphonuclear cells. A bile culture yielded *S typhi*. After 12 days of intensive care, the patient stabilised and was finally discharged. He expressed no complaints during follow-up visits, and remained well 4 months after surgery.

### Discussion

Typhoid fever is a common infection in the tropics and a common cause of intestinal perforation, resulting in high mortality and morbidity.<sup>3,4</sup> The enteric perforation(s) classically occur in the ileum in the second week of the illness. The associated sepsis and toxæmia make it a major challenge for the surgeon. Due to the high postoperative mortality, non-operative management used to be the treatment of choice, but better understanding of the pathogenesis of the disease and the availability of effective antibiotics now make early surgery the

best choice.<sup>4,5</sup> The operative mortality ranges from 12 to 25% in various series.<sup>6-8</sup> The factors leading to high mortality are younger age, inadequate medical treatment, late presentation, number of perforations and sepsis. On the other hand, early surgery has been found to be an independent variable in death reduction.<sup>5</sup> Perforation of the gall bladder was first reported by J Duncan of The Royal Infirmary, Edinburgh (quoted by Gonsalves in 1979<sup>9</sup>) about 135 years ago. It is a potentially fatal condition and demands prompt management. Perforation occurs in the presence of gallstone disease with the incidence varying from 5 to 12%.<sup>10</sup> Typhoid fever is also known to occasionally cause spontaneous perforation of the gall bladder in the absence of stone disease.<sup>13,11</sup> The operative mortality when repairing perforation of the gall bladder can be as high as 53.3%.<sup>12</sup> The combination of enteric perforation with a gall bladder perforation in typhoid fever increases the mortality many times over.

It was almost impossible to predict gall bladder perforation after the first surgery because the organ showed no evidence of gangrene, especially since perforation is uncommon in the absence of gallstones. Such perforations are also rare in typhoid fever so a combination of all these factors, namely typhoid fever, absence of gallstones and no gall bladder gangrene made it even more difficult to expect such an outcome. The presence of biliary effluent in the drain during the postoperative period usually makes one to think of another gut perforation, or a leak in a repaired perforation or anastomosis, all of which are common enteric complications of typhoid fever. Unless encountered before, it is very difficult to diagnose gall bladder perforation as a sequential complication of typhoid but in both situations, early surgery is the best option. Typhoid fever-induced perforation of the gall bladder following an enteric perforation in the same patient, managed by two consecutive laparotomies during the same admission has probably not been reported before. The reason for presenting this case is the need to highlight the possibility of a second perforation, of the gall bladder instead of the gut. Although it is not recommended that a cholecystectomy be performed when managing intestinal perforation in every typhoid case, we feel one should be diligent about the condition of the gall bladder and look particularly for any sign of patchy gangrene or impending perforation. In such circumstances, a cholecystectomy will prevent the second surgery and hence morbidity. Similarly, if the drain effluent is bilious during the postoperative period, one should keep such a possibility in mind. If a gall bladder perforation is detected late, an urgent cholecystectomy instead of non-operative management is indicated. Ultrasonography accurately detects 70% of cases with collapsed gall bladders and a perforation/defect in the gall bladder wall.<sup>13</sup> It can

show free fluid or a fluid collection close to the gall bladder fossa, a thickened gall bladder wall and a localised collection in the gall bladder wall. Thus it may be used as a first-line investigation whenever there is suspicion of gall bladder perforation, however, there is no specific sign indicating imminent perforation.

## References

1. Shukla VK, Khandelwal C, Kumar M, Vaidya MP. Enteric perforation of the gall bladder. *Postgrad Med J* 1983;59:125-6.
2. Memon AA. Perforated gall bladder: A case report. *J Surg Pak* 2001;6:37-8.
3. Ugwu BT, Yiltok SJ, Kidmas AT, Opaluwa AS. Typhoid intestinal perforation in north central Nigeria. *West Afr J Med* 2005;24:1-6.
4. Archampong EQ. Typhoid ileal perforation: why such mortality? *Br J Surg* 1976;63:317-20.
5. Saxe JM, Cropsey R. Is operative management effective in treatment of perforated typhoid? *Am J Surg* 2005;189:342-4.
6. Edino ST, Mohammed AZ, Uba AF, et al. Typhoid enteric perforation in north western Nigeria. *Niger J Med* 2004;13:345-9.
7. Honorio-Horna CE, Diaz-Plasentia J, Yan-Quiroz E, Burgos-Chavez O, Ramos-Dominguez CP. Morbidity and mortality risk factors in patients with ileal typhoid perforation [in Spanish]. *Rev Gastroenterol Peru* 2006;26:25-33.
8. Aziz M, Qadir A, Aziz M, Faizullah. Prognostic factors in typhoid perforation. *J Coll Physicians Surg Pak* 2005;15:704-7.
9. Gonsalves HJ. Spontaneous perforation of gallbladder due to acute non-calculus ulcerative cholecystitis. *J R Coll Surg Edinb* 1979;24:159-61.
10. Friley M. Perforation of the gallbladder. *Rev Surg* 1972;29:377-8.
11. Sarda DK, Chaudhury N, Hetwar S. Gall bladder perforation in typhoid fever. *J Indian Assoc Pediatr Surg* 2003;8:249-50.
12. Essenhigh DM. Perforation of the gall-bladder. *Br J Surg* 1968;55:175-8.
13. Sood BP, Kalra N, Gupta S, et al. Role of sonography in the diagnosis of gallbladder perforation. *J Clin Ultrasound* 2002;30:270-4.