

# Severe coagulopathy associated with white-lipped green pit viper bite

Janet YK Yang 楊懿君  
Henry Hui 許嘉恩  
Anselm CW Lee 李志偉

The authors report a case of *Trimeresurus albolabris* (white-lipped green pit viper) bite in a 6-year-old girl living in rural Yuen Long. Despite repeated use of *Agkistrodon halys* antivenin, the patient developed severe coagulopathy with defibrination syndrome on the fourth day of envenomation, which was also refractory to therapy with fresh frozen plasma. When treatment was switched to green pit viper antivenin, the coagulopathy resolved promptly. The case is illustrative of the potential lethality to children of snakebites in Hong Kong and suggests that the *A halys* antivenin may not be effective for the treatment of *T albolabris* bites.

## Introduction

Snakebites are a common injury in the rural areas of Hong Kong,<sup>1,2</sup> but it is rare for children to be victims.<sup>3</sup> The majority of cases are caused by *Trimeresurus albolabris*, commonly known as the white-lipped green pit viper. In adults, envenomation with *T albolabris* is frequently associated with local oedema and inflammation, while disturbance of coagulation is less common and rarely life-threatening.<sup>1</sup> Information about the clinical manifestations and complications of snakebites seen in children in Hong Kong is limited.<sup>3</sup> Our report of a case where a 6-year-old girl developed severe coagulopathy after being bitten by the green pit viper, despite treatment with the commonly recommended antivenin,<sup>4</sup> is therefore of special interest.

## Case report

A 6-year-old girl living in a rural part of Yuen Long was admitted in September 2004 after being bitten on her right foot by a snake. She was bitten at about 9 o'clock at night when she was walking with her father on a footpath outside her home. The father, who was a local resident, identified the snake as a green pit viper. On admission, the dorsum of her right foot was swollen; the swelling quickly progressed to the knee over the next 12 hours, then reached her mid-thigh within 24 hours. Blisters also developed around the bite wounds. The right lower limb blood vessels remained patent and neurological function remained normal. There were no signs of any circulatory disturbance.

The child was admitted to the paediatric intensive care unit for close observation. Initial treatment consisted of local toilet, wound dressings, tetanus toxoid, systemic antibiotics and analgesics. In view of the evidence of severe local envenomation, a vial (6000 units) of *Agkistrodon halys* antivenin (Shanghai Institute of Biological Products, Peoples' Republic of China) was given 3 hours after the injury.

The child's blood cell counts and coagulation parameters, including prothrombin time (PT), activated partial thromboplastin time (APTT), fibrinogen, and d-dimers were monitored daily. Mild hypofibrinogenaemia alone was first noticed on day 2, while the PT, APTT, d-dimers, and platelet counts remained normal on the first 3 days of admission (Fig). On day 4, the child's blood abruptly failed to coagulate with a PT >60.0 seconds, international normalised ratio (INR) >4.5, and APTT >150.0 seconds. Serum fibrinogen was undetectable and d-dimers >1 µg/mL. The platelet count was normal. In view of the severe coagulopathy, transfusions with fresh frozen plasma and cryoprecipitates were given daily from days 4 to 7. An additional vial of *A halys* antivenin was given on day 4 but the coagulopathy did not improve. On day 7, five vials of Green Pit Viper Antivenin (The Thai Red Cross Society, Thailand) with a neutralising activity equivalent to 17.5 mg of the specific venom were infused. The clotting profile returned to almost normal within 24 hours and became normal from day 9 onwards. There were no adverse reactions to the antivenin and the child was finally discharged on day 11.

## Discussion

Although Hong Kong is regarded as a developed and densely populated city, snakebite

### Key words

Antivenins; Blood coagulation disorders;  
Snake bites; *Trimeresurus*

*Hong Kong Med J* 2007;13:392-5

Department of Paediatrics and  
Adolescent Medicine, Tuen Mun  
Hospital, Tuen Mun, Hong Kong  
JYK Yang, MB, BS, MRCPCH  
H Hui, MB, BS, FHKAM (Paediatrics)  
ACW Lee\*, MB, BS, FHKAM (Paediatrics)

\* Currently at: Parkway Children's  
Haematology & Cancer Centre, East Shore  
Hospital, 321 Joo Chiat Place, Singapore  
427990

Correspondence to: Dr ACW Lee  
E-mail: aclee@graduate.hku.hk

is still a common injury among local residents, especially those living in the rural areas. At the Prince of Wales Hospital, which serves the eastern New Territories, about 50 cases were seen annually from 1984 to 1988,<sup>1</sup> whereas as many as 137 cases were seen at the Accident and Emergency Department in 1996.<sup>2</sup> At Tuen Mun Hospital, which serves the western New Territories, about 40 cases were seen annually from 2000 to 2005.<sup>5</sup> While it is a common injury in adults, it is rare for children to be victims of snakebite. The Prince of Wales Hospital reported only seven paediatric cases over a 10-year period.<sup>3</sup> Compared with other reported series, children bitten by snakes in Hong Kong appear to have milder clinical manifestations (Table<sup>3,6-10</sup>).

*Trimeresurus albolabris* is the commonest offender in Hong Kong and can be easily distinguished from other species by its green colour and envenomation syndromes.<sup>14</sup> The green pit viper venom has been found to possess a thrombin-like action in vitro but causes a defibrination syndrome in vivo.<sup>11</sup> This is manifested as a reduction of plasminogen and antiplasmin activities and elevated fibrin degradation products. Of the commonly available laboratory tests, prolongation of the thrombin time, hypofibrinogenaemia, and elevated d-dimers appear to be the most sensitive indicators of accelerated destruction of the fibrin monomers. Chan et al<sup>12</sup> studied 21 adults with snake envenomation and 18 (86%) patients had abnormal laboratory haemostasis parameters, such as elevated fibrin degradation products, hypofibrinogenaemia, and shortened euglobulin clot lysis time. Mild thrombocytopenia ( $85-133 \times 10^9/L$ ) and/or prolongation of PT (15-18.5 s), APTT (41.6-49.1 s) were also present in 10 patients, but none of these 21 cases had any clinically significant bleeding. Among the seven children with snakebites reported by the same institution,<sup>3</sup> four (57%) cases were found to have mildly abnormal coagulation (INR, 1.13-1.23; APTT, 40.2-42.3 s). Severe coagulopathy has been reported in Thailand where *T albolabris* is also commonly encountered.<sup>13</sup> Six of 24 patients presented with uncoagulable blood on admission, while another seven developed the same features between 9 and 47 hours after admission. The coagulopathy seen in the case we describe is not only remarkable for the severity of the laboratory abnormalities, but also distinguished by its delayed onset developing on the fourth day of envenomation. The mechanism governing this delayed manifestation of disordered coagulation is poorly understood. It is prudent to note that, of the three snakebite fatalities reported in Hong Kong,<sup>1</sup> two were caused by intracranial bleeding while coagulopathy was considered a contributory factor in the third patient who died of multi-organ failure and septicaemia.

Antivenins may play an important role in the management of venomous snakebites along with

### 被白唇竹葉青蛇咬傷所致的嚴重凝血

本報告描述一名六歲女童在元朗鄉郊被白唇竹葉青蛇咬傷的病例。雖然不斷注射抗腹蛇毒血清，但女童在被蛇咬傷中毒的第四天仍出現嚴重凝血以及去纖維蛋白徵，對採用新鮮冰凍血漿的療法並無反應。後轉用抗竹葉青蛇毒血清，凝血問題迅速消除。本報告正好是被蛇咬傷可能引致兒童喪命的一個本地例證，並顯示抗腹蛇毒血清未必能有效治療竹葉青蛇傷。

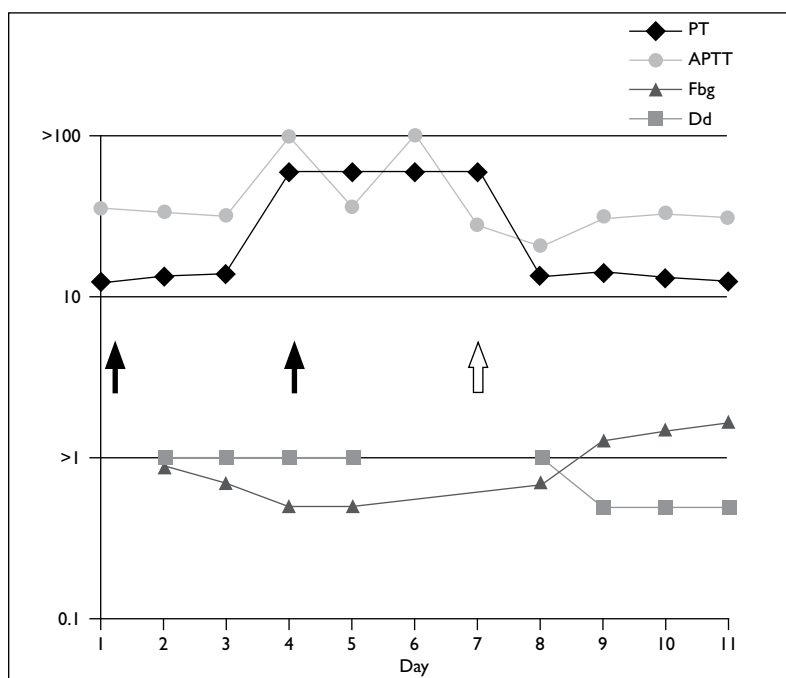


FIG. Serial measurements of the coagulation profile  
PT denotes prothrombin time (s), APTT activated partial thromboplastin time (s), Fbg fibrinogen (g/L), and Dd d-dimers (µg/mL) in relation to infusions of *Agkistrodon halys* antivenin (▲) and Green Pit Viper Antivenin (◊). Fresh frozen plasma was transfused daily from day 4 to day 7 (not marked)

general supportive care and wound management. Few antivenins have undergone randomised controlled trials, but their use in envenomated patients is supported by animal studies and extensive clinical experience.<sup>14</sup> Nevertheless, there are still doubts about their effectiveness and concerns regarding severe allergic reactions. Antivenins are usually indicated when there is evidence of systemic envenomation such as neurotoxicity, persistent hypotension, coagulopathy, rhabdomyolysis or renal failure, or when there is severe local tissue destruction. As the amount of antivenin required depends on the amount of venom to be neutralised, the dosage is the same for both children and adults, except in very small children in whom volume overload from repeated infusions may be a concern.

The infusion of *A halys* antivenin as an antidote during the initial management of our patient was a recommendation in local guidelines.<sup>4</sup> Even with

TABLE. Reported series of snakebites in children

City/country	No. of children	Types of snakebite	Significant complications	Antivenin therapy
Thailand <sup>6</sup>	72	Green pit viper in 29	Coagulopathy present; mild systemic bleeding in 21; no mortality	Green Pit Viper Antivenin in suboptimal doses used in 32 cases; objective responses absent
West Australia <sup>7</sup>	156	Brown snake ( <i>Pseudonaja</i> ) or Tiger snake ( <i>Notechis</i> ) in 21	Coagulopathy in 2; no systemic bleeding; rhabdomyolysis in 1; no mortality	Antivenins used in 18 cases; efficacy not assessed
Queensland, Australia <sup>8</sup>	218	Venomous snakes in 10 ( <i>Pseudonaja</i> in 5)	No mortality	Antivenins used in 14 cases; 1 developed anaphylaxis; favourable response mentioned
Mexico <sup>9</sup>	19	Rattlesnakes ( <i>Crotalus atrox</i> in 16; <i>Crotalus cerastes</i> in 3)	7 had coagulopathy; systemic bleeding present; 1 child died of disseminated intravascular coagulation	Antivenin used in 6 cases; efficacy not assessed
Arizona, US <sup>10</sup>	66	Rattlesnake ( <i>C atrox</i> ) in all cases	Coagulopathy present; no systemic bleeding; no mortality	Anti-Crotalidae Antivenin used in 50 cases; 19 developed anaphylaxis; efficacy not assessed
Hong Kong, PRC <sup>3</sup>	7	Green pit viper in 5	Coagulopathy in 4 cases; no systemic bleeding; no mortality	Green Pit Viper Antivenin used in 1; favourable response mentioned

\* Exact number not mentioned

repeated doses and the concomitant use of plasma products as advocated previously,<sup>15</sup> a therapeutic response was not evident. A search of the medical literature using the Medline database failed to identify any evidence that the *A halys* antivenin has therapeutic efficacy against *T albolabris*, although, according to the Chinese literature the antivenin has been useful against another *Trimeresurus* species (*Trimeresurus stejnegeri*). Indeed, information provided by the manufacturer describes the antivenin as indicated for bites with *A halys*, *T stejnegeri*, and *Trimeresurus mucrosquamatus*. Although *Agkistrodon* and *Trimeresurus* belong to the same genus *Crotalus* in the Viperidae family, it is not known whether antisera manufactured from the *A halys* venom are of a sufficiently broad spectrum to neutralise all kinds of

*Trimeresurus* venom. In contrast, the Green Pit Viper Antivenin produced by the Thai Red Cross Society is an antiserum specific for *T albolabris*. Given at the recommended dose, resolution of coagulopathy can be achieved rapidly in most treated patients within 5 hours.<sup>13</sup> Both antivenins are available in public hospitals in Hong Kong, but the therapeutic outcomes in our case suggest that the Thai product is a more effective treatment for *T albolabris* envenomation.

In summary, snakebites are uncommon in children in Hong Kong but the significant complications caused by envenomation by the white-lipped green pit viper (*T albolabris*) are still a clinical challenge. The use of antivenin therapy is controversial, but the Green Pit Viper Antivenin from Thailand is the treatment of choice when indicated.

## References

- Cockram CS, Chan JC, Chow KY. Bites by the white-lipped pit viper (*Trimeresurus albolabris*) and other species in Hong Kong. A survey of 4 years' experience at the Prince of Wales Hospital. *J Trop Med Hyg* 1990;93:79-86.
- Ng W, Cheung WL. Snake bites in Hong Kong: a prospective study on epidemiology and pre-hospital management. *Hong Kong J Emerg Med* 1997;4:68-73.
- Hon KL, Kwok LW, Leung TF. Snakebites in children in the densely populated city of Hong Kong: a 10-year survey. *Acta Paediatr* 2004;93:270-2.
- Ng WS, Ng MH. A&E clinical guidelines No. 9—management of snake bites. Hong Kong: Hospital Authority; 2004.
- Fung HT, Lam KK, Kam CW. Efficacy and safety of snake antivenom therapy: experience of a regional hospital. *Hong Kong J Emerg Med* 2006;13:70-8.
- Mitrakul C. Clinical features of viper bites in 72 Thai children. *Southeast Asian J Trop Med Public Health* 1982;13:628-36.
- Mead HJ, Jelinek GA. Suspected snakebite in children: a study of 156 patients over 10 years. *Med J Aust* 1996;164:467-70.
- Jamieson R, Pearn J. An epidemiological and clinical study of snake-bites in childhood. *Med J Aust* 1989;150:698-702.
- Cruz NS, Alvarez RG. Rattlesnake bite complications in 19 children. *Pediatr Emerg Care* 1994;10:30-3.
- LoVecchio F, DeBus DM. Snakebite envenomation in children: a 10-year retrospective review. *Wilderness Environ Med* 2001;12:184-9.
- Rojnuckarin P, Intragumtornchai T, Sattapiboon R, et al.

- The effects of green pit viper (*Trimeresurus albolabris* and *Trimeresurus macrops*) venom on the fibrinolytic system in human. *Toxicon* 1999;37:743-55.
12. Chan JC, Kwok MM, Cockram CS, Prematilleke MN, Tomlinson B, Critchley JA. Blood coagulation abnormalities associated with envenoming by *Trimeresurus albolabris* in Hong Kong. *Singapore Med J* 1993;34:145-7.
  13. Hutton RA, Looareesuwan S, Ho M, et al. Arboreal green pit vipers (genus *Trimeresurus*) of South-East Asia: bites by *T. albolabris* and *T. macrops* in Thailand and a review of the literature. *Trans R Soc Trop Med Hyg* 1990;84:866-74.
  14. Cheng AC, Currie BJ. Venomous snakebites worldwide with a focus on the Australia-Pacific region: current management and controversies. *J Intensive Care Med* 2004;19:259-69.
  15. Chan TY, Chan JC, Tomlison B, Critchley JA. Clinical features and hospital management of bites by the white-lipped green pit viper (*Trimeresurus albolabris*). *Southeast Asian J Trop Med Public Health* 1993;24:772-5.