

# Acyclovir-induced nephrotoxicity in a patient with acute retinal necrosis

David TL Liu 劉大立  
Vincent YW Lee 李佑榮  
Philip TH Lam 林子顥  
Dennis SC Lam 林順潮

A 50-year-old woman developed rapidly progressive acute renal failure on the first day after the administration of intravenous acyclovir for acute left retinal necrosis. Intravenous acyclovir was stopped and replaced with intravitreal injections of ganciclovir sodium (2 mg/0.05 mL) and foscarnet (1.2 mg/0.05 mL) 3 times per week for 4 weeks. Acyclovir-induced renal impairment can be reversed if recognised early and treated with careful, timely body fluid replacement. The necrotising retinitis responded well to intravitreal antiviral agents. No complications were seen at the 6 months' follow-up. Constant vigilance is essential for avoiding acute renal failure when treating ophthalmic conditions with intravenous acyclovir. Systematic monitoring of renal function, urine output, and characteristic symptoms like loin pain is warranted.

## Introduction

Acute retinal necrosis (ARN) is a clinical syndrome of vitritis, occlusive vasculitis and full-thickness, confluent necrotising retinitis. Viruses of the herpes family such as varicella-zoster virus (VZV), herpes simplex virus (HSV), and cytomegalovirus (CMV) are considered the aetiologic agents.<sup>1,2</sup> Blumenkranz et al<sup>1</sup> first documented application of intravenous acyclovir (1500 mg/M<sup>2</sup>/day) for an average of 10.9 days for the treatment of 13 eyes of 12 ARN patients, with regression of retinal lesions 3.9 days after therapy. Since then, intravenous acyclovir followed by oral acyclovir has been the standard treatment for herpetic ARN. This treatment regimen carries a potential risk of acyclovir-induced nephrotoxicity, though to date this has not been reported in the ophthalmology literature. We present a case of rapidly progressive acute renal failure in a previously healthy woman being treated with intravenous acyclovir for ARN. Risk factors for renal failure were explored and an alternative ARN ocular treatment was sought.

## Case report

In September 2005, a 50-year-old woman presented with a 1-week history of reduced vision in her left eye. The best-corrected left eye visual acuity was 20/400 and that of the right eye was 20/20. Physical examination revealed fine, pigmented, keratic precipitates, mild vitritis, and 360-degree confluent full-thickness creamy-yellow retinal necrosis spreading from the peripheral to posterior pole (Fig a). The right eye examination was unremarkable. The fundal appearance was consistent with ARN. A full blood count, erythrocyte sedimentation rate, renal and liver function tests were all normal. A serum virology assay was negative for the human immunodeficiency virus. Immune markers were absent. An urgent aqueous sample for polymerase chain reactions specifically for VZV, HSV I & II, and CMV was positive for VZV deoxyribonucleic acid. Intravenous acyclovir (1500 mg/M<sup>2</sup>/day in three divided doses) together with high-dose aspirin 320 mg daily was commenced. One day after commencement of the acyclovir infusion, she developed marked nausea and increasingly severe loin pain. Renal function tests showed a raised creatinine level of 1.83 mg/dL (reference range, 0.5-0.9 mg/dL) and the intravenous acyclovir was promptly withdrawn. Nevertheless, the serum creatinine kept rising, reaching 4.02 mg/dL with an estimated glomerular filtration rate of 27 mL/min 5 days after the treatment with intravenous acyclovir. Urine microscopy showed multiple needle-shaped birefringent crystals. The patient refused to have a renal biopsy. A vigorous but cautious body fluid challenge was started and her renal function stabilised on day 6, gradually returning to normal by day 12. This rapidly deteriorating acyclovir-induced acute renal failure precluded the resumption of intravenous acyclovir. Instead, we treated the affected eye with intravitreal injections of ganciclovir sodium (2 mg/0.05 mL) and foscarnet (1.2 mg/0.05 mL) 3 times per week for 4 weeks. Progression of the lesion was halted and gradual resolution of the confluent retinitis was evident with subsequent pigmentary scarring (Fig b). Oral prednisolone (30 mg per day) was introduced cautiously in view of the posterior segment inflammation. Three weeks after the resolution of the acyclovir-induced acute renal failure, oral acyclovir (800 mg 5 times per day), allowing better renal tolerance by achieving a lower plasma level, was carefully started together

### Key words

Acyclovir; Drug toxicity; Retinal necrosis syndrome, acute

*Hong Kong Med J* 2007;13:155-6

Department of Ophthalmology and  
Visual Sciences, The Chinese University  
of Hong Kong, Prince of Wales Hospital,  
Shatin, Hong Kong  
DTL Liu, MRCS  
VYW Lee, FRCS  
PTH Lam, FRCS  
DSC Lam, MD, FRCOphth

Correspondence to: Dr DTL Liu  
E-mail: david\_tliu@yahoo.com

## 一名急性視網膜壞死病人因阿昔洛韋導致腎中毒

一名50歲女病人因急性左眼視網膜壞死接受靜脈阿昔洛韋治療，但一日後出現急性腎功能衰竭。患者終止靜脈阿昔洛韋療法，代之以眼球玻璃體內注射更昔洛韋鈉（2 mg/0.05 mL）和膦甲酸（1.2 mg/0.05 mL），每星期三次，為期四星期。阿昔洛韋導致的腎臟受損若能及早發現和及時作體液更換治療，是可以逆轉的。病人壞死的視網膜對眼球玻璃體內抗病毒藥反應良好，而隨後六個月亦沒有出現併發症。以靜脈阿昔洛韋治療眼疾時，須小心避免急性腎臟衰竭，並要有系統地監察病人腎功能、排尿情況和是否出現腰痛等特殊徵狀。

with daily renal function monitoring. Two months later, all treatments were stopped and the left visual acuity improved to 20/50. The right eye remained normal. No retinal tears, nor rhegmatogenous or tractional retinal detachment were seen in the follow-up at 6 months.

### Discussion

It is well recognised that intravenous acyclovir causes elevated serum creatinine levels in a sizeable proportion of patients (12 to 48%).<sup>3</sup> Rapidly progressive acute renal failure has only been reported occasionally.<sup>3,4</sup> To the best of our knowledge, this is the first report of acyclovir nephrotoxicity induced by treatment of ARN. Usually, acyclovir is rapidly excreted in the urine in an unchanged and relatively insoluble form.<sup>3,4</sup> It has been shown that acute obstructive nephropathy is caused by crystal formation in the collecting ducts. Risk factors include rapid bolus high-dose acyclovir, depletion of circulating volume, and predisposition to renal impairment.<sup>3,4</sup> We used a standard dose and slow infusion regimen in this case. The unexpected drug-induced nausea, vomiting, and poor oral intake in our patient may have led to dehydration and favoured crystallisation in her kidney tubules. Having said that, unexpected acyclovir-induced renal failures have been reported despite precautions against volume contraction.<sup>4</sup> It has been shown that the development of crystalluria is reversible with early recognition and discontinuation of the drug in most patients.<sup>3,4</sup> Therefore, in ARN or other conditions being treated with high-dose acyclovir, vigilant monitoring consisting of daily renal function tests, urine output

### References

1. Blumenkranz MS, Culbertson WW, Clarkson JG, Dix R. Treatment of the acute retinal necrosis syndrome with intravenous acyclovir. *Ophthalmology* 1986;93:296-300.
2. Freeman WR, Thomas EL, Rao NA, et al. Demonstration of herpes group virus in acute retinal necrosis syndrome. *Am J Ophthalmol* 1986;102:701-9.
3. Perazella MA. Crystal-induced acute renal failure. *Am J Med* 1999;106:459-65.
4. Becker BN, Fall P, Hall C, et al. Rapidly progressive acute renal failure due to acyclovir: case report and review of the literature. *Am J Kidney Dis* 1993;22:611-5.
5. Perez-Blazquez E, Traspas R, Mendez Marin I, Montero M. Intravitreal ganciclovir treatment in progressive outer retinal necrosis. *Am J Ophthalmol* 1997;124:418-21.
6. Luu KK, Scott IU, Chaudhry NA, Verm A, Davis JL. Intravitreal antiviral injections as adjunctive therapy in the management of immunocompetent patients with necrotizing herpetic retinopathy. *Am J Ophthalmol* 2000;129:811-3.

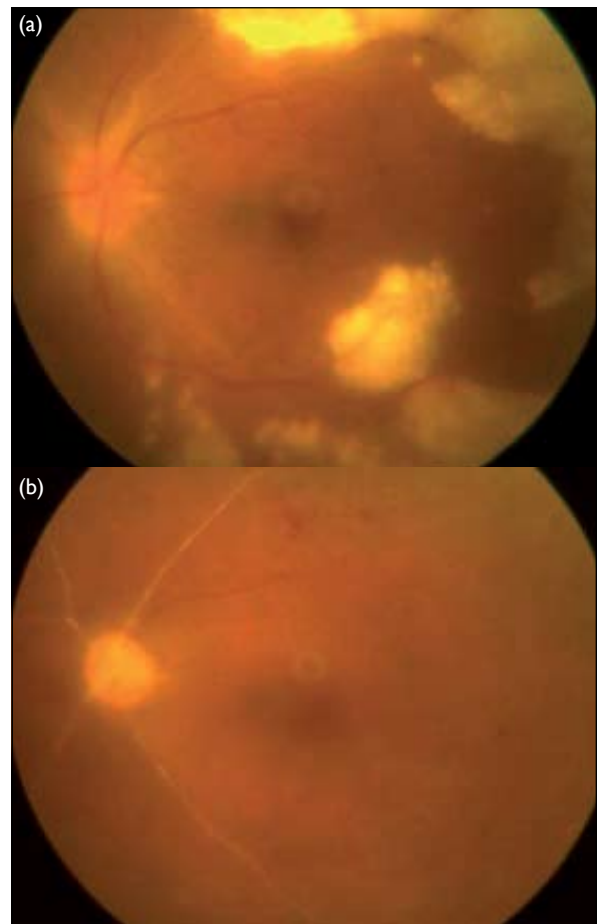


FIG. Colour photographs of the left fundus (a) Confluent full-thickness creamy-yellow retinal necrosis spreads from the peripheral retina into the posterior pole. (b) Five weeks after administration of the intravitreal ganciclovir and foscarnet, the retinitis has resolved almost completely, leaving behind a pale optic disc, multiple retinal scars and thrombotic arterioles

charting, and active questioning for characteristic symptoms like loin pain is warranted.

As with progressive outer retinal necrosis or acyclovir-resistant ARN, acyclovir-induced renal toxicity may be another clinical indication for intravitreal injections of antivirals such as ganciclovir and/or foscarnet.<sup>5,6</sup> However, when using this treatment alternative, the unaffected eye has not been protected by the antiviral agents, so both eyes must be closely monitored for 6 weeks after the initial presentation.