

R Meher  
S Agarwal  
I Singh

# Tuberculous retropharyngeal abscess in an HIV patient

## 一名愛滋病帶菌者的結核性咽後膿瘡

With the emergence of the human immunodeficiency virus (HIV), the incidence of deep neck space infections and associated life-threatening complications has been on the rise. We describe a case of tubercular retropharyngeal abscess in an HIV-positive patient who developed bilateral parapharyngeal space abscesses and was treated by incision and drainage.

愛滋病病毒的出現，令深喉間隙感染和相關的致命併發症的個案不斷上升。本文描述一名愛滋病帶菌者患上結核性咽後膿瘡，後來惡化為兩邊咽旁間隙膿瘡，須進行手術切除和引流。

### Introduction

Recent literature indicates that the incidence of deep neck space abscesses is on the decline because of the availability of better antibiotics used for upper respiratory infection, but cases of deep neck abscess that do not respond to conventional antibiotic therapy are on the rise. This may be due to reduced immunity, debility, human immunodeficiency virus (HIV) infection, and improper or inadequate treatment.

### Case report

In May 2003, a 24-year-old man presented to the department of otorhinolaryngology with complaints of dysphagia for solid food for about 1 week and difficulty with breathing for 2 days. He had experienced a low-grade irregular fever for about 3 months. The patient had no history of neck pain, ingestion of foreign bodies, earache, dental extraction, endoscopy or other invasive procedure, blood transfusion, haematemesis or melaena. The patient was of thin build and poor nutrition, with mild pallor but no cyanosis or clubbing. Blood investigations revealed mild anaemia with leukocytosis and an erythrocyte sedimentation rate of 52 mm in the first hour. A bulge was seen on the posterior pharyngeal wall. A chest X-ray showed opacities in the upper left and middle zones suggestive of old pulmonary tuberculosis. A neck X-ray showed an increase in the prevertebral shadow with straightening of the cervical spine. An emergency tracheostomy was performed under local anaesthesia; a cuffed tracheostomy tube was inserted followed by intra-oral drainage through a vertical incision in the posterior pharyngeal wall. Direct laryngoscopic examination after the drainage of the abscess was within normal limits. Pus from the retropharyngeal abscess did not show any acid-fast bacilli (AFB) or any growth on routine culture. After 2 days of drainage, the patient did not get better and developed right neck swelling that was fluctuant and tender. Pus was found on aspiration. Computed tomographic scanning of the neck showed, in addition to the retropharyngeal space abscess, bilateral parapharyngeal space abscesses with involvement of both submandibular spaces (Fig 1). The patient was given a general anaesthetic and the abscesses drained. Despite aggressive therapy using intravenous penicillin, gentamicin and metronidazole and daily dressings, the neck abscess did not improve. A workup for tuberculosis revealed a positive tuberculin (Mantoux) test at 72 hours using purified protein derivative (PPD). The Mantoux test was carried out by injecting 0.1 mL of PPD containing active tubercular antigen intradermally on the flexor surface of the forearm. A tuberculin reaction consists of erythema and induration; reactions exceeding

#### Key words:

HIV;  
Retropharyngeal abscess;  
Tuberculosis

#### 關鍵詞：

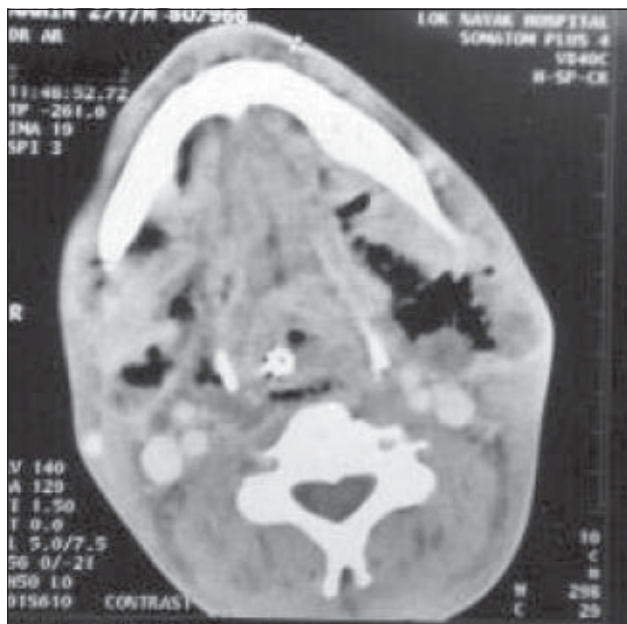
愛滋病病毒；  
咽後膿瘡；  
結核

*Hong Kong Med J* 2006;12:483-5

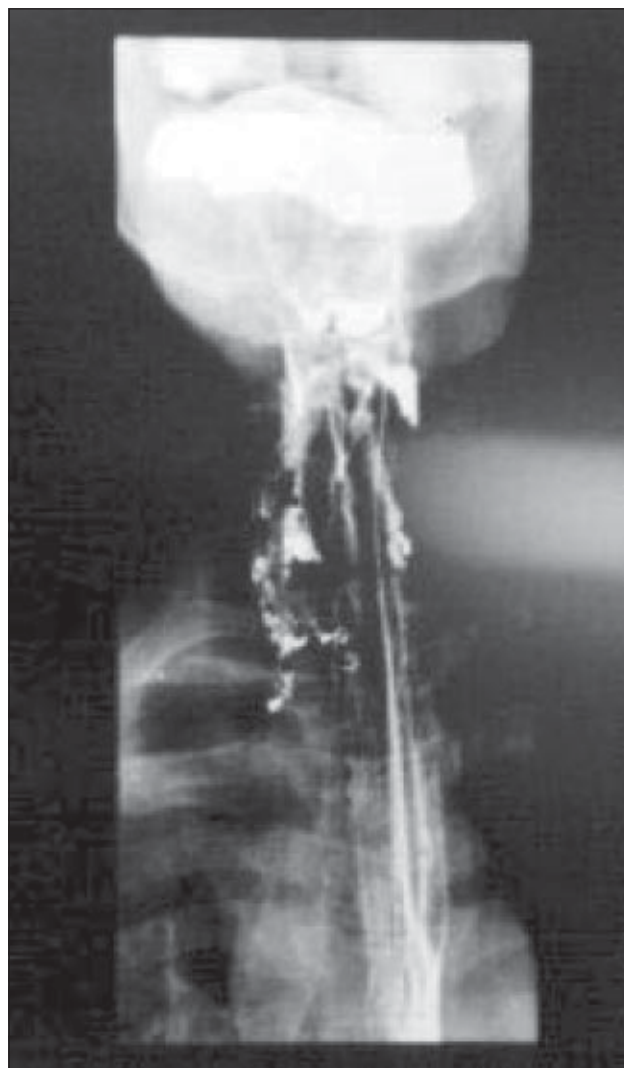Department of ENT and Head Neck  
Surgery, Lok Nayak Hospital, Maulana  
Azad Medical College, New Delhi, India

R Meher, MS, DNB (ENT)  
S Agarwal, MS, DNB (ENT)  
I Singh, MS (ENT)

Correspondence to: Dr R Meher  
(e-mail: meherravi@hotmail.com)



**Fig 1. Computed tomographic scan (axial cut) showing extensive retropharyngeal and parapharyngeal abscess**



**Fig 2. Barium swallow showing multiple tracts along the oesophagus**

10 mm are considered positive. A stain for AFB of the pus from the abscess was negative. A culture of tissue homogenate from the abscess cavity for pyogenic bacteria, mycobacteria, and fungal organisms yielded no growth. As all tests, apart from the Mantoux test, were negative for tuberculosis, an enzyme-linked immunosorbent assay (ELISA) for antimicrobial-IgM was used and was found to be reactive at 1:250 dilutions. Further investigation using the ELISA revealed the patient was HIV positive. This was confirmed by a western blot, which tests antibodies against the p24 antigen. The final diagnosis was made about 1 month after presentation. The patient later developed a leak from the tracheostomy site suggestive of a fistula connecting the oropharynx/hypopharynx to the trachea. After insertion of a Ryle's tube, pressure dressings were started. A barium swallow showed multiple tracts from the oropharynx going into the parapharyngeal space (Fig 2). The treatment was changed to anti-tubercular drugs and antiretroviral therapy using zidovudine, lamivudine, and zalcitabine. The patient improved considerably before discharge. He received isoniazid (300 mg), rifampicin (450 mg), pyrazinamide (1500 mg), and ethambutol (1200 mg) for 2 months, followed by isoniazid (300 mg) and rifampicin (450 mg) for 4 months with complete healing of the lesion.

## Discussion

A retropharyngeal abscess is a common pathology occurring secondary to acute infection of the throat or chronic infective conditions such as tuberculous cervical spines and tuberculosis of the cervical lymph nodes. The infection can spread to the parapharyngeal area or the mediastinal area, as the retropharyngeal space communicates with these. Delay in diagnosis and treatment

can lead to complications such as spontaneous rupture of the abscess leading to tracheobronchial aspiration, or stridor due to laryngeal oedema, or mediastinitis. Acute retropharyngeal abscesses are usually seen in children of less than 5 years of age. They are caused by spread of infection from the nasopharynx or the oropharynx, rarely from mastoid infection, as the pus tracks down along the underside of the petrous bone. This is rare in adults because the lymph nodes in the retropharyngeal space usually disappear after age 4 to 5 years, and is usually only seen after a penetrating injury or a foreign body piercing the posterior pharyngeal wall. A chronic lateral retropharyngeal abscess can occur when tubercular infection of the cervical lymph node spreads to the retropharyngeal nodes and forms a cold abscess. Intra-oral swelling is usually seen on the sides, not in the midline, as there is a central raphe. In the central type caused by tuberculosis of the cervical spine, the abscess is present between the vertebral body and the prevertebral fascia. It begins in the midline, then spreads to both sides. It can present at any age, usually causing

restricted movements of the neck and pain at the back of the neck. There is a swelling in the midline on oral examination. Predisposing factors are: debility, exanthemata, decreased immunity, and HIV infection. Unusual pathogens like *Staphylococcus aureus*,<sup>1</sup> *Streptococcus pneumoniae*,<sup>2</sup> *Pseudomonas aeruginosa*,<sup>3</sup> or *Mycobacterium tuberculosis* may be found in patients with HIV infection. Infection in such cases can progress rapidly to life-threatening complications like airway obstruction, jugular thrombophlebitis, descending suppurative mediastinitis, septic pulmonary foci, aspiration pneumonia, and extension to the adjoining neck space and carotid artery erosion.<sup>4</sup>

A tubercular retropharyngeal abscess in adults is usually secondary to tuberculous involvement of the cervical spine<sup>5</sup> and is a rare manifestation in HIV infection, even in the presence of extensive pulmonary involvement.<sup>6</sup> The probable route of tuberculosis spread to the retropharyngeal space is via the lymphatics to a persisting retropharyngeal lymph node. In rare cases, the abscess may be due to haematogenous spread from pulmonary tuberculosis and patients may present with dysphagia and stridor. In our patient, stridor and dysphagia were present but there was no evidence of spinal tuberculosis. Reduced immunity caused by HIV infection further aggravated the problem and led to rapid spread of infection to adjacent neck spaces and a delayed treatment response. Healed tubercular lesions shown on the chest X-ray suggested that the retropharyngeal abscess was due to haematogenous spread from pulmonary tuberculosis. Clinicians must be aware that an extensive deep neck space infection may not respond to conventional therapy in immunodeficient patients. The diagnosis is based on a high index of clinical suspicion, especially in an endemic area, a positive Mantoux test, radiological features, aspiration of swelling for bacteriological examination and culture, biopsy for

histopathological examination, ELISA, and polymerase chain reaction. Aggressive treatment with antitubercular and antiretroviral therapy along with early surgical intervention<sup>7</sup> is necessary to prevent further complications such as mediastinitis and great vessel involvement.

## Conclusion

The HIV epidemic has increased the population of immunocompromised patients susceptible to infections caused by different organisms including *M tuberculosis*. Although a tubercular retropharyngeal abscess in HIV-positive patients secondary to pulmonary tuberculosis infection is rare, clinicians should bear this possibility in mind when the neck abscess does not respond well to aggressive surgery and antimicrobial treatment.

## References

1. Lee KC, Tami TA, Echavez M, Wildes TO. Deep neck infections in patients at risk for acquired immunodeficiency syndrome. *Laryngoscope* 1990;100:915-9.
2. Benitez P, Guilemany JM, Alobid I, Berenguer J, Mullol J. Transoral approach to drain streptococcus pneumoniae spinal epidural abscess in an HIV-infected adult. *Acta Otolaryngol* 2004;124:863-6.
3. Sanderson RJ, Anstey ST. Parapharyngeal abscess from *Pseudomonas aeruginosa* infection in an HIV positive patient. *J Infect* 1995;31:174.
4. Singh I, Meher R, Agarwal S, Raj A. Carotid artery erosion in a 4-year child. *Int J Pediatr Otorhinolaryngol* 2003;67:995-8.
5. Ventura G, Cauda R, Paliotta VF, Colosimo C, Lucia MB. Pott's disease of the cervico-occipital junction in an AIDS patient. *Tuber Lung Dis* 1996;77:188-90.
6. Melchor Diaz MA, Domingo Carrasco C, Monge Jodra R, Marino Espuelas J, Ontanon Martin M. Tuberculous retropharyngeal abscess in an HIV patient. Report of a case [in Spanish]. *Acta Otorrinolaringol Esp* 1993;44:467-70.
7. Meher R, Jain A, Sabharwal A, Gupta B, Singh I, Agarwal AK. Deep neck abscess: a prospective study of 54 cases. *J Laryngol Otol* 2005; 119:299-302.