

N Tuncbilek
HM Karakas
OO Okten

Use of dynamic contrast-enhanced magnetic resonance imaging for differentiating between aggressive rectal tumours: two cases with small cell carcinoma and malignant melanoma

利用動態對比劑磁力共振掃描區分具侵略性的肛門腫瘤：兩宗微小細胞腫瘤和惡性黑素瘤的病例

Poorly differentiated small cell carcinomas and malignant melanomas are among the rarest of primary colorectal malignancies. Although very aggressive and lethal, small cell carcinomas and the amelanotic variety of malignant melanomas have similar radiological features to adenocarcinomas. We present two different cases with these unusual tumours, with special emphasis on their dynamic contrast-enhanced magnetic resonance imaging features. The dynamic contrast-enhanced magnetic resonance imaging revealed that these tumours have a faster and stronger enhancement pattern than most adenocarcinomas. The technique is thus potentially useful for the preoperative diagnosis of unusual aggressive tumours and for guiding the choice of treatment.

難以區分的微小細胞腫瘤和惡性黑素瘤，都屬極罕有的原發性結腸惡性瘤。雖然具侵略性和可以致命，微小細胞腫瘤和無黑色素的惡性黑素瘤都與腺瘤有相似的放射性特質。本文報告這兩種罕見腫瘤的病例，特別強調利用動態對比劑磁力共振掃描檢查時的特質。動態對比劑磁力共振掃描顯示，這類腫瘤比較大部分腺瘤顯影模式更快更強健。這項技術對在手術前診斷那些反常具侵略性的腫瘤和對選擇治療方法都有潛在價值。

Key words:

Carcinoma, small cell;
Magnetic resonance imaging;
Melanoma;
Rectal neoplasms

關鍵詞：

腫瘤，微小細胞的；
磁力共振掃描；
黑素瘤；
肛門腫瘤

Hong Kong Med J 2006;12:480-2

Department of Radiology, Trakya
University Medical Faculty, Edirne, Turkey
N Tuncbilek, MD
OO Okten, MD
Department of Radiology, Inonu University
Medical Faculty, Turgut Ozal Medical
Center, Malatya, Turkey
HM Karakas, MD

Correspondence to: Dr N Tuncbilek
(e-mail: drtuncbilek@hotmail.com)

Introduction

Primary small cell carcinomas (SCC) and malignant melanomas (MM) of the rectum are unusual aggressive tumours of the colon and rectum.¹⁻³ Although imaging is an important part of the preoperative diagnosis and staging in colorectal cancers, conventional techniques usually fail to provide an accurate differential diagnosis for these unusual tumours.

Dynamic contrast-enhanced magnetic resonance imaging (DCE-MRI) is a novel application for determining tumour angiogenesis in colorectal adenocarcinomas. It is non-invasive and rapid and can be used to select treatment preoperatively by estimating the aggressiveness of the malignancy, and for monitoring the chemoradiotherapeutic response postoperatively.^{4,5} It has not been used to study SCC and MM, but it has a potential use in the preoperative diagnosis of these rare colorectal cancers. We present two different cases of rectal SCC and MM with a special emphasis on their DCE-MRI features.

Case reports

Case 1

In May 2000, a 37-year-old woman was admitted with rectal bleeding, pain, and constipation. Rectosigmoidoscopy revealed an ulceroinfiltrative annular rectal mass 4.5 cm from the anal verge. Pelvic computed tomography (CT) revealed an

Table. Dynamic contrast-enhanced magnetic resonance imaging parameters in adenocarcinoma,* small cell carcinoma (SCC), and malignant melanoma (MM)

	Adenocarcinoma of all types	Adenocarcinoma with TEC [†] type A	SCC	MM
Time to peak enhancement (second) [mean (range)]	105 (60-180)	70 (60-120)	45	75
Steepest slope of TEC (mean [range])	2.53 (1.00-6.37)	3.77 (1.54-6.37)	5.02	4.98
Maximal relative enhancement (mean [range])	91 (48-180)	113 (61-180)	151	147

* Data for adenocarcinoma were from Reference 4

[†] TEC denotes time-enhancement curve

annular rectal tumour of 4 cm and multiple regional lymph nodes smaller than 2.5 cm. Further radiological work-up did not show any extracolonic involvement. A 1.0-T scanner was used as a part of the preoperative work-up. T1- and T2-weighted spin-echo MRI demonstrated an annular rectal tumour and enlarged lymph nodes. An abdominoperineal resection with regional lymph node dissection was performed and on histopathologic examination of the tissue a diagnosis of SCC was made. The micro vessel density (MVD) of the related specimen was 46 in the 200X high-power field (MVD was calculated by averaging the number of defined vessels in the six most vascularised tumour areas). The patient had four postoperative cycles of chemotherapy consisting of cisplatin and etoposide, and locoregional radiotherapy.

Case 2

In October 1999, a 70-year-old woman was admitted with a 6-month history of rectal bleeding, long-lasting pain, and constipation. Rectosigmoidoscopy revealed a greyish-brown tumour in the rectum. Pelvic CT revealed an annular rectal tumour of 4 cm and multiple regional lymph nodes smaller than 2 cm. A detailed work-up was performed. A 1.0-T scanner was used and MRI of the thorax revealed multiple pulmonary metastatic nodules. On conventional spin-echo sequences, the rectal lesion yielded a high signal intensity on T1-weighted and a low signal intensity on T2-weighted images. Swollen lymph nodes in the left pararectal area were demonstrated as hypointense lesions on both T1- and T2-weighted images. There was no evidence of invasion in the neighbouring pelvic structures. The patient underwent endoscopic biopsy and a diagnosis of MM was made. The patient died of systemic metastases approximately 4 months after the diagnosis.

Dynamic contrast-enhanced magnetic resonance imaging

Both lesions were scanned using an axial turbo fast low-angle shot sequence. After taking standard images, both patients received 0.1 mmol/kg gadopentetate dimeglumine intravenously through a peripheral line. The tumours were sampled every 30 seconds over a period of 3 minutes and 30 seconds. According to this protocol, every sampling block provided the signal intensity of its mid-point (ie 15th to 195th second). Precontrast images were subtracted from the relevant postcontrast images to reveal the differential enhancement.

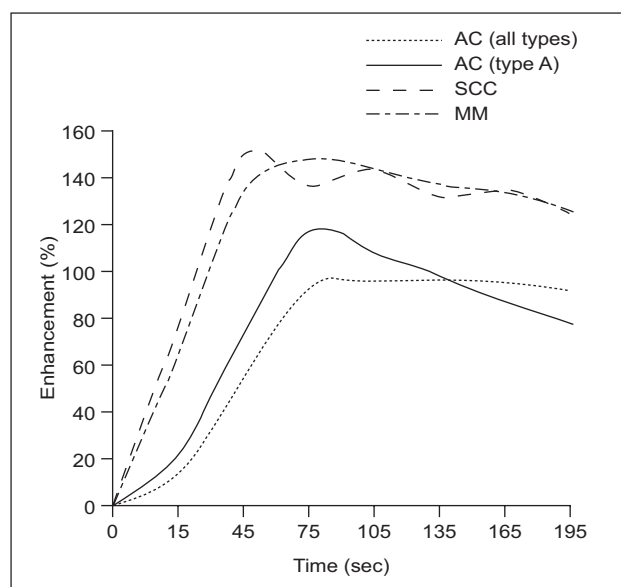


Fig. Line graphic showing mean time-enhancement curves of adenocarcinomas (AC) of all types, highly vascular adenocarcinomas, small cell carcinomas (SCC), and malignant melanomas (MM)

The latter two exhibit steeper curves and higher levels of enhancement

In the early imaging phase, both tumours showed strong enhancement because of the extensive blood flow. Subtracted dynamic images revealed a ring-like enhancement in case 1 and an intensive enhancement in case 2. Using nominal evaluation, time-enhancement curves (TECs) showed a contrast peak in the early phase (within 45 to 75 seconds) followed by a decrease in the late phase. The parametric enhancement features of the lesions are presented in the Table and Figure. In case 1, the TEC of the central portion of the largest lymph node was similar to the TEC of the primary tumour.

Discussion

Colorectal SCC is a rare tumour, most commonly found in the rectum. It has high metastatic potential; most patients have distant metastases at the time of diagnosis.⁶ Our patients had metastases in their perirectal lymph nodes but not in distant organs.

Malignant melanoma rarely involves the alimentary tract, and is usually located at the transitional segment of the anus. The colour (black appearance) is a very important feature in the differential diagnosis, but many MMs do not exhibit this feature. Therefore, the correct diagnosis can be obtained only after a histopathologic examination.^{3,6} Our patients presented with complaints of rectal bleeding and long-lasting pain, and presented slightly earlier than the mean time of 11.2 months reported in an earlier study.⁷

Magnetic resonance imaging seems to be better for staging colorectal cancers than CT,^{4,5} because MRI has a multiplanar imaging capability and is superior at showing local extension to neighbouring bones or muscle.⁸ Magnetic resonance imaging has considerable diagnostic value for rectal MM, because of its ability to differentiate between specific constituents. Because melanin pigments are paramagnetic, melanoma often yields high signal intensity on T1-weighted, and low signal intensity on T2-weighted images.^{3,9} Therefore, MM can be differentiated from other types of tumours that have low signal intensity on T1-weighted, and high signal intensity on T2-weighted images. However, the amelanotic variety of the melanoma has the same features as other rectal cancers, making it impossible to differentiate on MRI. This also holds true for SCCs.

Determination of tumour type by analysing dynamic enhancement patterns may be another use of MRI. Colorectal SCCs and MMs are highly infiltrative lesions, which lead to lower resectability and a higher risk of postoperative dissemination than colorectal adenocarcinomas.^{1,3} Dynamic enhancement features specific to these aggressive types may indicate the need for a more aggressive therapeutic option. Once established, these features may also be used for postoperative follow-up; the evolution of the TEC pattern from type C to type A or B indicates malignant transformation, whereas a change from type A to type B and C indicates that the treatment has been effective. The reverse situation provides evidence of a need for therapeutic change.

Muller-Schimpfle et al¹⁰ first used DCE-MRI to study colorectal cancers, using dynamic spin-echo sequence. Other studies^{4,5} correlated parametric measures of DCE-MRI (time to peak enhancement, steepest slope of the enhancement curve, and maximal relative enhancement in the first minute) with the tumour perfusion index, serum level of vascular endothelial growth factors, and mean vessel densities in colorectal adenocarcinoma. This method has also been used to differentiate between recurrent rectal cancer and scarring.¹⁰ The DCE-MRI was further used in stage T3 rectal cancers and provided nodal down staging in

high-permeability tumours.¹¹

According to Tuncbilek et al,⁴ most of the DCE-MRI parameters correlated with MVD in colorectal adenocarcinomas, and the TECs of tumour tissues were classified as type A (peak enhancement in the early phase, followed by a decrease in the late phase) in 43% of cases. This TEC type was correlated with high MVDs. The contrast enhancement in both SCC and MM was significantly faster and stronger than in most adenocarcinomas.⁴ Both SCC and MM also showed faster and stronger enhancement than the subgroup of adenocarcinomas with a similar TEC type (eg TEC type A) [Table, Fig].⁴ The MVD of the SCC in case 1 was 46. This density was much higher than the MVD of 28.2 seen in the average adenocarcinoma.⁴ Both SCC and MM are more vascular than adenocarcinomas; this plays an important role in the development of the aggressive TEC type. This vascularisation, along with multiple lymphatic drainage pathways, predisposes the tumour to early dissemination.

The existence of 'unusually' extreme DCE-MRI parameters in colorectal tumours should alert clinicians to the possibility of 'unusual' tumours. This possibility should dictate a more radical therapeutic approach to enable long-term survival.

References

1. Cebrian J, Larach SW, Ferrara A, et al. Small-cell carcinoma of the rectum: report of two cases. *Dis Colon Rectum* 1999;42:274-7.
2. Weinstock MA. Epidemiology and prognosis of anorectal melanoma. *Gastroenterology* 1993;104:174-8.
3. Roumen RM. Anorectal melanoma in the Netherlands: a report of 63 patients. *Eur J Surg Oncol* 1996;22:598-601.
4. Tuncbilek N, Karakas HM, Altaner S. Dynamic MRI in indirect estimation of micro vessel density, histologic grade, and prognosis in colorectal adenocarcinomas. *Abdom Imaging* 2004;29:166-72.
5. George ML, Dzik-Jurasz AS, Padhani AR, et al. Non-invasive methods of assessing angiogenesis and their value in predicting response to treatment in colorectal cancer. *Br J Surg* 2001;88:1628-36.
6. Sashiyama H, Takayama W, Miyazaki S, et al. The diagnostic value of endoscopic ultrasonography and magnetic resonance imaging for anorectal malignant melanoma: report of a case. *Surg Today* 2003;33:209-13.
7. De Lange EE, Fechner RE, Edge SB, Spaulding CA. Preoperative staging of rectal carcinoma with MR imaging: surgical and histopathologic correlation. *Radiology* 1990;176:623-8.
8. Reeders JW. Neoplastic and inflammatory diseases of the colon. *Eur Radiol* 2000;10(Suppl 2):135S-156S.
9. Ojima Y, Nakatsuka H, Haneji H, et al. Primary anorectal malignant melanoma: report of a case. *Surg Today* 1999;29:170-3.
10. Muller-Schimpfle M, Brix G, Loyer G, et al. Recurrent rectal cancer: diagnosis with dynamic MR imaging. *Radiology* 1993;189:881-9.
11. Devries AF, Griebel J, Kremser C, et al. Tumor microcirculation evaluated by dynamic magnetic resonance imaging predicts therapy outcome for primary rectal carcinoma. *Cancer Res* 2001;61:2513-6.