

PSC Yip 葉羨川  
 YL Lam 林英利  
 MK Chan 陳文光  
 JSJ Shu 許向捷  
 KC Lai 黎國忠  
 YC So 蘇鎰昌

# Computed tomography-guided percutaneous radiofrequency ablation of osteoid osteoma: local experience

## 香港利用經皮電腦斷層掃描射頻能量消融術切除骨樣骨瘤的經驗

Osteoid osteoma is a slow-growing tumour with limited growth potential. In the past, treatment comprised open surgery with en-bloc resection or curettage of the tumour. In recent years, various minimally invasive percutaneous treatments have gained popularity. We report on six patients who underwent computed tomography-guided percutaneous radiofrequency ablations of osteoid osteomas between January 2000 and December 2003 in a regional hospital in Hong Kong. Technical success was achieved in all procedures, with a mean follow-up of 40 months (range, 18-65 months). Five of the six patients achieved complete pain relief after the procedure and remained pain-free on subsequent follow-up. One patient with persistent symptoms after the first ablation was successfully treated with a second ablation. The mean in-hospital stay was 2.4 days. Progress in radiological healing was observed in all patients. There was one complication of skin burn over the needle entry site. Our experience shows that percutaneous computed tomography-guided radiofrequency ablation is a minimally invasive and cost-effective treatment for osteoid osteoma.

骨樣骨瘤是一種發展緩慢和成長機率有限的腫瘤，過往只能開刀整個切除或刮除治療。近年，刺穿皮膚進行微創手術越來越普及。本文報告2000年1月至2003年12月期間，香港一所地區醫院進行了六宗利用刺穿皮膚技術，以電腦斷層掃描引導射頻能量切除骨樣骨瘤的病例。技術上所有程序都很成功，病人的跟進期平均為40個月（介乎18至65個月）。六名病人中，有五人在治療後痛楚完全消失，並在跟進期內維持無痛楚。一名病人在首次治療後病徵持續出現，但第二次治療後已痊愈。病人的住院期平均為2.4日。是次研究亦觀察病人放射痊癒的進展，其中一名病人的皮膚刺針位置有燒傷併發症。是次經驗顯示，以經皮電腦斷層掃描射頻能量消融術切除骨樣骨瘤，侵害性低且具成本效益。

**Key words:**

Bone neoplasms;  
 Catheter ablation;  
 Osteoma, osteoid

**關鍵詞：**

骨瘤；  
 導管消融術；  
 骨瘤，骨樣的

*Hong Kong Med J* 2006;12:305-9

Queen Elizabeth Hospital, 30 Gascoigne Road, Hong Kong;

Department of Orthopaedics and Traumatology

PSC Yip, MB, BS

YL Lam, FRCS (Edin), FHKAM (Orthopaedic Surgery)

YC So, FRCS (Edin), FHKAM (Orthopaedic Surgery)

Department of Radiology and Imaging

MK Chan, FRCR, FHKAM (Radiology)

JSJ Shu, FRCR, FHKAM (Radiology)

KC Lai, FRCR, FHKAM (Radiology)

Correspondence to: Dr PSC Yip  
 (e-mail: paulyipsc@gmail.com)

### Introduction

Osteoid osteoma, first described in 1935, accounts for 10% to 12% of primary benign bone tumours and 5% of all primary bone tumours.<sup>1,2</sup> It generally affects children and adolescents and most commonly occurs in the proximal femur and tibia. Pain is the most common presenting symptom and is described as severe, sharp, and worse at night. It is typically relieved by aspirin or other non-steroidal anti-inflammatory drugs (NSAIDs). Other possible presentations include growth disturbance, painful scoliosis, and (if located within a joint) joint swelling, synovitis, restricted movement, and contracture.<sup>3,4</sup>

The typical radiographic appearances of osteoid osteoma comprise a lytic nidus surrounded by dense sclerotic bone. Radionuclide bone scanning is sensitive but of low specificity, although a typical double-density nidus sign may be seen.<sup>5</sup> Computed tomography (CT) is more effective than magnetic resonance imaging for making the diagnosis and localising the tumour and is the imaging modality of choice.<sup>6</sup>

Pathologically, an osteoid osteoma usually comprises a round or oval lesion

**Table 1. Patient details, presentations, and investigations performed**

Patient No.	Sex/age (years)	Symptoms and signs	Duration of symptoms	Investigations*	Location of lesion	Longest dimension of nidus on CT scan
1	F/18	Left hip pain, limping gait	1 year	X-ray, CT scan, bone scan, MRI	Left femoral neck	10 mm
2	F/19	Right hip pain, nocturnal pain, limping gait, right lower limb wasting	1 year	X-ray, CT scan, MRI	Right femoral neck	7 mm
3	F/23	Mild left leg pain	3 months	X-ray, CT scan	Left proximal tibia	5 mm
4	F/11	Left leg pain	7 months	X-ray, CT scan, MRI	Left tibial shaft	4 mm
5	M/9	Right knee pain, limping gait, right lower limb wasting	2 years	X-ray, CT scan, MRI, bone scan	Right femur meta-diaphyseal region	12 mm
6	M/14	Left thigh pain, limping gait	2 years	X-ray, CT scan, bone scan, MRI	Left mid-shaft femur	8 mm

\* CT denotes computed tomography, and MRI magnetic resonance imaging

(called a nidus) surrounded by a variable amount of reactive bone tissue. It usually arises from the bony cortex or periosteum. Osteoid osteoma is a slow-growing tumour with limited growth potential. It usually runs a self-limiting course with pain subsiding in 5 to 6 years as the lesion matures.<sup>7</sup> Traditional medical treatment includes aspirin or other NSAIDs for pain relief, however, long-term medication is not acceptable to most parents and children due to inadequate pain relief and the gastro-intestinal complications associated with NSAIDs. In some cases more definitive treatment is preferable. In the past, such treatment comprised open surgery with en-bloc resection or curettage of the tumour and high success rates were reported.<sup>8,9</sup>

Recently, various minimally invasive percutaneous treatments, including CT-guided radiofrequency ablation, have gained popularity. Radiofrequency ablation is now an accepted, safe, and cost-effective treatment for osteoid osteoma and is routinely used in some tertiary referral centres. There appears to be no local data regarding this treatment modality. The aim of our study was to review our early experience with this technique.

## Patients and methods

Between January 2000 and December 2003, six patients (4 female and 2 male) with a clinical diagnosis of osteoid osteoma were referred to and treated by our radiologist using percutaneous CT-guided radiofrequency ablation. The mean age at presentation was 15.6 years (range, 9-23 years). Lesion and symptom characteristics are summarised in Table 1. The diagnoses were based on clinical symptoms and radiographic and CT features. All patients were offered conservative treatment with NSAIDs, surgical excision of the nidus, or percutaneous radiofrequency ablation. Half of the patients (n=3) tried NSAIDs initially with little or no improvement and all six patients subsequently consented to CT-guided radiofrequency ablation. Patient characteristics are summarised in Table 1.

## Procedure

The procedure was performed under general anaesthesia, using CT guidance, by two interventional radiologists

working together. Five patients underwent core bone biopsy immediately before ablation. One patient had a CT-guided core bone biopsy at a separate preceding examination.

The approach to the lesion was dependent on the location, which was precisely localised using thin cut CT. The shortest distance to the bone was usually selected. A coaxial Bonopty bone biopsy system (Radi Medical Systems, Uppsala, Sweden) was used in most patients. A small (5 mm) incision was made and the penetration cannula with stylet introduced as far as the bone surface. The stylet was then exchanged for a drill and drilling was done down to the edge of the nidus. The penetration cannula was advanced over the drill so that it was anchored in the bone cortex. A biopsy cannula (16G in size) was introduced in place of the drill and a core bone biopsy taken for histology. A radiofrequency ablation cannula with stylet was then inserted via the penetration cannula until the tip was placed in the centre of the nidus. The stylet was exchanged for the radiofrequency ablation probe with 5 mm effective tip (SMK-TC15; Radionics, Burlington, US). The tip temperature was slowly increased to 90°C and ablation performed for a mean of 8.4 (range, 6-10) minutes for each procedure.

For elongated lesions or those larger than 10 mm, a second needle was passed to a different position in the nidus (through the same skin incision) to ensure no portion of the nidus was more than 5 mm from the electrode tip. A small dressing was applied to the skin puncture site after the procedure. The whole procedure took 45 minutes to 1 hour. All patients were allowed full weight bearing after the procedure and advised to avoid strenuous exercise for 6 weeks.

Technical success was defined as successful localisation of the lytic nidus and placement of an electrode under CT guidance with ablation performed for the desired period. Clinical success was defined as complete symptomatic relief within 2 weeks of intervention, no need for analgesia, and no recurrence for at least 18 months on subsequent follow-up.

**Table 2. Treatment information and results of the six patients**

Patient No.	Date of treatment	Bone biopsy result	Response to treatment	Hospital stay (days)	Follow-up treatment	Follow-up period (months)
1	13 Jan 2000	Osteoid osteoma	Decreased pain but still had limping gait	2	Second ablation on 21 Jun 2000 with resolution of pain and limping within 1 day (stay, 2 days)	65
2	24 Jan 2000	No diagnostic feature	Pain and limping completely resolved after 3 days	2	Nil	65
3	27 Jan 2001	No significant pathology	Original pain resolved within 1 day but complicated by burn over skin puncture site	5	Ulcer completely healed after wound dressing	52
4	4 Sept 2003	No diagnostic feature	Pain resolved within 1 day	1	Nil	21
5	4 Sept 2003 (bone biopsy), 13 Nov 2003	Osteoid osteoma	Pain and limping completely resolved after 1 week	3	Nil	19
6	30 Dec 2003	Osteoid osteoma	Pain and limping resolved within 1 day	2	Nil	18

All patients were followed up regularly in a specialist out-patient clinic and were also contacted by phone for discussion of their progress in June 2005.

## Results

Technical success was achieved in all procedures. The mean follow-up period was 40 months (range, 18-65 months). Five of the six patients achieved complete pain relief and a return to normal gait after a mean of 2 days (range, 1-7 days). There was no recurrence on subsequent follow-up (83% primary clinical success rate). One patient had initial failure with improved but residual pain after the first ablation. She was successfully treated by a second ablation 4 months later with complete pain relief within 1 day. She remained pain-free on follow-up (100% secondary clinical success rate). One patient sustained a skin burn over the ablation needle entry site presenting with skin erythema immediately after the procedure. That was followed by a small skin ulcer. She required a course of antibiotics and wound dressing in the out-patient clinic. The ulcer healed with no skin graft needed. There were no fractures, haematoma formations, or neurovascular injuries during or after each procedure. The mean length of in-hospital stay for each admission was 2.4 days (range, 1-5 days). Radiological healing was observed in all six cases, with either complete disappearance (n=4) or blurring of the nidus (n=2). With regard to core bone biopsy results, 50% of specimens provided histological confirmation of osteoid osteoma. There were no diagnostic features in the remaining specimens. A summary of the treatment information and results of the six patients is shown in Table 2 (Figs 1-3).

## Discussion

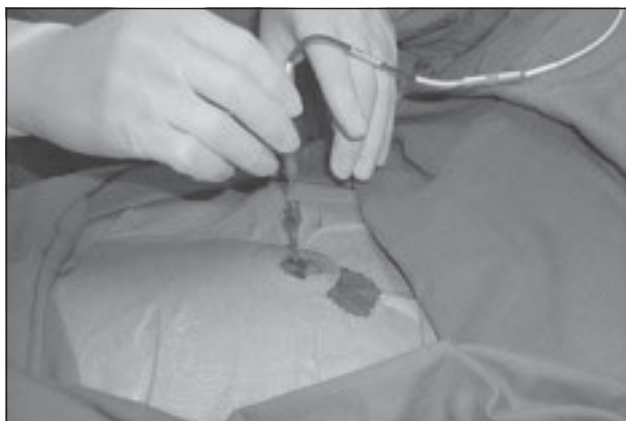The standard treatment option for patients with painful osteoid osteomas is conservative treatment with NSAIDs or surgery (en-bloc resection of the nidus and surrounding reactive bone or curettage). During open surgery, intra-operative localisation of the nidus may be difficult and

result in wider resection margins than expected. If a weight-bearing bone is involved, internal fixation and/or bone grafting may be necessary to prevent fracture and protected weight bearing for a prolonged period may be required. Surgery in anatomically difficult sites such as the acetabulum, femoral head, or neck can lead to significant morbidity. Various techniques such as intra-operative radioisotope scans or CT localisation of the nidus have been developed in an attempt to better localise the tumour.<sup>10</sup> More recently, percutaneous techniques have been used in an attempt to limit iatrogenic damage to normal tissue. These include percutaneous resection of tumours and several different percutaneous ablation techniques.

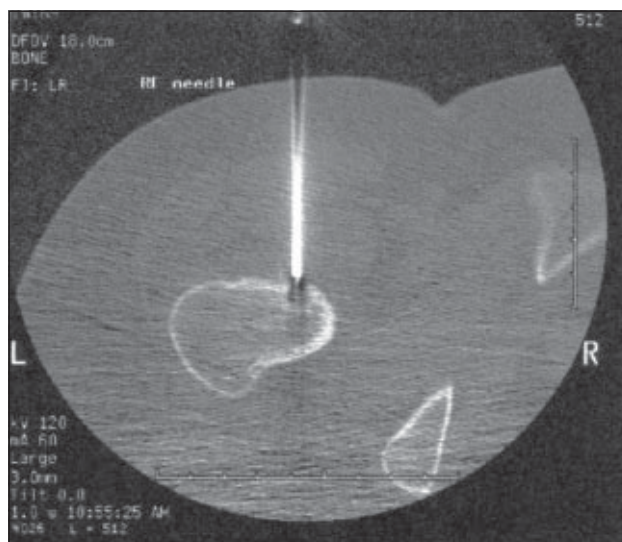
Percutaneous resection using large calibre needles and drills has been advocated in the past due to its simplicity and high success rate.<sup>11</sup> With the mean tumour diameter being around 7 mm, and tumours larger than 10 mm being not uncommon, large-calibre drills and multiple passes may be necessary, thus obviating the advantage of such a minimally invasive approach. Patients must also be non weight-bearing for a few weeks. Fractures, osteomyelitis, skin burns, and muscular haematomas have also been reported using this technique.<sup>7,11</sup>

Percutaneous ablation techniques include alcohol injection, interstitial laser photocoagulation, and radiofrequency ablation. High initial success rates have been reported for the first two techniques.<sup>12-15</sup> The main disadvantage of alcohol injection is its non-selective action on tissue, thus extravasation may affect the surrounding normal tissue. Interstitial laser coagulation using small optical fibres is very expensive and biopsy cannot be performed simultaneously. The long-term results of alcohol injection and laser photocoagulation are also limited.

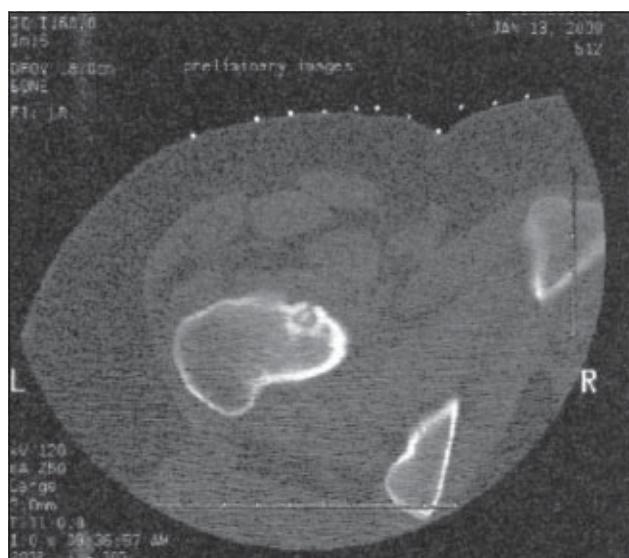
The authors' hospital started using radiofrequency ablation to treat osteoid osteoma in 2000. Case numbers are small due to the fact that osteoid osteoma is rare and only locally referred cases are treated. The treated patients in



**Fig 1. Treatment of an osteoid osteoma of the femur**  
Placement of the radiofrequency probe through the penetration cannula



**Fig 3. Computed tomographic image showing passage of the radiofrequency probe to the nidus through an anterior approach**



**Fig 2. Computed tomographic image of an osteoid osteoma of the femoral neck showing a typical nidus with central calcification**

our study were also the only patients with a diagnosis of osteoid osteoma who were followed up in our specialist clinic throughout the study period.

We performed radiofrequency ablation under general anaesthesia in all patients, consistent with other authors. Early experience showed that local anaesthesia was inadequate for pain control, despite adequate anaesthetic infiltration of soft tissue and the overlying periosteum.<sup>16</sup> Entering the nidus also elicited extreme pain and resulted in movement of the patient and loss of the position of the electrode.<sup>16</sup> In addition, the nidus is very sensitive, thus its disturbance can cause elevation of cardiac and respiratory rates, even under general anaesthesia.<sup>17</sup>

Primary clinical failure with residual pain occurred in

one patient. She was the first case in our study and the electrode was placed in only one position in the nidus. The failure was probably due to incomplete destruction of the nidus. For an effective electrode tip of 5 mm, there is a 1 cm spherical zone of thermal necrosis (irrespective of the duration of ablation<sup>18,19</sup>). As the size of the lesion in this case was 10 mm, any slight off-centring of the probe would have resulted in incomplete ablation of the nidus. Following this experience, we placed the electrode in three different positions in the nidus to ensure complete ablation of the lesion in a subsequent patient (patient 5) whose lesion measured more than 10 mm. This patient was successfully treated with no recurrence. A recent retrospective review of 72 successfully treated and 23 unsuccessfully treated patients with osteoid osteoma by percutaneous radiofrequency ablation concluded that multiple needle positions reduce the risk of treatment failure, especially in large ( $\geq 10$  mm) lesions.<sup>20</sup>

We followed up all our patients with radiographs and progress in radiological healing was observed in all cases. Although disappearance of the lesion is reassuring to the patients and the parents, the main goal of our treatment is still symptomatic relief since there is no evidence of a direct relationship between radiological healing and symptomatic relief.

No lesions were located in the spine (including the posterior arch, despite it being a common location for this tumour) in our series. Although there are reports of successful treatment in the spine without neurological complications,<sup>21-23</sup> radiofrequency ablation at these sites must be performed cautiously because of the difficulty with positioning the probe at least 1 cm away from the nerve roots or spinal cord. A similar problem may be encountered in rare lesions of the hands and feet.



## Conclusion

Early experience in our hospital and evidence from previous studies show that percutaneous CT-guided radiofrequency ablation is a minimally invasive and effective treatment for patients with osteoid osteomas. We advocate that it should be the preferred definitive treatment for osteoid osteoma of the appendicular skeleton.

## References

- Kransdorf MJ, Stull MA, Gilkey FW, Moser RP Jr. Osteoid osteoma. *Radiographics* 1991;11:671-96.
- Springfield DS. Osteoid osteoma. In: Morrissy RT, Weinstein SL, editors. *Lovell and Winter's paediatric orthopaedics*. 4th ed. Philadelphia: Lippincott-Raven Publishers; 1996:422-5.
- Dahlin DC. *Bone tumours: general aspects and data on 6221 cases*. Philadelphia: Lippincott-Raven Publishers; 1996:463.
- Radcliffe SN, Walsh HJ, Carty H. Osteoid osteoma: the difficult diagnosis. *Eur J Radiol* 1998;28:67-79.
- Helms CA. Osteoid osteoma. The double density sign. *Clin Orthop Relat Res* 1987;222:167-73.
- Hosalkar HS, Garg S, Moroz L, Pollack A, Dormans JP. The diagnostic accuracy of MRI versus CT imaging for osteoid osteoma in children. *Clin Orthop Relat Res* 2005;433:171-7. Erratum in: *Clin Orthop Relat Res* 2005;436:286.
- Parlier-Cuau C, Champsaur P, Nizard R, Hamze B, Laredo JD. Percutaneous removal of osteoid osteoma. *Radiol Clin North Am* 1998;36:559-66.
- Krishnan K. *Dahlin's bone tumours—general aspect and data on 11,087 cases*. 5th ed. Philadelphia: Lippincott-Raven Publishers; 1996.
- Sluga M, Windhager R, Pfeiffer M, Dominkus M, Kotz R. Peripheral osteoid osteoma. Is there still a place for traditional surgery? *J Bone Joint Surg Br* 2002;84:249-51.
- Lee DH, Malawer MM. Staging and treatment of primary and persistent (recurrent) osteoid osteoma. Evaluation of intraoperative nuclear scanning, tetracycline fluorescence, and tomography. *Clin Orthop Relat Res* 1992;281:229-38.
- Sans N, Galy-Fourcade D, Assoun J, et al. Osteoid osteoma: CT-guided percutaneous resection and follow-up in 38 patients. *Radiology* 1999;212:687-92.
- Gangi A, Dietemann JL, Clavert JM, et al. Treatment of osteoid osteoma using laser photocoagulation. Apropos of 28 cases [in French]. *Rev Chir Orthop Reparatrice Appar Mot* 1998;84:676-84.
- Adam G, Keulers P, Vorwerk D, Heller KD, Fuzesi L, Guenther RW. The percutaneous CT-guided treatment of osteoid osteoma: a combined procedure with a biopsy drill and subsequent ethanol injection [in German]. *Rofo* 1995;162:232-5.
- Sanhaji L, Gharbaoui IS, Hassani RE, Chakir N, Jiddane M, Boukhrissi N. A new treatment of osteoid osteoma: percutaneous sclerosis with ethanol under scanner guidance [in French]. *J Radiol* 1996;77:37-40.
- Witt JD, Hall-Craggs MA, Ripley P, Cobb JP, Bown SG. Interstitial laser photocoagulation for the treatment of osteoid osteoma. *J Bone Joint Surg Br* 2000;82:1125-8.
- Pinto CH, Taminiau AH, Vanderschueren GM, Hogendoorn PC, Bloem JL, Obermann WR. Technical considerations in CT-guided radiofrequency thermal ablation of osteoid osteoma: tricks of the trade. *AJR Am J Roentgenol* 2002;179:1633-42.
- Rosenthal DI, Marota JJ, Hornicek FJ. Osteoid osteoma: elevation of cardiac and respiratory rates at biopsy needle entry into tumor in 10 patients. *Radiology* 2003;226:125-8.
- Rosenthal DI, Alexander A, Rossenberg AE, Springfield D. Ablation of osteoid osteomas with a percutaneously placed electrode: a new procedure. *Radiology* 1992;183:29-33.
- Tillotson CL, Rosenberg AE, Rosenthal DI. Controlled thermal injury of bone. Report of a percutaneous technique using radiofrequency electrode and generator. *Invest Radiol* 1989;24:888-92.
- Vanderschueren GM, Taminiau AH, Obermann WR, van den Berg-Huysmans AA, Bloem JL. Osteoid osteoma: factors for increased risk of unsuccessful thermal coagulation. *Radiology* 2004;233:757-62.
- Depuy DE, Hong R, Oliver B, Goldberg SN. Radiofrequency ablation of spinal tumors: temperature distribution in the spinal canal. *AJR Am J Roentgenol* 2000;175:1263-6.
- Samaha EI, Ghanem IB, Moussa RF, Kharrat KE, Okais NM, Dagher FM. Percutaneous radiofrequency coagulation of osteoid osteoma of the "Neural Spinal Ring". *Eur Spine J* 2005;14:702-5.
- Cove JA, Taminiau AH, Obermann WR, Vanderschueren GM. Osteoid osteoma of the spine treated with percutaneous computed tomography-guided thermocoagulation. *Spine* 2000;25:1283-6.